

FOLIA MEDICA CRACOVIENSIA

Vol. LX, 3, 2020: 65–74

PL ISSN 0015-5616

DOI: 10.24425/fmc.2020.135796

## The height and type of the main septum in the sphenoid sinuses — evaluation before the fess

JOANNA JAWOREK-TROĆ<sup>1,2</sup>, MICHAŁ ZARZECKI<sup>1</sup>, IZABELA ZAMOJSKA<sup>1</sup>, ROBERT CHRZAN<sup>2</sup>,  
ANNA CURLEJ-WĄDRZYK<sup>3</sup>, JOE IWANAGA<sup>4</sup>, JERZY WALOCHA<sup>1</sup>, ANDRZEJ URBANIK<sup>2</sup>

<sup>1</sup>Department of Anatomy, Jagiellonian University Medical College, Kraków, Poland

<sup>2</sup>Department of Radiology, Jagiellonian University Medical College, Kraków, Poland

<sup>3</sup>Department of Integrated Dentistry, Institute of Dentistry Jagiellonian University Medical College, Kraków, Poland

<sup>4</sup>Department of Neurosurgery, School of Medicine, Tulane University, New Orleans, USA

**Corresponding author:** Prof. Jerzy A. Walocha, M.D., Ph.D.

Department of Anatomy, Jagiellonian University Medical College

ul. Kopernika 12, 31-034 Kraków, Poland

Phone: +48 12 422 95 11; E-mail: j.walocha@uj.edu.pl

**Abstract:** The purpose of this study was to examine the height of the main septum (MS) in the sphenoid sinuses and its type, depending on the percentage prevalence of its tissue composition (osseous and membranous) in the adult population.

**Materials and Methods:** A retrospective analysis of 296 computed tomography (CT) scans (147 females, 149 males) of the paranasal sinuses was conducted. The patients did not present any pathology in the sphenoid sinuses. The CT scans of the paranasal sinuses were carried out with a spiral CT scanner (Siemens Somatom Sensation 16) in a standard procedure, in the option Siemens CARE Dose 4D. No contrast medium was used. Having obtained the transversal planes, a secondary reconstruction tool (multiplans reconstruction — MPR) was used in furtherance of gleaning sagittal and frontal planes.

**Results:** In all cases, the height of the MS was measured by using a straight line running parallel to the course of the septum (when the MS was regarded as straight) or curved (when the MS was regarded as irregularly shaped). The average height of the MS was  $2.1 \pm 0.41$  cm in the whole research group. Completely osseous MS was found in 32.77% of the patients. In 63.85% of them, the MS was partially membranous. The rarest was the MS which was not even partially ossified — a membranous type, that was observed in 3.38% of the patients.

**Conclusions:** Variant anatomy of the paranasal sinuses may lead to complications encountered during a surgery, hence a CT scan is advised before the planned treatment.

**Keywords:** main septum, sphenoid sinus, FESS.

**Submitted:** 27-Feb-2020; **Accepted in the final form:** 18-Oct-2020; **Published:** 30-Nov-2020.

## Introduction

Pneumatic spaces known as sphenoid sinuses are localised in the diaphysis of the sphenoid bone and are lined with mucous membrane. Their morphology is varied to a great extent. They differ in size, shape, number of septa present and the degree to which they fill in with air [1, 2].

The closeness of nervous and vascular structures (neighbouring with the sinuses' walls), as well as their own anatomy, are of dire importance while having a surgery in this region. Evaluation of sinuses' anatomical parameters before the invasive intervention (surgery and endoscopy) is crucial, in furtherance of diminishing the surgical risk and avoiding potential complications during the surgery [3–13].

One of the most accurate methods of obtaining images of the paranasal sinuses is computed tomography (CT). Variations in the anatomical structure of the sinuses can be detected via this method, owing to the exact representation of the osseous structures.

In the recent years it was possible to notice the dynamic development of the functional endoscopic sinus surgery (FESS) [14, 15]. The usage of the minimally invasive endoscopic interventions allows to curtail the number of performed classical extensive surgeries in the paranasal sinuses.

Since the beginning of the 1990s, the aforementioned technique is commonly regarded as a method by choice in the surgical treatment of the chronic inflammatory states in the paranasal sinuses. Endoscopic techniques provide a good insight into the hardly accessible places, lessen the traumatisation and help obtain a shorter period of convalescence in comparison to the classical operations [4, 16].

## Materials and Methods

The study was conducted as a retrospective analysis of 296 CT scans of the patients (147 females, 149 males) referred to the Department of Medical Imaging of the University Hospital in Kraków, Poland. Patients over 18 years of age who did not present any pathology in the sphenoid sinuses were included in the research. The study exclusion criteria comprised also of: a head trauma or nasal, orbital or cranial basis surgery undergone in the past.

Spiral CT scanner (Siemens Somatom Sensation 16) was used to obtain the images in this study. A standard procedure applied, in the option Siemens CARE Dose 4D, without the use of any contrast medium. In order to glean sagittal and frontal planes, a secondary reconstruction tool (multiplans reconstruction — MPR) was used after obtaining the transverse planes. While analysing the imaging data, diagnostic station Siemens Volume Wizard was used.

The evaluation of the obtained images involved both height and type of the main septum (MS) — the height was measured in centimetres from the inferior to the

superior wall of the sphenoid sinuses in the straight line (if the MS was regarded as straight) or in the curved line (if the MS was regarded as irregular). In each case, absolute height of the MS was measured, relative to five threshold values in the Hounsfield units (H.u.): -200 H.u., -100 H.u., 0 H.u., 100 H.u., 200 H.u.; MS completely osseous was considered as such when its density did not go below 200 H.u.; MS incompletely osseous (partially membranous) was considered as such when its tinting parts were below 200 H.u. (up to -200 H.u.).

## Results

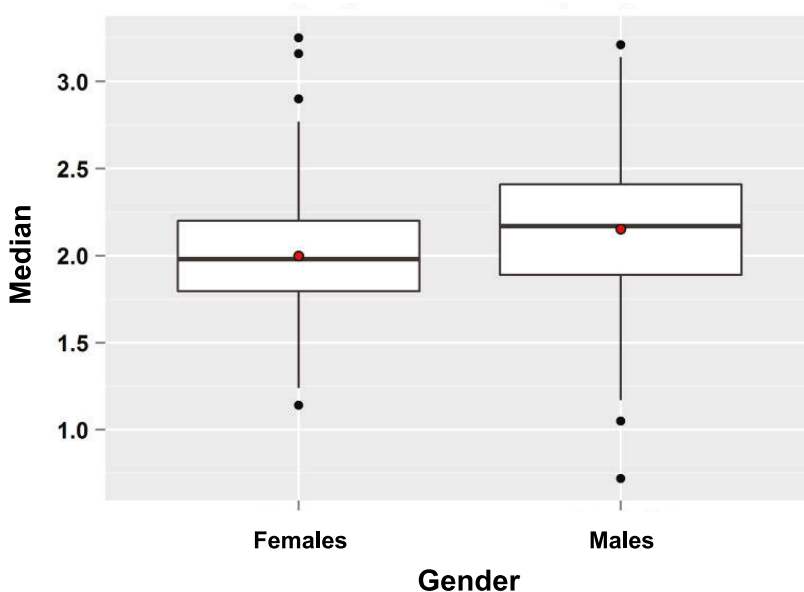
In each case the height of the MS was measured by using a straight line running parallel to the septum (when the MS was considered as straight) or curved (when the septum was considered irregular). The average height of the MS was  $2.1 \pm 0.41$  cm (in the range of 0.72–3.25 cm) in the whole research group. A statistically significant difference was found between the females and males in the average height of the MS ( $p = 0.001$ , t-Student test for the independent variables). The females had a lower average of the MS ( $2.00 \pm 0.38$  cm in the interval of 0.72–3.21 cm) than the males did ( $2.15 \pm 0.43$  cm in the interval of 1.14–3.25 cm) (Table 1, Fig. 1–4).

**Table 1.** The height of the main septum (MS) in centimetres. F — females, M — males.

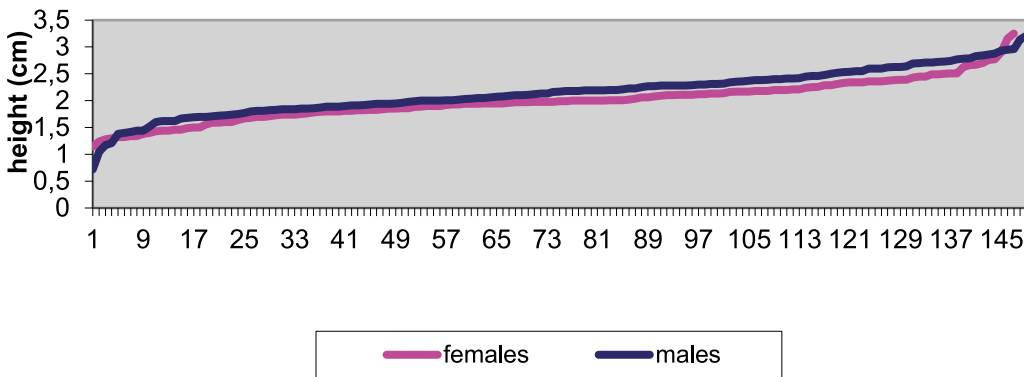
Height of the MS (cm)	F	M	F + M
Average	2	2.15	2.1
Standard deviation	0.38	0.43	0.41
The lowest	1.14	0.72	0.72
The highest	3.25	3.21	3.25

A completely osseous MS was found in 97 patients (53 females, 44 males). In 189 cases (90 females, 99 males), the MS was partially membranous. The rarest variant was the MS that did not undergo even partial ossification — a membranous one, which was observed in 10 patients (4 females, 6 males).

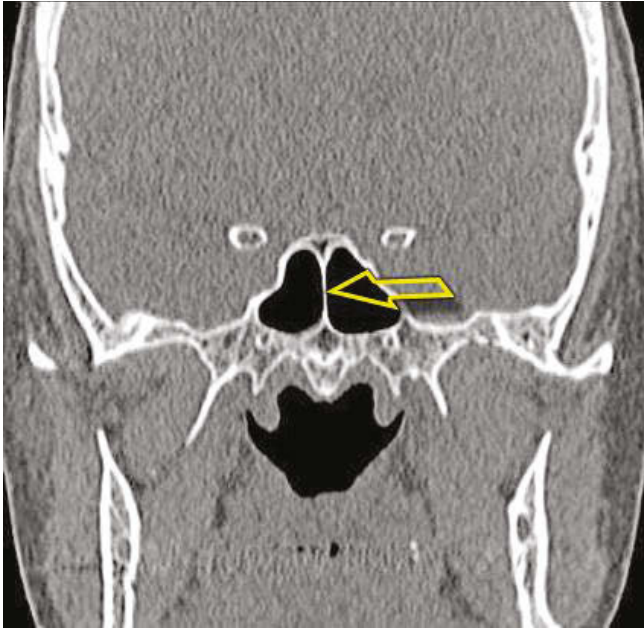
No statistically significant differences were found between the males and females in case of the septum's type ( $p = 0.438$ ,  $\chi^2$  test). The percentage distribution of the types of the MS is very approximate for both genders. In both groups, the partially membranous MS predominates (around 60–65%) (Table 2, Fig. 5–9).



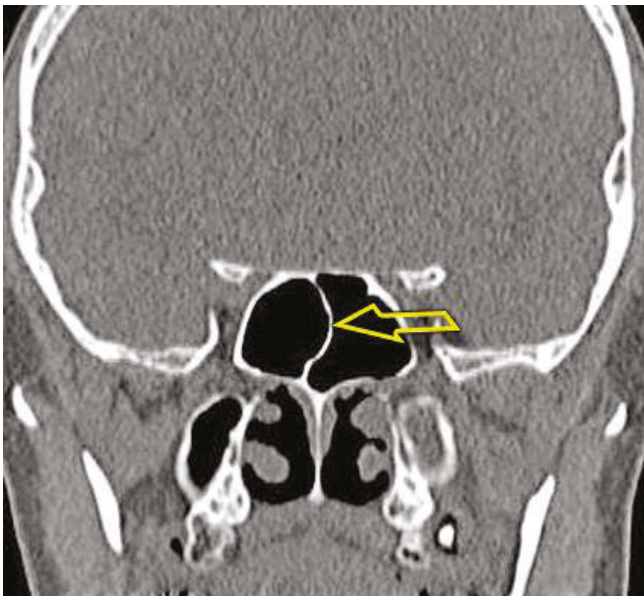
**Fig. 1.** The distribution of the height of the main septum in the females and males. The horizontal line represents the median value in the respective group. The box represents the value of the lower quartile (Q1) and the upper quartile (Q3). The whiskers (the vertical lines) represent the range of the data. The average values in each group were marked as the red dots.



**Fig. 2.** The distribution of the height of the main septum in females and males.



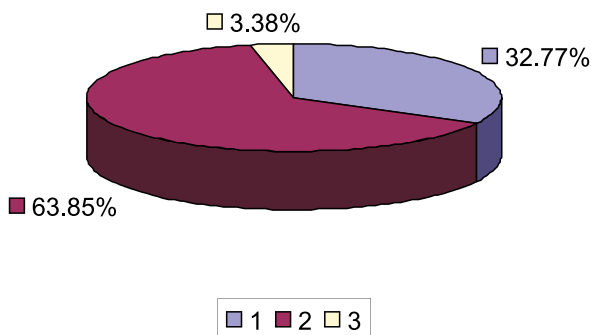
**Fig. 3.** A CT scan of the paranasal sinuses, frontal plane. A straight main septum.



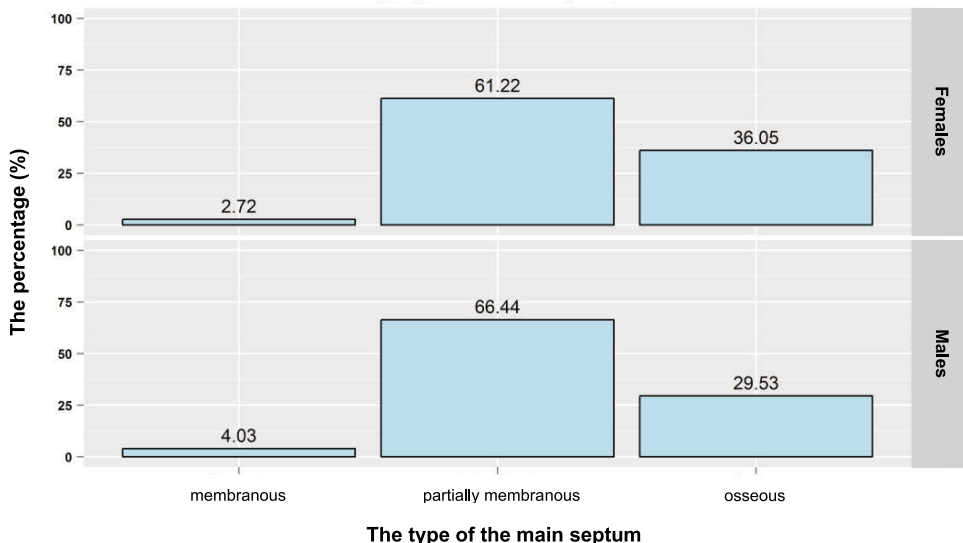
**Fig. 4.** A CT scan of the paranasal sinuses, frontal plane. An irregularly shaped main septum.

**Table 2.** The type of the main septum — osseous, partially membranous, membranous. MS — main septum, F — females, F% — the percentage of females, M — males, M% — the percentage of males.

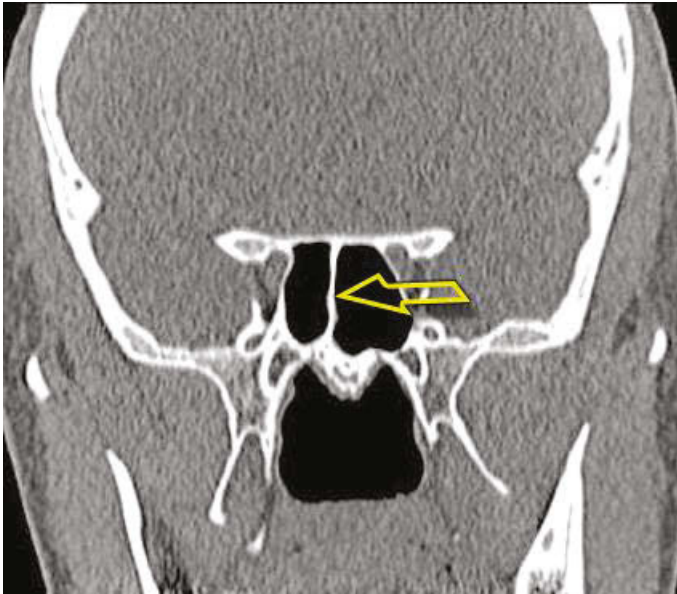
MS	F	F%	M	M%	F + M	F + M%
Osseous	53	36.05%	44	29.53%	97	32.77%
Partially membranous	90	<b>61.22%</b>	99	<b>66.44%</b>	189	<b>63.85%</b>
Membranous	4	2.72%	6	4.03%	10	3.38%



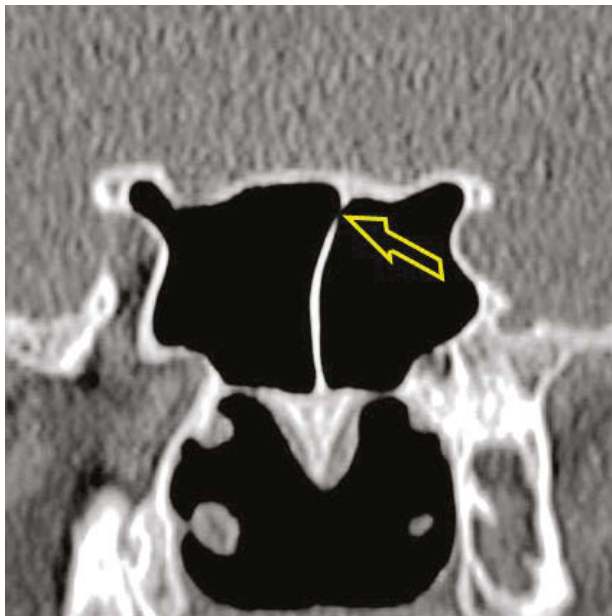
**Fig. 5.** The prevalence of the types of the main septum (MS) in the total research group. 1 — completely osseous MS (32.77%), 2 — partially membranous MS (63.85%), 3 — completely membranous MS (3.38%).



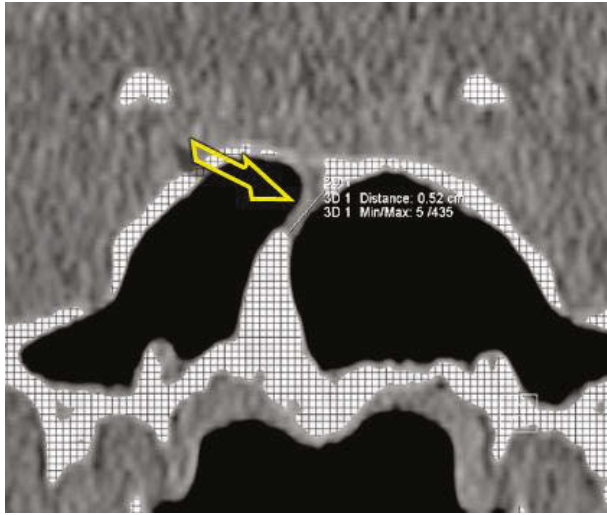
**Fig. 6.** The percentage distribution of the types of the main septum in females and males.



**Fig. 7.** A CT scan of the paranasal sinuses, frontal plane. A completely osseous main septum.



**Fig. 8.** A CT scan of the paranasal sinuses, frontal plane. A partially membranous main septum (the arrow points to the membranous part of the septum).



**Fig. 9.** A CT scan of the paranasal sinuses, frontal plane. A partially membranous septum (the membranous part of the septum is measured on the image).

## Discussion

The average height of the MS was 2.075 cm (in the range of 0.72–3.25 cm). The total height of the septum relies upon its course (straight or curved). Almost in every case the MS was curved, and its height was usually different to the height of the sphenoid sinuses.

During this research, no other studies have been found that would refer to the height of the MS of the sphenoid sinuses.

Sareen *et al.* noted that the vertical dimension of the sphenoid sinuses is on average 2.2 cm (in the range of 1.4–3.6 cm) [12]. Notwithstanding, according to our study, the vertical dimension of the sphenoid sinuses is the same as the vertical dimension of the MS only when the MS has a straight course (Table 3).

**Table 3.** The average height of the main septum (MS).

Author (materials and methods)	The height of the MS (cm)
Sareen <i>et al.</i> (20 skulls, dissection study)	2.2
Jaworek-Troć <i>et al.</i> (296 CT scans)	2.075

The most common type of the MS was the mixed type — a partially ossified, partially membranous that was present in 63.85% of the patients. A completely ossified septum was found in 32.77% of the patients. The rarest type of the MS — noticed



in only 3.38% of the cases — was a completely membranous type. In the literature regarding the topic only Dundar *et al.* make note of the frequency prevalence of the completely and incompletely ossified MS. However, their results are very much different — they estimate the completely ossified MS as 60.5% of cases (132/218), not fully ossified as 30.2% of cases, but they did not find any completely membranous MS in the research material of 218 patients (in the CT scans) [17]. Nonetheless, the aforementioned scientists did not state the way of measuring nor the inclusion criteria for the MS to each type — the said criteria may have a fundamental relation to the dissimilar results, as well as the ethnic group used in the study — Turkish (Table 4).

**Table 4.** The frequency prevalence of the types of the main septum (MS).

Author (materials and methods)	Osseous MS	Mixed MS	Membranous MS
Dundar <i>et al.</i> (218 CT scans)	60.5%	30.2%	0%
Jaworek-Troć <i>et al.</i> (296 CT scans)	32.77%	63.85%	3.38%

## Conclusions

1. The average height of the MS was  $2.1 \pm 0.41$  cm in the whole research group.
2. The majority of patients had a mixed type of the MS (partially ossified, partially membranous).
3. In order to avert potential complications whilst carrying out a planned surgical intervention in this region, a CT scan is recommended due to the high incidence of the anatomical variants of the paranasal sinuses.

## Conflict of interest

None declared.

## References

1. Jaworek-Troć J., Zarzecki M., Bonczar A., Kaythampillai L.N., Rutowicz B., Mazur M., Urbaniak J., Przybycień W., Piątek-Koziej K., Kuniewicz M., Lipski M., Kowalski W., Skrzat J., Loukas M., Walocha J.: Sphenoid bone and its sinus — anatomo-clinical review of the literature including application to FESS. *Folia Med Crac.* 2019; 59 (2): 45–59. doi: 10.24425/fmc.2019.128453.
2. Jaworek-Troć J., Zarzecki M., Mróz I., Troć P., Chrzan R., Zawiliński J., Walocha J., Urbanik A.: The total number of septa and antra in the sphenoid sinuses —

- evaluation before the FESS. *Folia Med Crac.* 2018; 58 (3): 67–81. doi: 10.24425/fmc.2018.125073.
3. *Abdullah B.J., Arasaratnam A., Kumar G., Gopala K.*: The sphenoid sinuses: computed tomographic assessment of septation, relationship to the internal carotid arteries and sidewall thickness in the Malaysian population. *J HK Coll Radiol.* 2001; 4: 185–188.
  4. *Eryilmaz A., Ozeri C., Bayiz U., Samim E., Gocmen H., Akmansu H., Safak M.A., Dursun E.*: Functional endoscopic sinus surgery (FESS). *Turk J Med Res.* 1993; 11 (5): 221–223.
  5. *Haetinger R.G., Navarro J.A.C., Liberti E.A.*: Basilar expansion of the human sphenoidal sinus: an integrated anatomical and computerized tomography study. *Eur Radiol.* 2006; 16: 2092–2099.
  6. *Kantarci M., Karasen R.M., Alper F., Onbas O., Okur A., Karaman A.*: Remarkable anatomic variations in paranasal sinus region and their clinical importance. *European Journal of Radiology.* 2004; 50: 296–302.
  7. *Kazkayasi M., Karadeniz Y., Arikan O.K.*: Anatomic variations of the sphenoid sinus on computed tomography. *Rhinology.* 2005; 43: 109–114.
  8. *Keast A., Yelavich S., Dawes P., Lyons B.*: Anatomical variations of the paranasal sinuses in Polynesian and New Zealand European computerized tomography scans. *Otolaryngology-Head and Neck Surgery.* 2008; 139: 216–221.
  9. *Mafee M.F., Chow J.M., Meyers R.*: Functional endoscopic sinus surgery: anatomy, CT screening, indications and complications. *AJR.* 1993; 160: 735–744.
  10. *Mutlu C., Unlu H.H., Goktan C., Tarhan S., Egrilmez M.*: Radiologic anatomy of the sphenoid sinus for intranasal surgery. *Rhinology.* 2001; 39: 128–132.
  11. *Perez-Pinas I., Sabate J., Carmona A., Catalina-Herrera C.J., Jimenez-Castellanos J.*: Anatomical variations in the human paranasal sinus region studied by CT. *J Anat.* 2000; 197: 221–227.
  12. *Sareen D., Agarwail A.K., Kaul J.M., Sethi A.*: Study of sphenoid sinus anatomy in relation to endoscopic surgery. *Int J Morphol.* 2005; 23 (3): 261–266.
  13. *Terra E.R., Guedes F.R., Manzi F.R., Boscolo F.N.*: Pneumatization of the sphenoid sinus. *Dentomaxillofacial Radiology.* 2006; 35: 47–49.
  14. *Becker D.G.*: The minimally invasive, endoscopic approach to sinus surgery. *Journal of Long-Term Effects of Medical Implants.* 2003; 13 (3): 207–221.
  15. *Bogusławska R.*: Badanie zatok przynosowych metodą tomografii komputerowej dla celów chirurgii endoskopowej nosa i zatok. Warszawa 1995.
  16. *Krzieski A., Osuch-Wójcikiewicz E., Szwedowicz P., Tuszyńska A.*: Chirurgia endoskopowa w leczeniu guzów jam nosa i zatok przynosowych. *Mag ORL.* 2004; 3 (3): 79–84.
  17. *Dundar R., Kulduk E., Soy F.K., Aslan M., Kilavuz A.E., Sakarya E.U., Yazici H., Eren A.*: Radiological evaluation of septal bone variations in the sphenoid sinus. *J Med Updates.* 2014; 4 (1): 6–10.