

DOI 10.24425/pjvs.2023.148282

Original article

PCR-based methods in detection and identification of dermatophytes in dogs and cats with suspected dermatophytosis in 2021 in Poland

D. Jańczak, P. Górecki, A.K. Maj

Animallab Veterinary Laboratory, Śródkowa 2/4, 03-430 Warsaw, Poland

Abstract

Dermatophytes from *Microsporum*, *Trichophyton* and *Epidermophyton* genera are divided into geophilic, zoophilic and anthropophilic species which cause skin infection in humans and wide group of animals, mainly mammals. Main species causing dermatophytosis in dogs and cats are *Microsporum* and *Trichophyton*. Conventional mycological diagnostic technique includes Saburaud Dextrose Agar (SAD) and others medium cultures, 10% KOH mount and direct microscopy of hairs and scraping. Molecular diagnostic become more frequent in veterinary practice due to shortening of waiting time. In this study we based on two PCR methods. The nested PCR amplified CHS1 gene for dermatophytes detection, and multiplex PCR coding ITS1 and ITS2 fragments for species identification of detected derpatophytes. Most frequently detected species was *Microsporum canis*, mainly in young cats. Geophilic *Microsporum gypseum* and anthropophilic *Trichophyton rubrum* was found primarily in dogs. Molecular methods in dermatophytosis identification are rapid in contrast to routinely, long lasting culture.

Keywords: dermatophytes, dogs, cats, Poland, nested PCR, multiplex PCR

Introduction

Dermatophytes are keratinophilic fungi that cause skin infections. The three main zoonotic dermatophytes genus *Microsporum*, *Trichophyton* and *Epidermophyton* can cause diseases in humans and animals. We can divide these genera into anthropophilic, zoophilic and geophilic species (Moriello 2004). Fungi with important role for veterinary medicine include *Microsporum* and *Trichophyton* species which cause a skin disease

in companion animals, mainly dogs and cats (Weitzman and Summerbell 1995, Moriello 2003, Hill et al. 2006, Haggag et al. 2017). Humans mainly become infected by anthropophilic and zoophilic species, rarely by geophilic fungi (Hay 2005). The study carried in Poland among farmers and non-farmers in eastern Poland has shown the prevalence of dermatophytes 64/116 (55.2%) in farmers and 35/74 (47.3%) in non-farmers. Among zoophilic and geophilic species *Trichophyton verrucosum* was identified in 3 farmers. Both,

Trichophyton terrestrae and *Microsporum gypseum* was found in one farmer. In non-farmers *Microsporum canis* in two persons, and one species in each patient: *Trichophyton verrucosum*, *Trichophyton mentagrophytes* var. *mentagrophytes*, *Microsporum nanum* and *Trichophyton terrestrae* (Spiewak and Szostak 2000). *Microsporum canis* causes more than 90% infections in cats, but also in other animals like dogs, rabbits, goats, guinea pigs, tigers, mice and monkeys (Frymus et al. 2013). In a 15-year-period a study in Italy confirms high prevalence of dermatophytosis in dogs (18.7%) and cats (24.7%) and a significant advantage of *Microsporum canis* infection in dogs (83%) and cats (97%) (Mancianti et al 2002). *Trichophyton mentagrophytes* is mainly isolated from rodents, guinea pigs, chinchillas and mice, but also from dogs and cats (Drouot et al. 2009, Bloch et al. 2016, Bartosch et al. 2018). One of the objectives of this study was direct and rapid detection of dermatophytes in specimens and species identification from positive samples. In addition, evaluation of infection rate among dogs and cats with clinically suspected dermatophytosis.

Materials and Methods

In 2021, 752 samples of hairs, skin scrapings or claws from 312 dogs and 436 cats with clinical suspicion of dermatophytosis were collected in commercial veterinary laboratory. Samples were sent by veterinarians as a part of the laboratory service tests, therefore the Ethic Commission Agreement is not required. Collected claws were mechanically homogenized before DNA isolation. Hairs were cutted into small fragments. Scrapings were used directly in isolation protocol without any pre-treatment. The manual DNA extraction method was performed according to the manufacturer's instructions with addition of 20 µl 0.1 M dithiothreitol during the first step of isolation (Sherlock AX, A&A Biotechnology). Incubation at 50°C was continued until all specimens was lysed. The obtained DNA was frozen for further tests. Samples were firstly tested by nested-PCR protocol targeting the CHS1 gene (Garg et al. 2007). The first PCR-round was performed in a 25 µl reaction mixture containing 12.5 µl StartWarm HS-PCR Mix (A&A Biotechnology) 1.5 µl each primer specific for dermatophytes CHS1 gene, 6.5 µl ddH₂O and 3 µl of genomic DNA. The first PCR run using primers CHS1 1S (5'-CATCGAGTACATGTGCTCGC-3') and CHS1 1R (5'-CTCGAGGTCAAAGCAGCC-3') amplify a 435-bp DNA fragment of CHS1 gene was performed. For the nested-PCR pair of primers: JF2 (5'-GCAAAGAAGCCTGGAAGA AG-3') and JR2 (5'-GGAGACCATCTGTGAGAGTTG-3') amplifying

a 288 bp DNA fragment of the internal sequence of the first-round PCR amplicon were used. The first-round PCR products were diluted 1:10 with deionized water, and 3 µl were used in nested-PCR. PCR was carried out by an initial denaturation at 95°C for 3 min, followed by 35 cycles of denaturation at 95°C for 30s, annealing at 60°C for 60s, extension at 72°C for 60s, and a final extension at 72°C for 10 min in a PCR thermocycler (MultiGene optiMAX, Labnet International, Inc.). In contrast to PCR, nested-PCR annealing temperature was 63°C and the number of cycles was increased to 45. Amplified products were analyzed on 2% agarose gel (Fig.1).

Positive samples in nested-PCR were further tested with multiplex assay using primers coding ITS1 and ITS2 region: forward ITS1-2 5'-ATCATTAACGCG CAGGC-3', and reverse ITS1-2 5'-TGGCCACTGC TTTTCGG-3' (Kim et al. 2011). Multiplex PCR was performed in a 50 µl reaction mixture containing 25 µl StartWarm HS-PCR Mix (A&A Biotechnology) 3 µl each primer ITS1-2, 14 µl ddH₂O and 5 µl of genomic DNA. Reaction conditions were as follows: 3 min of initial denaturation at 95°C, followed by 35 cycles at 95°C for 30 s, annealing at 60°C for 60 s, extension at 72°C for 60 s with final extension at 72°C for 10 minutes. Results of multiplex PCR analysis for specific primer (ITS1-2) are shown in Fig. 2.

Results

Overall, of the 752 dogs and cats with clinically suspected dermatophytosis, 18.5% (139/752) were positive in nested-PCR. Out of the 312 dogs, 9.9% (31/213) were positive for dermatophyte infection including *Microsporum gypseum* 38.7% (12/31), *Trichophyton rubrum* 32.3% (10/31), *Microsporum canis* 25.8% (8/31) and *Trichophyton tonsurans* 3.2% (1/31). Among the 436 cats, 24.8% (108/436) were positive for dermatophytosis caused by *Microsporum canis* 96.3% (104/108) and *Trichophyton mentagrophytes* 3.7% (4/108). No mixed fungal infection was found. *Microsporum canis* infection was confirmed in 83 cats out of 87 infected animals younger than 1 year of age. Rate of fungal infection among cats is decreasing with their age. Table 1 shows dermatophytes infections by age among dogs and cats.

Discussion

Animal dermatophytoses are caused by zoophilic or geophilic species of dermatophytes (Segal and Elad 2021). Our study has shown six cases of *Trichophyton rubrum* infection in dogs, which is considered as

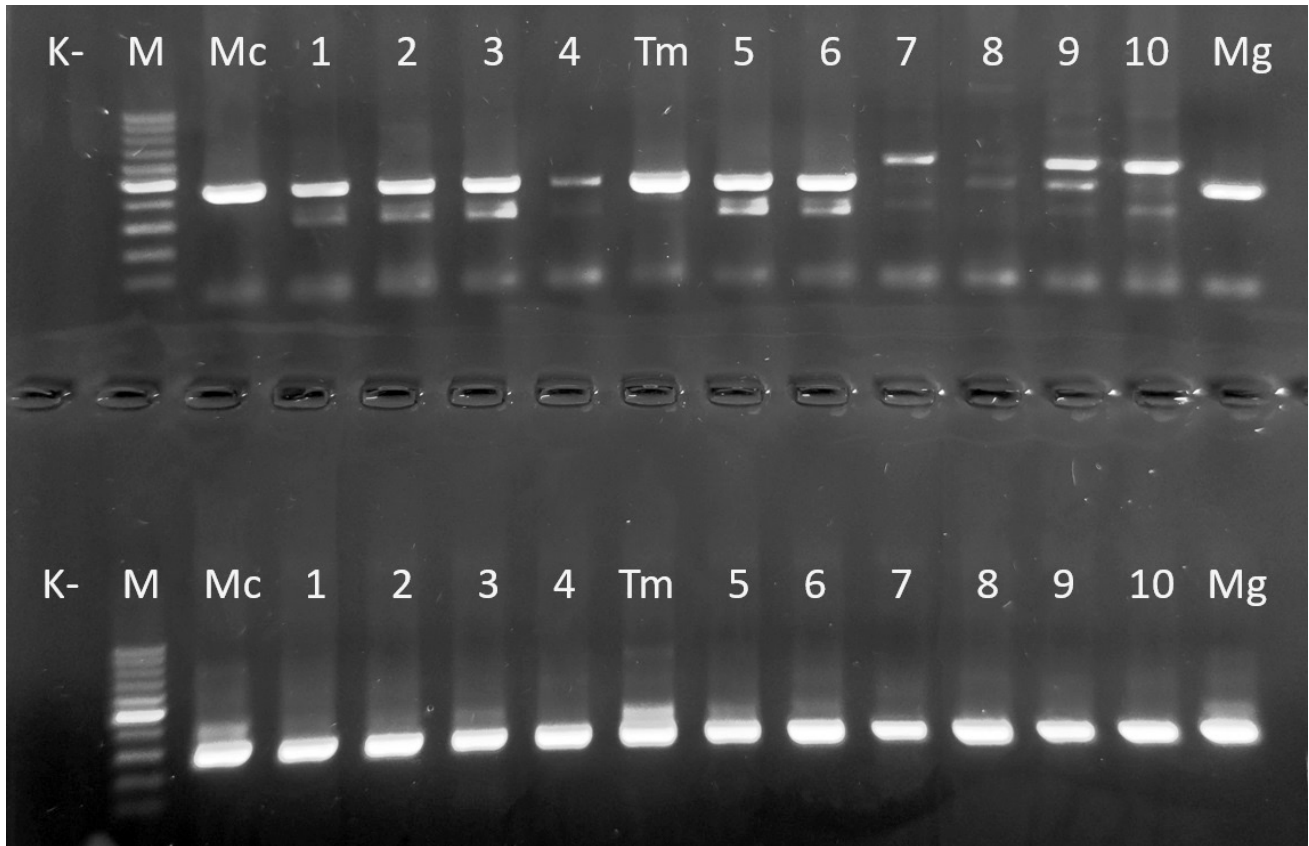


Fig. 1. Results of PCR-435 bp (top row) and nested-PCR-288 bp (lower row) of clinical specimens from dogs and cats; positive controls: Mc – *Microsporium canis*, Tm – *Trichophyton mentagrophytes*, Mg – *Microsporium gypseum*; lanes: 1, 2, 3, 5, 6 – positive samples (hairs); lanes: 4, 7, 8 – positive samples (claws); lanes: 9, 10 – positive samples (skin scrapings); K- (negative control ddH₂O); M – 100-bp DNA ladder (Marker 1, A&A Biotechnology).

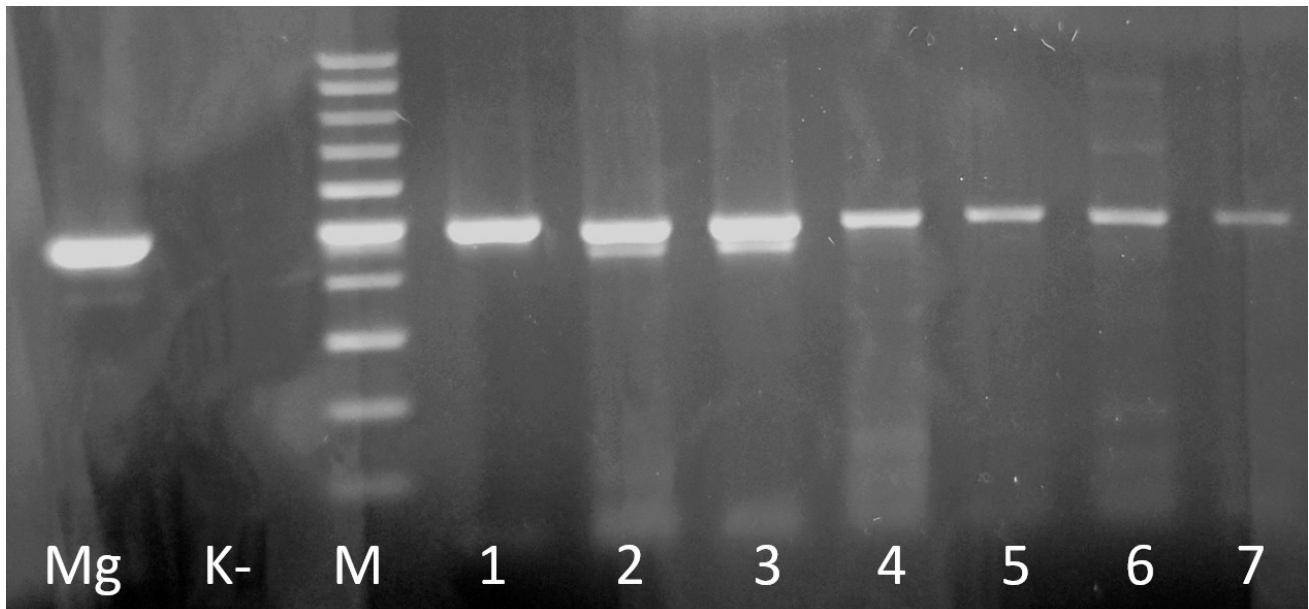


Fig. 2. Results of multiplex PCR of clinical specimens from dogs and cats; positive control: Mg – *Microsporium gypseum*; lanes: 1, 2, 3 – positive samples *Trichophyton mentagrophytes*; lanes: 4, 5, 6, 7 – positive samples *Trichophyton rubrum*; K- (negative control ddH₂O); M – 100-bp DNA ladder (Marker 1, A&A Biotechnology).

Table 1. Dermatophyte infections among dogs and cats in different age groups.

	< 1 year		1-4 years				> 4 years						
	dogs (122)		cats (259)		dogs (112)		cats (93)		dogs (78)		cats (84)		
nested PCR (+)	17	13.9%	87	33.6%	12	10.7%	16	17.2%	2	2.6%	5	6.0%	
multiplex PCR	<i>M. canis</i>	11	9.0%	83	32.0%	-	-	16	17.2%	-	-	5	6.0%
	<i>M. gypseum</i>	-	-	-	-	10	8.9%	-	-	2	2.6%	-	-
	<i>T. mentagrophytes</i>	-	-	4	1.5%	-	-	-	-	-	-	-	-
	<i>T. rubrum</i>	6	4.9%	-	-	1	0.9%	-	-	-	-	-	-
	<i>T. tonsurans</i>	-	-	-	-	1	0.9%	-	-	-	-	-	-

anthropo-zoonotic pathogen, mostly infecting humans (Hubálek and Rudolf 2010). Yamada et al. (1991) have described a case of 3-year-old female of Yorkshire Terrier. The dog had a long story of chronic pyoderma skin lesions and treatment. Infection of *T. rubrum* has been detected by culture on Sabouraud dextrose agar medium. However, cases of human infection caused by *T. rubrum* are not that rare. The infection affects the skin between toes (tinea) and toe nails (onychomycosis). The highest percentage of infections include people between 20 and 59 years (Lee et al. 2015). Therefore, hypothetically there is a possibility that close contact with an infected person may cause transmission to dogs.

In our study more than 96% and 25% of infection was caused by *Microsporum canis* in cats and dogs respectively. This species is the most often diagnosed in dogs and cats worldwide (Boyanowski et al. 2000, Mancianti et al. 2002, Copetti et al. 2006, Frymus et al. 2013). The same species is considered as the most zoonotic agent that cause dermatophytosis of head skin, body and face mainly in children (Weitzman and Summerbell 1995, Hermoso de Mendoza et al. 2010). In animals *M. canis* infection may cause an alopecia in the middle and around infected area. Alopecia may occur permanent if the infection is long lasting (Sakuragi et al. 2016). Many factors have the influence on type of the infection, including species of dermatophyte, its virulence, environmental humidity, area of the infected skin and other systemic or skin infections (Aktas and Yigit 2015). However, no significant difference in dermatophyte infection between FIV (feline immunodeficiency virus) and FeLV (feline leukemia virus) positive and seronegative cats was found (Sierra et al. 2000). Even a positive result for *Microsporum* in cats infected with FIV, may do not correlate with clinical signs of the fungal infection (Manciani et al. 1992). Immunosuppression caused by immunosuppressive treatment is also one of the predisposing factors, but it's not common (Olivry et al. 2000, Cafarchia et al. 2004, Moriello et al. 2017). Moreover, immunosup-

pressive treatment including steroids in patient with clinical signs of dermatophytosis should be considered with caution (Czaika and Lam 2013). Unfortunately, it was practically impossible to obtain information regarding the immunological status of animals tested in our study. One of the most important information we obtained was the age of dogs and cats. Kittens and puppies living in high density in a cattery or kennel are more susceptible to infection, in contrast to adult animals (Mancianti et al. 2002, Czaika and Lam 2013, Frymus et al. 2013). Infections caused by *Trichophyton* species are more common in dogs and outdoor cats which may have contact with rodents and others wild animals or their habitat (Gnat et al. 2019). *Microsporum gypseum* infections are often identified in hunting dogs, like Shorthaired German Pointer, Pointer, Irish Setter which is explained by frequent contact with soil containing arthrospores of *Microsporum* species (Carlotti and Bensignor 1999).

Routine identification of a fungal infection includes culture on various media like Sabouraud Dextrose Agar, Potato Dextrose Agar, Cornmeal Agar with Tween 80 or Inhibitory Mold Agar with chloramphenicol. All of them are important in isolation of pathogenic fungi like *Cryptococcus* or *Candida* species and dermatophytes (Collins et al 2005, Basu et al. 2015). Fungal culture is regarded as the gold standard, but the method of obtaining the samples is crucial (Moriello et al. 2017, Bajwa 2020). Three sampling methods are often used by clinicians - hair coat brushings, hair plucking and sampling by sticking tape (Moriello et al. 2017). Skin scrapings can be useful in dermatophytes diagnostic using 10% KOH solution (Garg and Gupta 2020). Human nails and animal claws can be used directly in culture and KOH mount or molecular diagnostic after pre-treatment includes homogenization or crushing in liquid nitrogen (Garg et al. 2007). Molecular diagnostic is a rapid diagnostic test, with good sensitivity and specificity which reveals from 74% to 100% depending on PCR techniques (Garg et al 2007, Luk et al. 2012, Moriello et al. 2017, Pihet and Givic 2017).

Brillowska-Dabrowska et al. (2013) have evaluated *M. canis*-specific PCR test which has 100% sensitivity and specificity regardless of the used clinical specimens. In our study we used PCR technique based on the amplification of the CHS1 gene which is one of the most used targets in molecular diagnosis of dermatophytosis in humans (Kano et al. 1998, Garg et al. 2007, Luk et al. 2012). The CHS1 gene is used as target because it is shared by the three genera *Trichophyton*, *Epidermophyton* and *Microsporum* causing infection among humans and animals (Dhib et al. 2012). Conventional PCR is commonly used as rapid and good cost-benefit ratio (Petrucci et al. 2020). In our study, we have chosen a PAN-Dermatophyte nested PCR developed by Garg et al. (2007) to increase a sensitivity of detection from different animal specimens (hairs, scrapings, claws), and also, to avoid detection of non-dermatophytes. However, high sensitivity may detect dermatophytes in specimens from non-infected carrier, without any clinical signs (Bajwa 2020). For identification of detected in nested PCR dermatophytes, multiplex PCR protocol targeting the ITS1-2 gene was used. Developed by Kim et al. (2011) multiplex PCR protocol includes detection and identification of main dermatophyte species causing infection in dogs and cats. Species identification was based on multiplex PCR product size which were compared with positive controls. Despite the high sensitivity, PCR methods can be used to control the effectiveness of dermatophytosis treatment (Bajwa 2020).

Conclusions

In this study, we demonstrated the prevalence of dermatophytes species among dogs and cats with suspected dermatophytosis. Dermatophytes are more often diagnosed in cats in contrast to dogs with clinical signs of skin disease. Infections of *Microsporum canis* mainly affect kittens and cats younger than 1 year of age. Molecular diagnostics is often the method of choice by veterinarians due to reduced result time from 21-28 days of culture to 2-5 days. False negative results may occur due to poor amount of a specimen, wrong place or technique of specimen collection. The results shows that dermatophyte infections are still the major part in small animal dermatology which should be elementary in clinical practice.

References

Aktas E, Yigit N (2015) Hemolytic activity of dermatophytes species isolated from clinical specimens. *J Mycol Med* 25: e25-30.

- Bajwa J (2020) Feline dermatophytosis: Clinical features and diagnostic testing. *Can Vet J* 61: 1217-1220.
- Bartosch T, Frank A, Günther C, Uhrlaß S, Heydel T, Nenoff P, Baums CG, Schrödl W (2018) *Trichophyton benhamiae* and *T. mentagrophytes* target guinea pigs in a mixed small animal stock. *Med Mycol Case Rep* 23: 37-42.
- Basu S, Bose C, Ojha N, Das N, Das J, Pal M, Khurana S (2015) Evolution of bacterial and fungal growth media. *Bioinformatics* 11: 182-184.
- Bloch M, Cavignaux R, Debourgogne A, Dorin J, Machouart M, Contet-Audonneau N (2016) From guinea pig to man: Tinea outbreak due to *Trichophyton mentagrophytes* var. *porcellae* in pet shops in Nancy (France). *J Mycol Med* 26: 227-232.
- Boyanowski KJ, Ihrke PJ, Moriello KA, Kass PH (2000) Isolation of fungal flora from the hair coats of shelter cats in the Pacific coastal USA. *Vet Dermatol* 11: 142-150.
- Brillowska-Dabrowska A, Michałek E, Saunte DM, Nielsen SS, Arendrup MC (2013) PCR test for *Microsporum canis* identification. *Med Mycol* 51: 576-579.
- Cafarchia C, Romito D, Sasanelli M, Lia R, Capelli G, Otranto D (2004) The epidemiology of canine and feline dermatophytoses in southern Italy. *Mycoses* 47: 508-513.
- Carlotti, Bensignor (1999) Dermatophytosis due to *Microsporum persicolor* (13 cases) or *Microsporum gypseum* (20 cases) in dogs. *Vet Dermatol* 10: 17-27.
- Collins MM, Nair SB, Der-Haroutian V, Close D, Rees GL, Grove DI, Wormald PJ (2005) Effect of using multiple culture media for the diagnosis of noninvasive fungal sinusitis. *Am J Rhinol* 19: 41-45.
- Copetti MV, Santurio JM, Cavalheiro AS, Boeck AA, Argenta JS, Aguiar LC, Alves SH (2006) Dermatophytes isolated from dogs and cats suspected of dermatophytosis in Southern Brazil. *Acta Sci Vet* 34: 119-124.
- Czaika VA, Lam PA (2013) *Trichophyton mentagrophytes* cause underestimated contagious zoophilic fungal infection. *Mycoses* 56 (Suppl 1): 33-37
- Dhib I, Fathallah A, Charfeddine IB, Meksi SG, Said MB, Slama F, Zemni R (2012) Evaluation of Chitine synthase (CHS1) polymerase chain reaction assay in diagnosis of dermatophyte onychomycosis. *J Mycol Med* 22: 249-255.
- Drouot S, Mignon B, Fratti M, Roosje P, Monod M (2009) Pets as the main source of two zoonotic species of the *Trichophyton mentagrophytes* complex in Switzerland, *Arthroderma vanbreuseghemii* and *Arthroderma benhamiae*. *Vet Dermatol* 20: 13-18.
- Frymus T, Gruffydd-Jones T, Pennisi MG, Addie D, Belak S, Boucraut-Baralon C, Egberink H, Hartmann K, Hosie MJ, Lloret A, Lutz H, Marsilio F, Mostl K, Radford AD, Thiry E, Truyen U, Hornizek MC (2013) Dermatophytosis in cats: ABDC guidelines on prevention and management. *J Feline Med Surg* 15: 598-604.
- Garg J, Tilak R, Singh S, Gulati AK, Garg A, Prakash P, Nath G (2007) Evaluation of pan-dermatophyte nested PCR in diagnosis of onychomycosis. *J Clin Microbiol* 45: 3443-3445.
- Garg R, Gupta S (2020) Mimickers of dermatophytes on KOH mount. *IP Indian J Clin Exp Dermatol* 6: 98-101
- Gnat S, Nowakiewicz A, Lagowski D, Troscianczyk A, Zieba P (2019) Multiple-strain *Trichophyton mentagrophytes* infection in a silver fox (*Vulpes vulpes*) from a breeding farm. *Med Mycol* 57: 171-180.
- Haggag YN, Samaha HA, Nossair MA, Mohammad RM (2017)

- Prevalence of dermatophytosis in some animals and human in Bahera Province, Egypt. *Alex J Vet Sci* 53: 64-71.
- Hay RJ (2005) Dermatophytosis and other superficial mycoses. In: Mandell GL, Bennett JE, Dolin R (eds) Principles and practice of infectious diseases. 6th ed., Philadelphia, PA: Elsevier, pp 3051-3079.
- Hermoso de Mendoza M, Hermoso de Mendoza J, Alonso JM, Rey JM, Sanchez S, Martin R, Bermejo F, Cortes M, Benitez JM, Garcia WL, Garcia-Sanchez A (2010) A zoonotic ringworm outbreak caused by a dysgonic strain of *Microsporum canis* from stray cats. *Rev Iberoam Micol* 27: 62-65.
- Hill PB, Lo A, Eden CA, Huntley S, Morey V, Ramsey S, Richardson C, Smith DJ, Sutton C, Taylor MD, Thorpe E, Tidmarsh R, Williams V (2006) Survey of the prevalence, diagnosis and treatment of dermatological conditions in small animal general practice. *Vet Rec* 158: 533-539.
- Hubálek Z, Rudolf I (2010) Types of human disease by source of the infectious agent. *Microb Zoon Sapron* 10: 5-8.
- Kano R, Nakamura Y, Watari T, Watanabe S, Takahashi H, Tsujimoto H, Hasegawa A (1998) Molecular analysis of chitin synthase 1 (CHS1) gene sequences of *Trichophyton mentagrophytes* complex and *T. rubrum*. *Curr Microbiol* 37: 236-239.
- Kim JY, Choe YB, Ahn KJ, Lee YW (2011) Identification of dermatophytes using multiplex polymerase chain reaction. *Ann Dermatol* 23: 304-312.
- Lee WJ, Kim SL, Jang YH, Lee SJ, Kim DW, Bang YJ, Jun JB (2015) Increasing prevalence of *Trichophyton rubrum* identified through an analysis of 115,846 cases over the last 37 years. *J Korean Med Sci* 30: 639-643.
- Luk NM, Hui M, Cheng TS, Tang LS, Ho KM (2012) Evaluation of PCR for the diagnosis of dermatophytes in nail specimens from patients with suspected onychomycosis. *Clin Exp Dermatol* 37: 230-234.
- Mancianti F, Giannelli C, Bendinelli M, Poli A (1992) Mycological findings in feline immunodeficiency virus-infected cats. *J Med Vet Mycol* 30: 257-259.
- Mancianti F, Nardoni S, Cecchi S, Corazza M, Taccini F (2002) Dermatophytes isolated from symptomatic dogs and cats in Tuscany, Italy during a 15-year-period. *Mycopathologia* 156: 13-18.
- Moriello KA (2003) Zoonotic skin disease of dogs and cats. *Anim Health Res Rev* 4: 157-168.
- Moriello KA (2004) Treatment of dermatophytosis in dogs and cats: review of published studies. *Vet Dermatol* 15: 99-107.
- Moriello KA, Coyner K, Paterson S, Mignon B (2017) Diagnosis and treatment of dermatophytosis in dogs and cats: Clinical Consensus Guidelines of the World Association for Veterinary Dermatology. *Vet Dermatol* 28: 266-e68.
- Olivry T, Power HT, Woo JC, Moore PF, Tobin DJ (2000) Anti-isthmus autoimmunity in a novel feline acquired alopecia resembling pseudopelade of humans. *Vet Dermatol* 11: 261-270.
- Petrucelli MF, de Abreu MH, Cantelli BA, Segura GG, Nishimura FG, Bitencourt TA, Marins M, Fachin AL (2020) Epidemiology and diagnostic perspectives of dermatophytoses. *J Fungi (Basel)* 6: 310.
- Pihet M, Le Govic Y (2017) Reappraisal of conventional diagnosis for dermatophytes. *Mycopathologia* 182: 169-180.
- Sakuragi Y, Sawada Y, Hara Y, Ohmori S, Omoto D, Haruyama S, Yoshioka M, Nishio D, Nakamura M (2016) Increased circulating Th17 cell in a patient with tinea capitis caused by *Microsporum canis*. *Allergol Int* 65: 215-216.
- Segal E, Elad D (2021) Human and zoonotic dermatophytoses: epidemiological aspects. *Front Microbiol* 12: 713532.
- Sierra P, Guillot J, Jacob H, Bussi eras S, Chermette R (2000) Fungal flora on cutaneous and mucosal surfaces of cats infected with feline immunodeficiency virus or feline leukemia virus. *Am J Vet Res* 61: 158-161.
- Spiewak R, Szostak W (2000) Zoophilic and geophilic dermatophytoses among farmers and non-farmers in Eastern Poland. *Ann Agric Environ Med* 7: 125-129.
- Weitzman I, Summerbell RC (1995) The dermatophytes. *Clin Microbiol Rev* 8: 240-259.
- Yamada C, Hasegawa A, Ono K, Pal M, Kitamura C, Takahashi H (1991) *Trichophyton rubrum* infection in a dog. *Jpn J Med Mycol* 32: 67-71.