

DOI 10.24425/pjvs.2024.152947

Original article

Parasitic survey of birds of prey used for falconry in Poland

A. Prątnicka¹, R. Sokół², M. Iller²

¹ University of Warmia and Mazury in Olsztyn, Faculty of Veterinary Medicine, Department of Parasitology and Invasive Diseases, Parasitology Science Club, Oczapowskiego 13, 10-718 Olsztyn, Poland

² University of Warmia and Mazury in Olsztyn, Faculty of Veterinary Medicine, Department of Parasitology and Invasive Diseases, Oczapowskiego 13, 10-718 Olsztyn, Poland

Correspondence to: M. Iller, e-mail: maria.iller@uwm.edu.pl

Abstract

Birds of prey raised in captivity have direct contact with the environment and are fed raw meat various animals, which increases the risk of infections caused by parasites, including endoparasites. The aim of this study was to evaluate the prevalence of endoparasites in predatory birds of the orders Accipitriformes and Falconiformes that are used in falconry in Poland. Fresh feces were sampled from 52 birds, including 16 saker falcons (*Falco cherrug*), 8 lanner falcons (*Falco biarmicus*), 7 peregrine falcons (*Falco peregrinus*), 8 Harris's hawks (*Parabuteo unicinctus*), 7 Eurasian goshawks (*Accipiter gentilis*), 3 common kestrels (*Falco tinnunculus*), 1 Eurasian sparrowhawk (*Accipiter nisus*), 1 red-tailed hawk (*Buteo jamaicensis*), and 1 common buzzard (*Buteo buteo*). Fecal samples were analyzed with the use of Fülleborn's floatation technique and the McMaster method (OPG/EPG). Dispersive forms of parasites were identified in 17 out of 52 fecal samples (32,69%). Protozoa of the genus *Avispora* and Nematodes of the genera *Porrocaecum* sp and *Capillaria* were detected. The predominant parasites were roundworms (*Porrocaecum* sp) which were identified in 27% of the samples. Polish falconers were surveyed to obtain information about bird rearing conditions, the administered feed, contact with wild fauna, incidence of parasitic infections, and the applied treatments. The survey showed that the housing conditions ensured contact with wild fauna, and the majority of owners (63,6%) feed their birds with part of the game they caught. The majority (81%) of falconers did not notice any clinical signs of infection in their infected birds, indicating the need to examine them regularly. The results of the survey were compared with the findings of the parasitological analysis. This study reports on the prevalence of endoparasites in birds of prey, and the present findings can be used by falconers to optimize the management and welfare of predatory birds.

Keywords: raptors, endoparasites, falconry, Poland



Introduction

Falconry is a traditional practice of keeping, training, and flying predatory birds to hunt wild animals. The process of training falconry birds is known as “manning”. The purpose of manning is to acclimate birds to living with humans, to overcome birds’ natural fear of humans, and to establish a working relationship between the bird and its handler. The International Association for Falconry and Conservation of Birds of Prey (IAF) has 75,000 members in 87 countries. According to the Polish Hunting Association, there are around 150 professional falconers in Poland (Dopierała et al. 2022). Trained falconry birds are used mainly for biological protection to deter undesirable bird species from flying in airports, municipal parks, tree nurseries, orchards, landfill sites, waste processing plants, as well as for environmental education and historical reenactments. The most popular species of falconry birds include the golden eagle (*Aquila chrysaetos*), peregrine falcon (*Falco peregrinus*), saker falcon (*Falco cherrug*), lanner falcon (*Falco biarmicus*), gyrfalcon (*Falco rusticolus*), common kestrel (*Falco tinnunculus*), Eurasian goshawk (*Accipiter gentilis*), Eurasian sparrowhawk (*Accipiter nisus*), Harris’s hawk (*Parabuteo unicinctus*), and red-tailed hawk (*Buteo jamaicensis*). Falconry birds are kept in outdoor aviaries, and they remain in permanent contact with the natural environment. During hunts, falconry birds may also come into contact with other birds of prey. Their diets consist mainly of raw meat of various animal and bird species as a source of essential nutrients for optimal performance. As a result, falconry birds may be susceptible to various diseases, including parasitic infections.

Avisporosis is recognised primarily in captive falcons (Papazahariadou et al. 2001). The coccidia live in the intestines of raptors. Excreted parasites are set free by the feces and it takes them several days to reach infectivity. The life cycle is direct, but also can involve an intermediate host (Krone 2007). Species of *Avispora* infecting raptors tend to be genus specific (Upton and Sundermann 1990). It is possible to detect them in a fecal examination.

Ascarids infections are indicated as more pathogenic for young birds and a potential problem in breeding centers for birds of prey (Forbes 2008). *Porrocaecum* sp are cosmopolitan nematodes that can be detected in fecal examination in birds of prey. In their life cycle, species observed in birds of prey use an intermediate host, such as an earthworm, as well as small mammals as paratenic hosts (Osche 1959). Most adults occur both free and embedded in the intestine (Mawson 1956). Their eggs differ from *Ascaridia* spp. as they are more round-shaped with pitted egg shell. (Hawks and Klann 1997). As the eggs can survive in the environment for

several months (Greve, 1996) recommendations for captive birds include routinely disinfecting feeders and watering troughs, and preventing birds from contacting contaminated soil and feces, for example raising birds on hardware cloth (Mozgovoi 1953, Levine 1968). To reduce risk, access to intermediate hosts should be minimized, possibly eliminated. Freezing products destined for consumption and storing them at -20°C or below for 7 days is one of The US Department of Agriculture recommendations. Mortality associated with ascarid nematodes (Smith 1993) have been reported in captive birds of prey.

Another nematodes infecting birds of prey are *Capillaria* spp. *Capillaria tenuissima* is often found in the small intestine of raptors. *Eucoleus dispar* is the only capillariid species parasite of the oesophagus in terrestrial birds including falcons (Barus and Sergejeva 1989a). Birds of prey can also be infected with *Baruscapillaria falconis* (Yabsley 2008). Ingestion of infected birds, invertebrates such as earthworms, and mammals are considered important for transmission of *Capillaria* in birds of prey (Heidenreich 1997). If earthworm intermediate hosts are required, rodents are believed to serve as paratenic hosts (Olsen 1974). *Eucoleus dispar* has an indirect life cycle with earthworms as intermediate hosts, but a direct life cycle is suspected (Barus and Sergejeva 1989). The life cycles of *B. falconis* and *C. tenuissima* are unknown. (Yabsley 2008). In definitive host larvae burrow in the intestinal mucosa and develop into adult worms in 3-4 weeks (Heidenreich 1997). Fatal infections has been reported in birds of prey such as captive and free-ranging Gyrfalcons (*Falco rusticolus*), Rednecked Falcon (*Falco chicquera*), and Peregrine Falcons (*Falco peregrinus*) (Brüll 1932, Trainer et al. 1968, Cooper 1969, Clausen and Gudmundsson 1981).

Spurious parasitism is possible: reports of eimeriid parasites in raptors in the wild might also include parasites from prey. (Santana-Sánchez G et al. 2015). According to (Hawks and Klann 1997) there is the potential for samples to be contaminated with ova from animals provided as food.

Information on the occurrence of these parasites in falconry birds is scarce and fewer coproscopic diagnosis surveys have been carried. Therefore, the aim of this pilot study was to identify infective-stage endoparasites in predatory birds of the orders Accipitiformes and Falconiformes that are used in falconry.

Materials and Methods

The study was conducted in 2022. Samples of fresh feces (approx. 10 g each) were collected from 9 birds kept in the falcon breeding facility of the Forestry

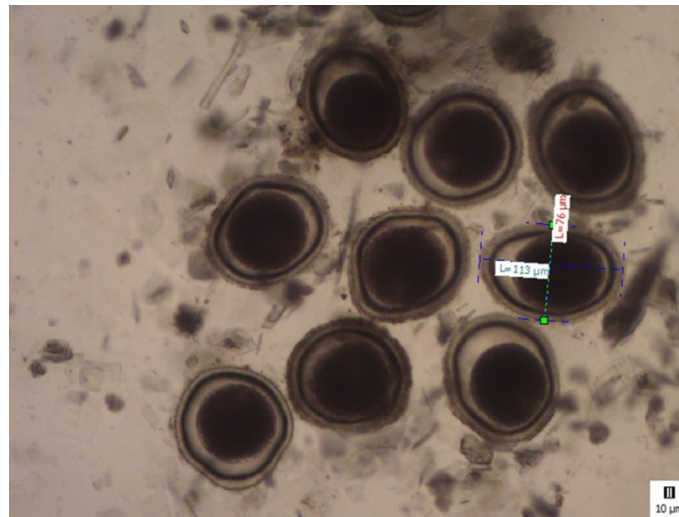


Fig. 1. *Porrocaecum* sp. eggs under the microscope. x10

College (Tuchola, Poland) and from 43 birds kept in aviaries by 12 professional falconers from different cities from different regions of Poland. Feces were sampled directly after defecation over a period of three consecutive days, and they were placed in plastic containers. A single container contained material taken three days from a single bird. The samples were stored in a refrigerator before shipment. A total of 53 52 bulk fecal samples from 9 species of predatory birds, including 16 saker falcons (*F. cherrug*), 8 lanner falcons (*F. biarmicus*), 7 peregrine falcons (*F. peregrinus*), 8 Harris's hawks (*P. uncinatus*), 7 Eurasian goshawks (*A. gentilis*), 3 common kestrels (*F. tinnunculus*), 1 Eurasian sparrowhawk (*A. nisus*), 1 red-tailed hawk (*B. jamaicensis*), and 1 common buzzard (*B. buteo*), were analyzed. The studied population comprised 29 ♂, 22 ♀, and one bird with unconfirmed sex. The age structure of the examined population was as follows: one-year-old birds – 33%, two-year-old birds – 11,5%, three-year-old birds – 23%, four-year-old birds – 11,5%, and birds aged 5-18 years – 17%. The birds came from legal breeding, had a CITES certificate confirming the date of hatching and, in some of the birds, sex. In cases where sex was not inscribed, it was assessed by morphological features. In most of the studied species, there is a marked sexual dimorphism expressed in the size and weight of the birds.

Fecal samples were analyzed with the use of Fülleborn's floatation technique with Darling's solution (samples were centrifuged at 2500 rpm for 5 min) (Gundlach and Sadzikowski 2004) and the McMaster method (Gundlach and Sadzikowski 2004). The number of oocysts (OPG) and eggs (EPG) in 1 gram of feces was counted (Ministry of Agriculture, Fisheries and Food 1986). Each sample was examined after taking 5 different, separate drops of the centrifuged material

onto the slide. The taxonomy was established based on morphologic characteristics. Photos and information from other works on similar subjects were used to mark the parasites (Krone 2007, Davydova 2016)

The study also involved a survey with falconers/bird owners. The survey questionnaire consisted of 12 questions to obtain information about bird rearing conditions, bird behavior, health status, disease symptoms, disease prevention, and anti-parasitic treatments. The surveyed falconers provided information about 46 birds participating in the study.

Results

Dispersive forms of parasites were identified in 17 (32,69%) out of 52 (100%) samples by coproscopic examination. Oocysts of *Avispora* (Apicomplexa Eimeriidae) spp. (OPG 2300, 850) were detected in two samples (2/20 53, 4%), i.e. in 1 ♂ peregrine falcon (2300 OPG) and 1 ♀ Eurasian goshawk (850 OPG). *Porrocaecum* sp. eggs were detected in 14 samples (14/20 52, 27%), i.e. in 1 ♂ peregrine falcon (1075 EPG), 1 ♂ (375 EPG) and 1 ♀ (3075 EPG) Eurasian goshawk, 1 ♂ (400 EPG) and 1 ♀ (2975 EPG) Harris's hawk, 1 ♂ lanner falcon (5250 EPG), 6 ♂ (3225, 4200, 9275, 7450, 14800, 275 EPG) and 1 ♀ (10 475 EPG) saker falcons, and 1 ♂ common buzzard (200 EPG) (Fig. 1). *Capillaria* spp. eggs (EPG 1875, 200, 5700) were identified in three samples (3/ 52, 6%), i.e. in 2 ♂ Eurasian goshawks (1875, 200 EPG) and 1 ♀ Eurasian sparrowhawk (5700 EPG), (Table 1). *Avispora* spp. oocysts were detected in the same number of female and male birds. Parasites were more prevalent in males; *Porrocaecum* sp eggs were identified in 3 ♀ (3/14, 21%) and 11 ♂ (11/14, 79%); *Capillaria* spp. eggs were identified in 1 ♀ (1/3, 33%) and 2 ♂ (2/3, 67 (Fig.2).

Table 1. Parasites identified in different sex and age groups in the studied bird species.

Bird species	Sex and number of studied birds / Sex and number of infected birds / parasite (OPG, EPG)					
	Age/sex	>1 year	2 years	3 years	4 years	5-18 years
Saker falcon (<i>F. cherrug</i>)	♂ 11/6	1/1 A (7450)	3/3 A (4200) A (9275) A (14 800)	3/-	2/2 A (275) A (3225)	2/-
	♀ 5/1	1/1 A (10475)	-	1/-	1/-	2/-
Eurasian goshawk (<i>A. gentilis</i>)	♂ 3/3	3/3 A (375) C (200) C (1875)	-	-	-	-
	♀ 4/2	2/2 E (850) A (3075)	-	-	2/-	-
Lanner falcon (<i>F. biarmicus</i>)	♂ 5/1	2/-	-	2/-	-	1/1 A (5250)
	♀ 3/-	1/-	-	-	-	2/-
Peregrine falcon (<i>F. peregrinus</i>)	♂ 4/2	1/-	3/2 E (2300) A (1075)	-	-	-
	♀ 4/-	-	1/-	2/-	-	1/-
Harris's hawk (<i>P. unicinctus</i>)	♂ 4/1	3	-	-	1/1 A (2975)	-
	♀ 3/1	-	-	2	-	1/1 A (400)
Common kestrel (<i>F. tinnunculus</i>)	♂ 2/-	2/-	-	-	-	-
	♀ 1/1	-	-	1/1 T (50)	-	-
Red-tailed hawk (<i>B. jamaicensis</i>)	♂ 1/-	-	-	1/-	-	-
	♀ -	-	-	-	-	-
Common buzzard (<i>B. buteo</i>)	♂ -	-	-	-	-	-
	♀ 1/1	-	-	1/1 A (200)	-	-
Eurasian sparrowhawk (<i>A. nisus</i>)	♂ -	-	-	-	-	-
	♀ 1/1	1/1 C (5700)	-	-	-	-

E – *Eimeria* spp. oocysts, A – *Ascaridia* spp. eggs, C – *Capillaria* spp. eggs, T – *Trichostrongylus* spp. eggs, * age and sex undetermined

Survey questionnaires were completed by 11 falconers, and their answers were referenced with the results of parasitological examinations of fecal samples.

Contact with wild fauna: Ten out of the 11 surveyed falconers/bird handlers (91%) confirmed that their birds had contact with wild fauna. Two birds infected with *Avispora* spp. came into contact with wild birds (1 bird), as well as snails and earthworms (1 bird). Thirteen of

14 birds infected with *Porrocaecum* sp had contact with other birds (10), as well as snails and earthworms (3). In birds infected with *Capillaria* spp., contact with wild fauna was ruled out in one case, whereas one bird came into contact with wild birds, and one bird – with snails and earthworms.

Housing conditions (aviaries and type of floor): Forty-five birds (98%) were kept in aviaries; 10 birds




Fig. 2. *Capillaria* spp, European sparrowhawk (*Accipiter nisus*). x40

(91%) were kept in outdoor aviaries, and one bird (9%) was kept indoors. All birds infected with *Avispora* spp. (2 birds) were kept on sand in an aviary. Birds infected with *Porrocaecum* sp were kept on gravel/stones (9 birds), on a layer of sand (3 birds), in an aviary/bird house with ground access (1 bird), and indoors on vinyl flooring (1 bird). All birds infected with *Capillaria* spp. were kept on sand.

Diet: All birds infected with *Avispora* spp. (2 birds) were fed day-old chicks, quails, pigeons, and game birds (pheasants and ducks). All birds infected with *Porrocaecum* sp were fed day-old chicks. Some birds were fed pigeons (11 birds), quails (6), game birds (4), poultry necks (5), rats (7), mice (4), roe deer meat (4), and suckling rabbits (4). All birds infected with *Capillaria* spp. (3) were fed day-old chicks and pigeons, and one bird was additionally fed poultry necks, mice, roe deer meat, suckling rabbits, and beef, whereas another bird was also fed hunter-harvested rabbits, pheasants, and ducks. Ten out of the 11 surveyed falconers (91%) fed some of the hunted game to their birds. All birds infected with *Avispora* spp. and *Capillaria* spp. were fed some of the game harvested during hunts. In the group of birds infected with *Porrocaecum* sp, 9 birds (64.29%) were fed wildlife species, whereas 5 birds (35.71%) were not.

Prevalence of parasitic infection: Symptoms of parasitic infection had not been observed by 9 of the 11 surveyed falconers (82%). Two bird handlers (18%) had experience with treating endoparasitic infections. One bird (2%) had been infected with ectoparasites (Mallophaga feeding on birds).

Possible sources of infection: According to the surveyed falconers, parasitic infections could have been caused by pigeon meat, excreta of small birds feeding on remnants in aviaries, earthworms or snails, absence of preventive treatment, or feeding fresh meat (quails)

to the birds. Aviaries were shaded by trees, and they attracted other birds that contaminated aviaries with their feces. Other contributing factors included the proximity of a forest, length of the storage of meat in the freezer, and feeding fresh hunted game to the birds.

Hygiene practices: The surveyed falconers differed considerably in the type and range of the applied hygiene practices. Three falconers who did not report any parasitic infections removed feces from the top layer of the substrate in the aviary, disinfected aviaries, removed food remnants, fed only selected carcass parts (fresh legs) of the hunted game and the remaining parts after freezing/thawing, and regularly collected bird feces for parasitological analyses. Nine falconers regularly dewormed their birds (mainly with toltrazuril), adhered to a strict hygiene and dietary regimen (frozen food only), and did not report any parasitic infections.

Clinical signs observed in confirmed cases of parasitic invasion Clinical signs of ascariasis in the examined birds involved anxiety, chronic hunger, difficulty in maintaining a healthy body weight, distracted and impulsive behavior. Clinical signs of capillariasis in the examined birds included absence of preening, food scattering, reluctance to attack during hunts, poor contact with the handler, atypical head movements resembling swallowing and moving food in the crop, respiratory problems, and considerable changes in body weight. In one bird, a post-mortem examination revealed an adult nematode in the esophagus. Based on the results of the survey, the above clinical signs had been observed in one of the two birds (50%) infected with *Avispora* spp., in two out of 14 birds (14.29%) infected with *Porrocaecum* sp, and in one of the three birds (33.3%) infected with *Capillaria* spp.

Anti-parasitic treatments: In birds with symptoms of infection, the type of applied treatment was based on the results of the parasitological analysis:

- infection with *Avispora* spp. oocysts – Endocox (active ingredient: toltrazuril) administered *per os* with feed at 0.14 ml 3,5 mg/kg, twice daily, at 8 h intervals, over two consecutive days, or Baycox (active ingredient: toltrazuril) administered at 8 mg/kg, once daily over two consecutive days, or diclazuril administered at 7 mg/kg, once daily over three consecutive days, twice at a weekly interval - infection with *Porrocaecum* sp or *Capillaria* spp. eggs: fenbendazole powder was administered *per os* with feed, or fenbendazole gel was administered once at 10 mg/kg with a syringe applicator and the treatment was repeated after 14 days, or fenbendazole was applied at 20 mg/kg, once daily over five days, or Galces Plus tablets were administered at ¼ tablet (Febantel 150.0 mg, Pyrantel pamoate 144.0 mg (equivalent to 50 mg pyrantel), Praziquantel 50.0 mg; crushed and mixed with feed, twice at a weekly interval).

Discussion

Most research has focused on prevalence of endoparasites in bird hospitals, zoos, and in free-living wild birds. Endoparasite infections and their levels have been described in free-living predatory birds in Italy, Germany, Mexico, Austria, and Spain. (Krone et al. 2000, Sanmartin et al. 2004, Kutzer et al. 2009, Santoro et al. 2010, Santos et al. 2011).

In the present study, infective-stage endoparasites were identified in 32,69% of fecal samples collected from falconry birds. Similar results were reported by Papini et al. (2012) who detected parasites in 35.5% of pet and zoo birds. Most of the identified parasites had a fecal-oral route of transmission. These observations suggest that housing conditions (contaminated bedding, contact with other birds and invertebrates as intermediate hosts), and the quality and origin of the administered feed may play a key role as potential sources of parasitic infections. Birds of prey are generally definitive hosts for parasites. A parasitic infection should be diagnosed by a veterinary clinician, and the administered treatment should specifically target the identified parasite. Effective treatment requires at least a rudimentary knowledge of the main types of parasites infesting predatory birds. The surveyed falconers had a keen interest in their birds' health, and they were aware of the negative effects of endoparasitic infections. Guidelines for controlling and treating parasitic infections should be observed to protect non-infected birds, in particular in large aviaries and breeding centers. Endoparasites adapt to the host to derive long-term benefits, and they

rarely cause pathological changes, anxiety or decreased flight performance (Krone 2000, Lacina and Bird 2000). However, parasitic infections can have serious or even significant health implications in the presence of predisposing factors such as stress (Krone 2000, Lacina and Bird 2000). Birds that are not acclimated to humans, birds in initial stages of training, malnourished birds, birds performing under stressful conditions, and anxious individuals are particularly susceptible to stress.

In the current study, most parasitic infections were caused by nematodes. *Porrocaecum depressum* has been observed in species of birds of prey which can be used for falconry in other studies, including: gyrfalcons (*Falco biarmicus*) and goshawks (*Accipiter gentilis*) (Davydova et al. 2016). Intense infection with *Porrocaecum angusticolle* caused death of a saker falcon (Komorová et al. 2017). In this experiment, *Porrocaecum* sp. eggs were detected in 14 fecal samples (14/52, 27%) from birds from both Falconiformes and Accipitriformes orders, in particular in saker falcons (7 cases, 50% of positive samples). Six of the seven infected birds were asymptomatic. In one female saker falcon, the clinical signs described by the owner were similar to those noted in chickens infected with *Ascaridia galli* (weight loss and problems with achieving the target body weight, ruffled feathers, drooping wings, apathy, hyperactivity) (Dahl et al. 2002). Clinical signs become apparent only at high infestation levels, but they are non-specific and may be disregarded by owners who are not familiar with the birds' behavior or do not regularly monitor the body weight of their birds. Chronic infections can lead to weakness, emaciation, or even death.

These findings support that the quality of food fed to falconry birds should be carefully examined to eliminate potential sources of infection.

Capillaria spp. eggs were the second most frequently detected developmental stages of parasites in the analyzed fecal samples. Adult *Capillaria* are much smaller than *Ascaridia* spp. These parasites may colonize the oral cavity, pharynx, esophagus, crop, small intestine, or cecum, depending on the host species (Papini et al. 2012). *Capillaria* spp. eggs were identified *in vivo* with the use of the flotation method. Adult *Capillaria* were detected post-mortem in the esophagus of a Eurasian sparrowhawk. The post-mortem examination also revealed yellow discoloration of the oral cavity, and similar anatomopathological changes were reported in Italian birds infested with *Eucoelus dispar*. In the cited study, sections of *E. dispar* and their eggs were detected in the mucosa and ectatic and inflamed glands of the tongue and esophagus (Santoro et al. 2010). Yellowish tumor-like lesions in the proximal segment of the gas-

triointestinal tract could be indicative of trichomoniasis, and a detailed examination is required to identify the underlying cause of these changes. According to Sanmartin et al. (2004), a higher prevalence of *E. dispar* in free-living Eurasian sparrowhawks can be attributed to their diet based on invertebrates. To minimize this risk, the birds should have limited access to invertebrates. The aviary floor should be covered with sand or another substrate to prevent birds from coming into direct contact with the ground and invertebrates. Nonetheless, while transmission occurs with ingestion of invertebrates, raptors can also be infected by consuming the digestive tract of prey.

Coccidia were identified in the feces of two birds (2/20 53.4%). Krone et al. (2002) detected coccidia in 31.4% of free-living predatory birds, but none of the identified parasites belonged to the genus *Caryospora*. In contrast, *Caryospora* spp. were detected in 7.5% of hospitalized falcons in the United Arab Emirates (Mateuta et al. 2017). The prevalence of *Caryospora* spp. was also analyzed in a falcon breeding center in the United Arab Emirates, and the study revealed that it increased with the birds' age. Gyrfalcon chicks aged 10 to 60 days tested negative for the parasite, but the prevalence of *Caryospora* spp. reached 71.42% and 95.83% in 67- and 70-day-old birds, respectively (Juárez et al. 2020). The cited authors concluded that *Caryospora* oocysts may be found in the environment and in breeding facilities with poor and substandard hygiene. *Caryospora* oocyst counts were also higher in the sand in breeding chambers than in the environment of free-flying aviaries (Juárez et al. 2020). Krone et al. (2002) posited that infected birds imported into falcon breeding stations may be a source of *Caryospora* spp. and that this parasite has its natural nidus in the distribution range of predatory birds used in falconry. Coccidia are generally genus-specific and falcons cannot get infected with coccidia from quails or pigeons. However, the above observation cannot be unambiguously validated based on the results of the present study. Acute symptoms of coccidiosis, including significant weight loss, general weakness, ruffled feathers, dehydration, diarrhea, and blood in stool (OPG 2300), were observed in a peregrine falcon. In contrast, clinical symptoms were not observed in a Eurasian goshawk (OPG 850).

The results of this study contribute to the existing body of knowledge on endoparasitic infections in falconry birds and they can be used to increase the awareness of falconers to the potential risks of parasitic infection. Monitoring the prevalence of these protozoa in birds of prey and the importance of good feeding management of these captive species should be considered important measures.

References

- Baruš V, Sergejeva TP (1989a) Capillariids parasitic in birds in the Palaearctic region (2). Genera *Eucoleus* and *Echino-coleus*. Acta Scientiarum Naturalium Academiae Scientiarum Bohemoslovacae 23: 1-47.
- Brüll H (1932) A capillaria in pharynx and oesophagus of a peregrine falcon. Deut Tierarztl Wochenschr 40: 293-294.
- Clausen B, Gudmundsson F (1981) Causes of mortality among free-ranging gyrfalcons in Iceland. J Wild Dis 17: 105-109.
- Cooper JE (1969) Oesophageal capillariasis in captive falcons. Vet Rec 84: 634-636.
- Dahl C, Permin A, Christensen JP, Bisgaard M, Muhairwa AP, Petersen KM, Poulsen JS, Jensen AL (2002) The effect of concurrent infections with *Pasteurella multocida* and *Ascaridia galli* on free range chickens. Vet Microbiol 86: 313-24.
- Davydova OE, Vasilevytch FI, Pimenov NV (2016) Clinical-laboratory studies of the birds of prey of the order falconiformes contained in the conditions of kennel. Int J Pharm Res Allied Sci 5: 85-94.
- Dopierala A, Kruk R (2022) Marginalized heritage Brać Łowiecka 2: 51.
- Forbes NA (2008) Raptors: parasitic disease. BSAVA Manual of Raptors, Pigeons and Passerine Birds. British Small Animal Veterinary Association, Gloucester UK, pp 202-211.
- Greve JH (1996a) Gastrointestinal parasites. Rosskopf WJ and Woerpel R (Eds.) Diseases of cage and aviary birds. 3rd ed. Philadelphia. London. Paris. Williams & Wilkins. Baltimore, pp 613-619.
- Gundlach JL, Sadzikowski AB (2004) Parasitology i parasitoses of animals. State Agricultural and Forestry Publishing House, Warsaw, Poland, pp 468.
- Hawks S, Klann R (1997) Helminth Ova Recovered From Raptors Admitted For Rehabilitation, J Iowa Acad Sci 104: 47-49.
- Heidenreich M (1997) Parasitic diseases. Birds of prey, Medicine and management. Blackwell Science, Oxford, Wiley, UK, pp 131-148.
- Juárez A, García YM, Sauza RP, Luna JC, Samour J (2020) Prevalence of *Caryospora* (Apicomplexa: Eimeriidae) Oocysts in the Environment of a Gyrfalcon (*Falco rusticolus*) Breeding Center in the United Arab Emirates. J Avian Med Surg 34:152-157.
- Komorová P, Sitko J, Špakulová M, Hurnikova Z, Sařamatin R, Chovancová G (2017) New data on helminth fauna of birds of prey (Falconiformes, Accipitriformes, Strigiformes) in the Slovak Republic. Helminthologia. 54: 314-321.
- Krone O (2007) Endoparasites-Raptor Research and Management Techniques Manual. Hancock House Publishers, USA, pp 318-328.
- Krone O, Lumeij JT, Remple JD, Redig PT, Lierz M, Cooper JE (2000) Raptor Biomedicine III. Zoological Education Network, Inc., Lake Worth, Florida, pp 101-116.
- Kutzer E, Frey H, Kotremba J (1980) Parasites of Austrian birds of prey (Falconiformes). Angew Parasitol 21:183-205.
- Lacina D, Bird DM, Lumeij JT, Remple JD, Redig PT, Lierz M, Cooper JE (2000) Raptor Biomedicine III, Zoological Education Network, Inc., Lake Worth, Florida, pp 65-99.
- Levine ND (1968) Nematode Parasites of Domestic Animals and of Man. Burgess Publishing Company, Minneapolis, pp 1-600.

- Mawson PM (1956) Ascaroid nematodes from Canadian birds. *Can J Zool* 34: 35-47.
- Mateuta VDS, Samour JH (2017) Prevalence of *Caryospora* Species (Apicomplexa: Eimeriidae) in Falcons in the United Arab Emirates. *J Avian Med Surg* 31: 327-334.
- Ministry of Agriculture, Fisheries and Food (1986) Manual of veterinary parasitological laboratory techniques, reference book. Great Britain. Ministry of Agriculture, Fisheries and Food, London, UK, pp 1-160.
- Mozgovoř, AA (1968). Ascaridata of animals and man and the diseases caused by them: (Askaridaty zhivotnykh i cheloveka i vzyvyaemye imi zabolevaniya). Israel Program for Scientific Translations [available from the U.S. Dept. of Commerce, Clearinghouse for Federal Scientific and Technical Information, Springfield, Va.], Israel, pp 335-389.
- Olsen OW (1974) Animal Parasites. Their Life Cycles and Ecology. University Park Press, Baltimore, pp. 1-562.
- Osche G (1959) On intermediate and accidental hosts, and on the ontogeny of the labial region in species of *Porrocaecum* and *Contraecaecum* (in German). *Zeitsch Parasitenkunde* 19: 458-484.
- Papini R, Girivetto M, Marangi M, Mancianti F, Giangaspero A (2012) Endoparasite infections in pet and zoo birds in Italy. *ScientificWorldJournal* 2012: 253127.
- Sanmartín ML, Alvarez F, Barreiro G, Leiro J (2004) Helminth fauna of Falconiform and Strigiform birds of prey in Galicia, Northwest Spain. *Parasitol Res* 92: 255-263.
- Santana-Sánchez G, Flores-Valle IT, González-Gómez M, Vega-Sánchez V, Salgado-Miranda C, Soriano-Vargas E (2015) *Caryospora neofalconis* and other enteroparasites in raptors from Mexico. *Int J Parasitol Parasites Wildl* 4: 351-355.
- Santoro M, Tripepi M, Kinsella JM, Panebianco A, Mattiucci S (2010) Helminth infestation in birds of prey (Accipitiformes and Falconiformes) in Southern Italy. *Vet J* 186: 119-122.
- Santos T, de Oliveira JB, Vaughan C, Santiago H (2011) Health of an ex situ population of raptors (Falconiformes and Strigiformes) in Mexico: diagnosis of internal parasites. *Rev Biol Trop* 59: 1265-1274.
- Smith SA, Redig PT, Cooper JE, Remple JD, Hunter DB (1993) Diagnosis and treatment of helminths in birds of prey. *Raptor Biomedicine*. University of Minnesota Press, Minneapolis, USA, pp 21-27.
- Tarello W (2008) Efficacy of ivermectin (Ivomec) against intestinal capillariosis in falcons. *Parasite* 15: 171-174.
- Trainer D, Foltz S, Samuel WM (1968) Capillariasis in the Gyrfalcon. *The Condor* 70: 276-277.
- Upton SJ, Sundermann CA (1990) *Caryospora: Biology, Coccidiosis of Man and Domestic Animals*, CRC Press, Boca Raton, pp 187-204.
- Yabsley MJ (2008) Capillarid nematodes. *Parasitic Diseases of Wild Birds*. John Wiley & Sons, Inc, pp 463-497.