

Sequence of procedures used in management of disc displacement without reduction

MAŁGORZATA PIHUT¹, MAŁGORZATA KULESA-MROWIECKA², ADRIAN OLSZEWSKI³,
ANDRZEJ GALA¹

¹ Prosthodontic and Orthodontic Department, Dental Institute, Jagiellonian University Medical College, Kraków, Poland

² Department of Rehabilitation in Internal Diseases, Faculty of Health Sciences, Jagiellonian University Medical College, Kraków, Poland

³ 2KMM CRO, Katowice, Poland

Corresponding author: Andrzej Gala, D.D.S., Ph.D.

Prosthodontic and Orthodontic Department, Dental Institute, Jagiellonian University Medical College
ul. Montelupich 4, 31-155 Kraków, Poland

Phone: +48 12 424 55 55 int. 230; E-mail: andrzej.gala@uj.edu.pl

Abstract: Temporomandibular disorder (TMD), occurring in the form of articular disc displacement without reduction is one of the most serious and common forms of dysfunction.

The aim of this article was to present a complete sequence of procedures and intervention that consequently led to the resolution of symptoms in most patients, associated with disc displacement without reduction and the resolution of joint's pain, as well as favorable results of treatment of disc displacement with reduction.

Material and Methods: A group of 128 patients (86 females, 42 males) aged 20 to 42 years old, diagnosed with disc displacement without reduction undertook treatment at the Prosthodontics Clinic of the University Dental Clinic in Krakow, in period January 2020 — June 2024. Diagnosis of the condition was made on the basis of the DC/TMD (Diagnostic Criteria for Temporomandibular Disorders) questionnaire axis I (reduction in mouth opening <35 mm, oblique lowering path of mandibular motion, pain of the joint) and the results of ultrasonography (USG) of the temporomandibular joints. 121 patients reported experiencing intrinsic pain and 7 patients presented for treatment without feeling pain.

Result: Analysis of the results of the carried-out tests (maximal mouth opening, mandibular lowering trajectory deviation and pain intensity VAS + VNRS scale indicate that the displaced articular disc was unblocked and a statistically significant improvement in the clinical condition of the temporomandibular joints was achieved.

Conclusion: The proposed sequence of procedures carried out is an effective treatment for displacement of the articular disc with no reduction.

Key words: TMD, disc displacement without reduction, physiotherapy, biostimulation laser, occlusal splint, USG of joints.

Submitted: 22-Oct-2024; **Accepted in the final form:** 22-Nov-2024; **Published:** 26-Dec-2024.



Introduction

Temporomandibular disorder (TMD), occurring in the form of articular disc displacement without reduction is one of the more common forms of dysfunction. Patients often seek help too late to treat this form of disorder, leading to the most advanced form, which is accompanied by significant pain. We can say that this form is the worst subgroup of TMD. The clinical signs of this form of dysfunction are a reduction in the range of mandibular motion, a deviation of the mandible's lowering tract and the cessation of acoustic symptoms in the form of clicking. This is often accompanied by pain in the joint where the disc displacement without reduction occurred [1–3]. The patho-mechanism of posterior disc ligament damage is frequently associated with occlusal parafunctions, in the form of teeth clenching or grinding. The parafunctions usually last for many years, before the patient look for treatment, and a preceding form of dysfunction in the form of disc displacement with reduction leads to excessive and uncontrolled compression of the articular head on the overstretched posterior ligament [3–6].

The CD/TMD axis I classification is used in the diagnosis of disc TMD, and the described form of the disorder belongs to group II B. To date, no single, specific algorithm of therapeutic management has been developed [4]. Numerous articles describe various methods used to treat articular disc displacement without reduction, but they are mainly based on personal experience, less on scientific evidence. These include: the use of occlusal splints, active manipulation of the mandible, intraarticular injection of hyaluronic acid or platelet rich plasma, arthrocentesis, physical therapy, physiotherapy treatments, self-therapy, and necessity of changing harmful habits [6–12]. The effectiveness of conservative treatment depends — among other things — on the timing undertaking of the patient's treatment after the onset of jaw restricted range of mandible motion. The disease described by the author can take an acute or chronic form [2, 4, 13–15].

The aim of this article is to present the satisfactory treatment, which is based on contemporary literatures and long, over 30 years of practice with this group of patients. The article presents a complete sequence of procedures and intervention that consequently led to the resolution of symptoms in most patients, associated with disc displacement without reduction and the resolution of joint's pain, as well as favorable results of treatment of disc displacement with reduction.

Bioethics Committee Approval No. 1072.6120.62.2020

Material and Methods

Patient group

A group of 128 patients (86 females, 42 males) aged 20 to 42 years old, diagnosed with disc displacement without reduction undertook treatment at the Prosthodontics Clinic of the University Dental Clinic in Krakow in period January 2020 — June 2024. Diagnosis of the condition was made on the basis of the DC/TMD (Diagnostic Criteria for Temporomandibular Disorders) questionnaire axis I (reduction in mouth opening <35 mm, oblique lowering path of mandibular motion, pain of the joint) [4] and the results of ultrasonography (USG) of the temporomandibular joints. 121 patients reported experiencing intrinsic pain and 7 patients presented for treatment without feeling pain.

The inclusion criteria were: consent to participate in the study, age 20–40 years, both sex, good general health, symptoms of disc displacement without reduction, a previous history of clicking,

non-use drug consumption for 4 weeks before application of treatment. The exclusion criteria were: willingness to give up of treatment, progression of the condition to a more advanced state, the occurrence of a general condition affecting the disorders being treated.

A complex lecture was given to all subjects in the first stage of treatment to raise awareness of: the etiological factors of TMD and the harmfulness of occlusal parafunctions, the necessary mental control of the position of the mandible in which it is located, the necessity of disocclusion lodging one's own teeth, throughout the day, and the need for the patient to engage in self-therapy (systematically performing a series of exercises, supplements with glucosamine and chondroitin).

A sample size calculation was performed (in G-Power v. 3.1.9.7 and R 4.4.2 software) for the main outcome measures in order to obtain a power of 0.80 and estimated effect size at least 0.25 value for the opening endpoint. The significance level was set to 0.05 value under the fixed-sequence approach to testing the three planned hypotheses.

Methods of the study

All subjects were tested according to the DC/RDC questionnaire prior to treatment. Patients with a diagnosis of II B were eligible for the study. For further analysis, data indicating disc displacement without reduction, maximum unassisted mouth opening (MMO) — measured between the edges of the upper and lower central incisors, degree of mandibular deviation, maximum lateral movements the mandible and the, were relevant. The intensity of joint's pain was measured using connected scale VAS + VNRS (Visual Analogue Scale and Verbal Numerical Rating Scale). All the measurement were performed by one researcher. The clinical diagnosis (displacement of the articular disc without reduction) was confirmed by examination of the soft-tissue structures of the joints using ultrasonography. Clinical study were performed twice i.e. at the beginning of the treatment (I examination) and five months later (II examination).

They included measuring: the maximum mouth opening, the extent of mandibular deviation during maximal opening, assessing the intensity of joint pain in which there was disc displacement without reduction and USG examination of the temporo-mandibular joints. All measurement were performed by one researcher [2, 8, 9].

Patients were treated in the first stage of procedure with attempt of active unblocking of the articular disc — 112 patients (71 female and 41 male), using special manipulation of the doctor, followed by the application of splints — repositioning if the protrusive test was positive or relaxation if the test was negative. In all subjects, hyaluronic acid was injected intra-articularly into the upper extremity of the joints 4 times, at 2-week intervals.

Physiotherapeutic treatments were applied in the form of a low-power biostimulating laser and sonophoresis treatments for the joint area and masticatory muscles with an analgesic gel. A positive protrusive test shows the correct anterior therapeutic position of the active manipulation was carried out very gently, following the procedure described by mandible, at which acoustic symptoms in the form of clicking occurring in the temporomandibular joints disappear [2]. Immediately after unblocking the pathologically displaced disc, alginate impressions were taken for the fabrication and application of acrylic anterior positioning appliances. After unlocking the articular disc, acoustic symptoms in the temporomandibular joints were again present.

In the group of the 16 patients in whom active unblocking of the disc failed (15 female and 1 male), immediate splints were used, made (from silicone impression compound) in the therapeutic position of the mandible, for the time required to unblock the disc. Usually it was 2 to 4

weeks. After obtaining a favorable effect in the form of normalization of the normal alignment of the mandibular articular head disc complex (usually about 3 weeks), the splints were made of hard acrylic material. The splint therapy was used to reduce the excessive loading on the joints, lowering the high tensions of the masticatory muscles, and for support the adaptation of articular elements and regenerative processes within the temporomandibular joints.

It was recommended that all patients using occlusal splints should use the devices 20 hours a day and after a period of first 4 weeks, steadily reduce the duration of splint use. Follow-up visits were made every 4 weeks, and the results that were taken into account to evaluate the applied treatment were analyzed in the first examination and the examination performed after 5 months.

Statistical analysis

Statistical analyses were performed using SPSS Statistics for Data Analysis v.29 and R v.4.4.2 (packages such as MKinfer, Tidyverse, statspsych were used). The Shapiro–Wilk normality test was applied to check whether data were normally distributed. Mean, median, standard deviation, and other descriptive statistics were calculated. Since data were not normally distributed, a non-parametric test, the Wilcoxon test (Wilcoxon signed-rank test), was used to compare the difference in data values between two dependent groups (Examination_1 and Examination_2) (Fig. 1).

Additionally the results of the above-mentioned test were compared with permutation paired t-test results (as in that case assumptions of normality can be relaxed). The differences were taken as significant when the p-value was less than 0.05. All analyses utilized a significance level of $p < 0.05$ and the type-1 error rate was controlled for the three outcomes at the study level through the fixed-sequence method. A 1-out-of-20 rate of the type-1 error (false rejection) was deemed acceptable and aligned with established practices in this domain. All three ordered hypotheses were rejected, therefore no adjustment for significance level was necessary, in line the fixed-sequence principle.

Statistically significant differences were found between the first and second examinations in terms of Maximal Mouth Opening, VAS pain scores and Lateral deviation measurements [16]. According to statistical analyses performed, it is worth mentioning that the procedures undertaken were two directional.

Permutation t-test was proposed as a remedy due to rejected normality of differences by the Shapiro–Wilk test. Alternatively, Wilcoxon signed rank test was employed for validation of the results.

It turned out, despite formally violated assumption of normally distributed differences (confirmed by visual assessment), both permutation and ordinary paired t-test showed perfectly consistent results, in a close agreement with the Wilcoxon test (Fig. 2). As a conclusion, the observed deviation from theoretical normality did not affect the testing process essentially rendering all results consistent.

Risk of bias assessment

Analysis of the study material indicates that the risk of bias may be the sincerity of patients to follow the therapeutic recommendations for self-therapy (relaxation exercises performed independently by the patient, use of physiotherapy treatments, hot packs).

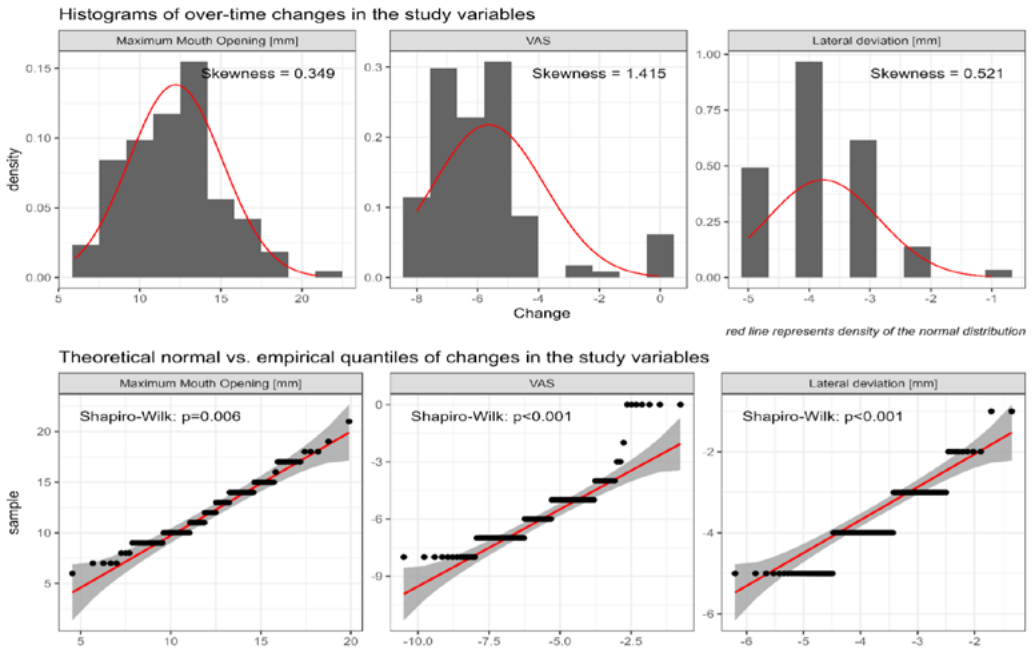


Fig. 1. Histograms and QQ plots for Maximum Mouth Opening, VAS pain intensity and Lateral deviation variables.

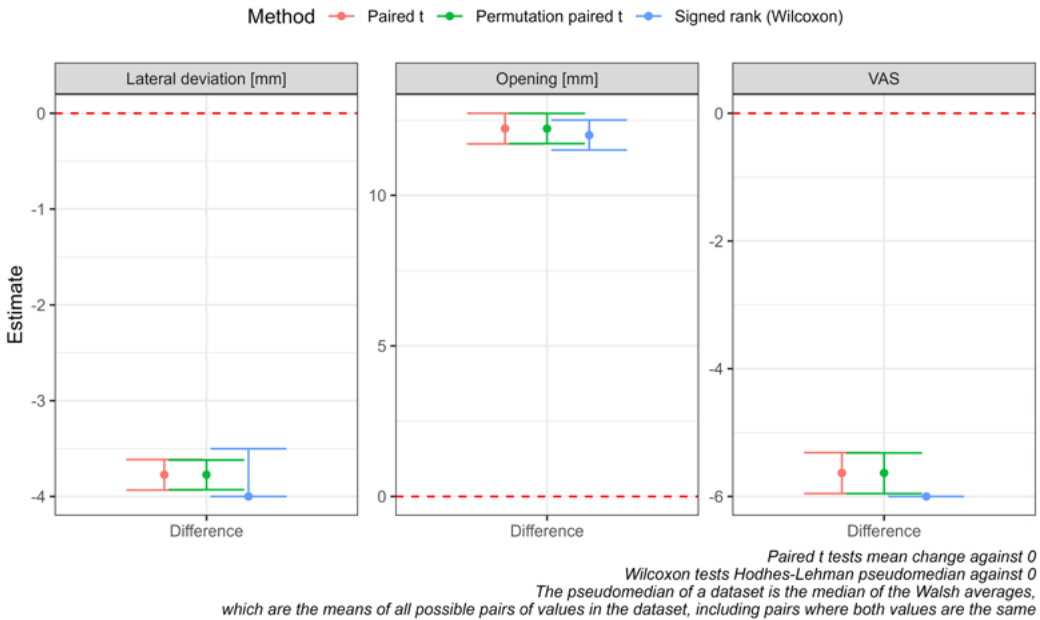


Fig. 2. Comparison of three inferential methods for paired samples.

Results

All subjects underwent DC/TMD, axis I, which confirmed a diagnosis of II B, so it was disc displacement without reduction.

Analyzing the data, obtained from the measurements of the maximum mouth opening, the mean value of the I examination was 31.56 mm, the standard deviation was 1.81, the median was 32, and the minimum and maximum values of the opening were 27–35. These measurements confirmed the pathological state of articular disc displacement without reduction.

In the II examination the mean value was 43.78 mm, the standard deviation was 2.26, median was 43.5 and minimum and maximum values were 41–51 mm. The values obtained in the Second examination (control test) indicate a significant improvement in the evaluated parameters, that is, the minimum physiological mouth opening is 40 mm, so the average values of this measurement have improved significantly, and the minimum values, i.e. 41 mm, indicate the achievement of a physiological range of this movement in all subjects. It is very important that the results obtained in the two examinations differ in a statistically significantly, because p-value is <0.001. The above results are shown in Table 1.

Table 1. The mean values of maximum mouth opening and statistical parameters.

Maximum mouth opening N = 128 patients					
	$\bar{X} \pm SD$	median	min-max	$\bar{X}_{DIFF} \pm SD$	level of significance ($\alpha = 0.05$) and p-value*
I examination	31.56 ± 1.81	32	27–35	12.2 ± 2.90	Wilcoxon <0.001 Perm. t test <0.001
II examination	43.78 ± 2.26	43.5	41–51		
* Wilcoxon (signed rank test) and Permutation t-test for paired samples					

An important parameter depicting the status of the lesions was the evaluation of the intensity of pain in the temporomandibular joints. In the first clinical examination, mean VAS + VNRS scores of 6.05 points were obtained, with a standard deviation of 1.90, a median of 6 and minimum and maximum values of 0–9. In the follow-up examination (II), a significant improvement was obtained, as the mean pain intensity score was 0.42, with a standard deviation of 0.74, a median of 0 and maximum values of 3 points. Also, the above study results differed in a statistically significantly, because p-value was <0.001. Pain relief is one of the basic principles of medical treatment. The above results are shown in Table 2.

Table 2. The mean value and SD of intensity of joint's pain, according to VAS + VNRS scale and statistical parameters.

VAS and VNRS N = 128 patients					
	$\bar{X} \pm SD$	median	min-max	$\bar{X}_{DIFF} \pm SD$	level of significance ($\alpha = 0.05$) and p-value*
I examination	6.05 ± 1.90	6	0–9	-5.63 ± 1.84	Wilcoxon <0.001 Perm. t test <0.001
II examination	0.42 ± 0.74	0	0–3		
* Wilcoxon (signed rank test) and Permutation t-test for paired samples					

Evaluation of the parameter of mandibular deviation during maximal opening mouth is an important parameter indicating temporomandibular joint disorders. In the first study, the mean deviation values of this movement were 3.98 mm, with a standard deviation of 0.85, a median of 4 mm, minimum and maximum values of 2–6 mm. In the second study, the results, respectively, were; mean value 0.21 mm, standard deviation 0.48, minimum and maximum values 0–2. The results of the first and second study were statistically significantly different, as the p-value was <0.001. The above results are shown in Table 3. Additionally the results of individual changes over time for Maximum Mouth Opening, VAS pain intensity and Lateral deviation variables are presented in (Fig. 3).

Table 3. The mean values of lateral deviation of mandible and statistical parameters.

Lateral deviation of mandible N = 128 patients					
	$\bar{X} \pm SD$	median	min-max	$\bar{X}_{DIFF} \pm SD$	level of significance ($\alpha = 0.05$) and p-value*
I examination	3.98 ± 0.85	4	2–6	-3.77 ± 0.92	Wilcoxon <0.001 Perm. t test <0.001
II examination	0.21 ± 0.48	0	0–2		

* Wilcoxon (signed rank test) and Permutation t-test for paired samples

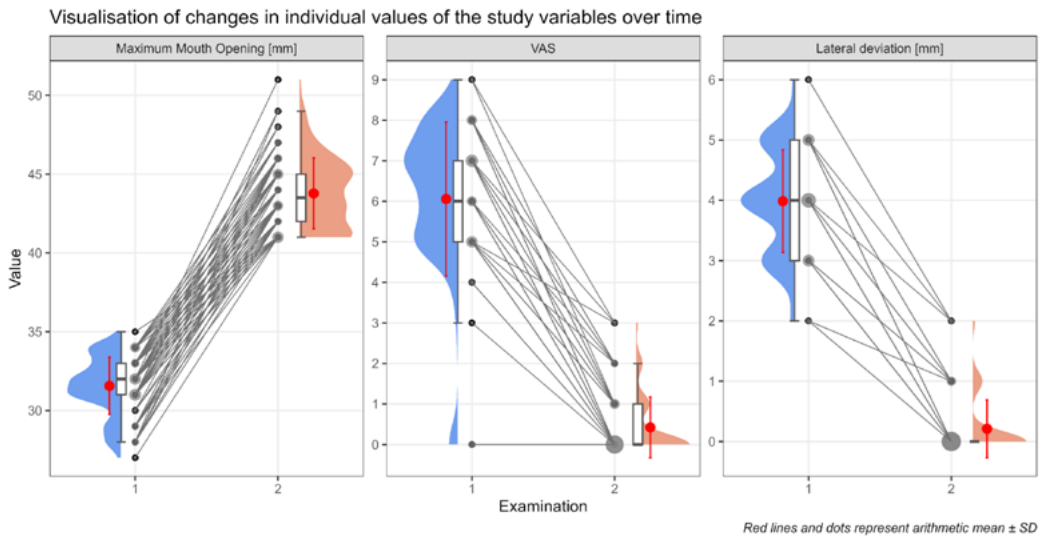


Fig. 3. Individual changes in Maximum Mouth Opening, VAS (pain intensity) and Lateral Deviation over time.

The clinical results indicated that full unblocking of the articular disc in the temporomandibular joints was finally achieved (N = 128 patients), as parameters indicative of a pathological condition corrected to physiological values. Only 12 patient showed unstable, sporadic acoustic symptoms after a period of 5 months.

The only difference was the time to achieve full improvement, as patients who failed to unlock the disc during active manipulation needed more time to achieve the same results. Both conservative methods used brought measurable therapeutic benefits that ultimately restored the physiological state of the masticatory organ.

Discussion

Displacement of the articular disc without reduction is the most advanced disorder among TMDs. It occurs in people of all ages, with a high prevalence in women aged 20 to 40 years. It is often a significant problem for patients and this dysfunction takes the form of pain [17–22]. If the disc is displaced without reduction, there is permanent damage to the posterior ligament of the articular disc, and this accounts for the fact that the disc remains in the anterior position when lowering the mandible. Such a condition often leads to a long-term disruption of the normal coordination of the disc and joint head, which manifests itself as a restriction of maximum mouth opening and chewing of food, which is usually accompanied by pain [10, 13, 17]. Many authors describe different methods of conservative treatment, and so far no clear-cut algorithm has been established, recommended for this management [2, 5, 7, 12, 14, 20, 21].

The results of the follow-up examinations indicate the full effectiveness of the described treatment, and the attempt to actively unblock the disc is an important part of the clinical management of the restoration of normal disc-articular head relations. Al-Baghdadi *et al.* [5] underline in their study that active unblocking has beneficial effects, and the evaluated parameters are significantly improved within 10 minutes in 84% of the subjects. Also, the cited authors point to the extremely beneficial performance of self-exercise by patients. This opinion is fully in line with the results of our research and defines the effectiveness of the interventions undertaken at a high level.

A major problem in the treatment of disc displacement without reduction is the very late reporting of patients to the doctor due to the limitation of the maximum mouth opening [1, 5, 10, 23, 27]. This fact makes it very difficult to achieve effective treatment. In addition, it should be noted that usually the condition preceding the described dysfunction is disc displacement with reduction, and this is the condition at which specialized treatment should be initiated. Several authors promote the opinion that displacement of the disc with reduction is a condition that does not require treatment and medical intervention [9, 10, 19, 23–26]. In the opinion of the authors of this article, it is difficult to agree with this these.

It should be noted that many authors emphasize the very important importance of physiotherapy treatments, as an adjunctive treatment. The patho-mechanism of damage to the posterior disc ligament indicates the benefits of biostimulation laser, manual therapy, sonophoresis [2, 7, 20, 22, 27–31].

Conclusions

In conclusion, it should be said that the proposed sequence of treatments and treatment steps for non-reduced articular disc displacement yielded favorable treatment results, as the restoration of normal articular disc position and resolution of temporomandibular joint pain were achieved after 5 months.

References

1. Ferreira C., Silva M., Felicio C.: Signs and symptoms of temporomandibular disorders in women and men. CoDAS [online]. 2016; 28 (1) [cited 2020-01-02]: 17–21. <http://dx.doi.org/10.1590/2317-1782/20162014218>.
2. Wright E., Klasser G.: Manual of temporomandibular disorders. Wiley Blackwell 2020. Fourth edition.

3. Wieckiewicz M., Grychowska N., Wojciechowski K., et al.: Prevalence and correlation between TMD based on RDC/TMD diagnoses, oral parafunctions and psychoemotional stress in Polish university students. *BioMed Res Int.* 2014; 472346. doi: 10.1155/2014/472346.
4. Schiffman E., Ohrbach R., Truelove E., et al.: Diagnostic Criteria for Temporomandibular Disorders (DC/TMD) for Clinical and Research Applications: recommendations of the International RDC/TMD Consortium Network* and Orofacial Pain Special Interest Group. *J Oral Facial Pain Headache.* 2014; 28 (1): 6–27. doi: 10.11607/jop.1151.
5. Al-Baghdadi M., Durham J., Araujo-Soares V., et al.: TMJ disc displacement without reduction management: a systematic review. *J Dent Res.* 2014; 93 (7 Suppl): 37S–51S. doi: 10.1177/0022034514528333.
6. Miernik A., Więckiewicz W.: The Basic Conservative Treatment of Temporomandibular Joint Anterior Disc Displacement Without Reduction — Review. *Adv Clin Exp Med.* 2015 Jul–Aug; 24 (4): 731–735. doi: 10.17219/acem/35165.
7. Tatli U., Benlidayi M., Ekren O., Salimov F.: Comparison of the effectiveness of three different treatment methods for temporomandibular joint disc displacement without reduction. *Int J Oral Maxillofac Surg.* 2017; 46 (5): 603–609. doi: 10.1016/j.ijom.2017.01.018.
8. Minakuchi H., Kuboki T., Matsuka Y., et al.: Randomized controlled evaluation of non-surgical treatments for temporomandibular joint anterior disk displacement without reduction. *J Dent Res.* 2001; 80 (3): 924–928. doi: 10.1177/00220345010800031501.
9. Koh K., Ha-Na P., Kyoung A.-K.: Relationship between anterior disc displacement with/without reduction and effusion in temporomandibular disorder patients using magnetic resonance imaging. *Imaging Sci Dent.* 2013; 43 (4): 245–251. doi: 10.5624/isd.2013.43.4.245.
10. Lin S.-L., Wu S.-L., Ko S.Y., et al.: Effect of flat-plane splint vertical thickness on disc displacement without reduction: a retrospective matched-cohort study. *J Oral Maxillofac Surg.* 2017; 75 (8): 1627–1636. doi: 10.1016/j.joms.2016.12.047.
11. Emshoff R., Brandlmaier I., Bertram S., Rudisch A.: Comparing methods for diagnosing temporomandibular joint disk displacement without reduction. *J Am Dent Assoc.* 2002; 133 (4): 442–451. doi: 10.14219/jada.archive.2002.0202.
12. La Touche R., Boo-Mallo T., Zarzosa-Rodríguez J., et al.: Manual therapy and exercise in temporomandibular joint disc displacement without reduction. A systematic review. *Cranio.* 2022; 40 (5): 440–450. doi: 10.1080/08869634.2020.1776529.
13. Al-Baghdadi M., Green R., Durham J., et al.: Decision-making in the management of TMJ disc displacement without reduction: A qualitative study. *J Dent.* 2019; 91: 103223. doi: 10.1016/j.jdent.2019.103223.
14. Kraus S., Prodoehl J.: Disc displacement without reduction with limited opening: A clinical diagnostic accuracy study. *Physiother Theory Pract.* 2017; 33 (3): 238–244. doi: 10.1080/09593985.2017.1288282.
15. Pihut M., Gorecka M., Ceranowicz P., Wieckiewicz M.: The efficiency of anterior repositioning splints in the management of pain related to temporomandibular joint disc displacement with reduction. *Pain Res Manag.* 2018 Feb 21; 2018: 9089286. doi: 10.1155/2018/9089286.
16. D'Elia A.: A statistical modelling approach for the analysis of TMD chronic pain data. *Stat Methods Med Res.* 2008; 17 (4): 389–403. doi: 10.1177/0962280206071846.
17. Alajbeg Z., Gikić M., Valentić-Peruzović M.: Mandibular range of movement and pain intensity in patients with anterior disc displacement without reduction. *Acta Stomatol Croat.* 2015; 49 (2): 119. doi: 10.15644/asc49/2/5.
18. He D., Yang X., Wang F., et al.: Acute trauma induced disc displacement without reduction and its sequelae. *Sci Rep.* 2016; 6: 32684. doi: 10.1038/srep32684.
19. Giraudeau A., Jeanny M., Ehrmann E., et al.: Disc displacement without reduction: a retrospective study of a clinical diagnostic sign. *CRANIO.* 2017; 35 (2): 86–93. doi: 10.1080/08869634.2016.1149291.
20. Lei J., Yap A.U., Li Y., et al.: Clinical protocol for managing acute disc displacement without reduction: a magnetic resonance imaging evaluation. *Int J Oral Maxillofac Surg.* 2020; 49 (3): 361–368. doi: 10.1016/j.ijom.2019.07.005.

21. *Diraçoğlu D., Saral I.B., Keklik B., et al.*: Arthrocentesis versus nonsurgical methods in the treatment of temporomandibular disc displacement without reduction. *Oral Surg Oral Med Oral Pathol Oral Radiol Endod.* 2009; 108 (1): 3–8. doi: 10.1016/j.tripleo.2009.01.005.
22. *Zhang Y., Zhang J., Wang L., et al.*: Effect of transcutaneous electrical nerve stimulation on jaw movement-evoked pain in patients with TMJ disc displacement without reduction and healthy controls. *Acta Odontol Scand.* 2020; 78 (4): 309–320. doi: 10.1080/00016357.2019.1707868.
23. *Fang Z., Yao Y., Fan S., et al.*: Physical therapy and non-surgical manual disc reduction combined with anterior repositioning splint for acute disc displacement without reduction of the temporomandibular joint in adolescents. *Clin Oral Investig.* 2024; 28 (10): 517. doi: 10.1007/s00784-024-05910-0.
24. *Lalue-Sanches M., Gonzaga A.R., Guimaraes A.S., Ribeiro E.C.*: Disc displacement with reduction of the temporomandibular joint: the real need for treatment. *J Pain Relief.* 2015; 4 (5): 2–5. doi: 10.4172/2167-0846.1000200.
25. *Iwase H., Sasaki T., Asakura S., et al.*: Characterization of patients with disc displacement without reduction unresponsive to nonsurgical treatment: a preliminary study. *J Oral Maxillofac Surg.* 2005; 63 (8): 1115–1122. doi: 10.1016/j.joms.2005.04.005.
26. *Manfredini D.*: No significant differences between conservative interventions and surgical interventions for TMJ disc displacement without reduction. *Evid Based Dent.* 2014; 15 (3): 90–91. doi: 10.1038/sj.ebd.6401049.
27. *Lei J., Han J., Liu M., et al.*: Degenerative temporomandibular joint changes associated with recent-onset disc displacement without reduction in adolescents and young adults. *J Craniomaxillofac Surg.* 2017; 45 (3): 408–413. doi: 10.1016/j.jcms.2016.12.017.
28. *Pihut M., Pac A., Gala A.*: Frequency of occurrence of the pain form of the temporomandibular disorders and gender distribution. *Folia Med Cracov.* 2021; 61 (2): 25–33.
29. *Pihut M., Gala A.*: The application of intra-articular injections for management of the consequences of disc displacement without reduction. *Int J Environ Res Public Health.* 2020; 17 (13): 4726. doi: 10.3390/ijerph17134726.
30. *Li J., Zhang Z., Han N.*: Diverse therapies for disc displacement of temporomandibular joint: a systematic review and network meta-analysis. *Br J Oral Maxillofac Surg.* 2022; 60 (8): 1012–1022. doi: 10.1016/j.bjoms.2022.04.004.
31. *Fujiwara M., Honda K., Hasegawa Y., et al.*: Comparison of joint pain in patients diagnosed with and without articular disc displacement without reduction based on the Research Diagnostic Criteria for Temporomandibular Disorders. *Oral Surg Oral Med Oral Pathol Oral Radiol.* 2013; 116 (1): 9–15. doi: 10.1016/j.oooo.2012.11.012.