

ABAMECTIN INDUCED BIOCHEMICAL AND HISTOPATHOLOGICAL CHANGES IN THE ALBINO RAT, *RATTUS NORVEGICUS*

Hany Kamal Abd-Elhady*, Gamal Elsayed Abou-Elghar

Department of Pesticides, Faculty of Agriculture, Menoufiya University, 32511, Shebin-Elkom, Egypt

Received: October 22, 2012

Accepted: July 24, 2013

Abstract: Abamectin (Avermectin B1a), is a natural fermentation product derived from the soil bacterium *Streptomyces avermitilis*. Abamectin (Avermectin B1a) is widely used as an insecticide, acaricide, and anthelmintic. The present study assessed the effects of repeated subacute and subchronic exposure to the commercial formulation of abamectin (Vertemic, 1.8% EC) in albino male rats. The toxic effects of abamectin were studied. The various biochemical parameters and histopathological changes were noted. A stomach tube was used to orally administer sublethal doses of abamectin suspended in corn oil to the rats. The animals were divided into four groups. Rats of the group T1 were orally administered a sublethal dose of 30 mg/kg body weight (b.wt.) (1/10 LD₅₀) three times a week for 30 days and the animals in group T2 were exposed to 10 mg/kg b.wt. (1/30 LD₅₀) for 210 days, once a week. Two control groups (C1 and C2) were used in parallel studies, where animals were administered a corn oil vehicle. At the end of the study period, blood samples were collected from all groups to measure plasma alanine aminotransferase (ALT), aspartate aminotransferase (AST) activities, and the levels of creatinine and urea. Also, total protein and RNA contents were determined in the liver and kidney tissues. Changes in biochemical parameters were more intense in male rats from group T2 than those reported in group T1. The levels of ALT, AST, urea and creatinine were significantly elevated in rats from group T2 when compared to the control. In group T2, a significant decrease in the levels of total protein and RNA in both the liver and kidneys was observed. Fertility was also significantly reduced in male rats ingesting abamectin in group T2. The number of offspring was significantly reduced. Histopathological changes were more intense in male rats from group T2 than those from group T1. In conclusion, the results of this study demonstrate that subchronic oral administration of abamectin altered some biochemical parameters which correlated with histopathological changes.

Key words: abamectin, albino rat, biochemical parameters, histopathology, subacute and subchronic toxicity

INTRODUCTION

Abamectin (ABA) belongs to the family of avermectins, which are the macrocyclic lactones produced by a soil actinomycete, *Streptomyces avermitilis* (Fisher and Mrozik 1989; Burg and Stapley 1989). Abamectin (avermectin B₁) is a mixture of two components, with the major component avermectin B_{1a}³ 80% of the mixture, and the minor component avermectin B_{1b}, £ 20% of the mixture, differing by a single methylene group. Abamectin is currently used in several countries as a pest control agent in livestock and as an active substance of nematicides and insecticides for agricultural use (Kolar *et al.* 2008). This product is a potent insecticide and may be highly toxic to mammals (Lankas and Gordon 1989). There are problems associated with chemical insecticides, such as health hazards (Abd-Elhady 2012). Abamectin should be carefully used in Integrated Pest Management (IPM) programs (Abd-Elhady and Heikal 2011). Seixas *et al.* (2006) reported that ABA poisoning caused the death of 57 calves over 4 years. The poisoning was caused by an incorrect dosage given to the animals. The authors noted that the number of deaths might be an underestimation because signs of intoxication vary in intensity and many animals recover quickly. Despite use

restricted to animals and crops, several cases of accidental or intentional abamectin poisoning in humans have been described (Chung *et al.* 1999; Yang 2008). The avermectins block electrical activity in nerve and muscle preparations by increasing the membrane conductance to ions of chloride (Clark *et al.* 1995). The target for abamectin involves the g-aminobutyric acid (GABA) receptor in the peripheral nervous system. It appears that the glutamate-gated chloride channel (GluCl), along with the g-aminobutyric acid (GABA)-gated chloride channel (GABR) and the histamine-gated chloride channel (HisCl), is a target site of avermectin and ivermectin in insects and nematodes (McCavera *et al.* 2007).

Intoxication of abamectin may affect the function of hepatocytes although permanent liver damage is not usually revealed immediately (Hsu *et al.* 2001). Previous study has shown that abamectin was able to elevate levels of the serum enzyme aspartate aminotransferase (AST) (Lowenstein *et al.* 1996). Research conducted by Hsu *et al.* (2001) showed elevated levels of the enzyme AST in the blood serum of rats after exposure to ABA by gavage. Gavage was done at doses between 1 and 20 mg/kg body weight. The maximum activity was obtained with a dose

*Corresponding address:
hkamalkamal@yahoo.com

of 20 mg/kg of body weight, 1 h after ingestion. The *in vitro* toxic action of abamectin, at concentrations of 10 and 100 mM, on isolated rat hepatocytes, was studied by El-Shenawy (2010). A significant increase was reported in alanine aminotransferase (ALT) and AST activities when hepatocytes were incubated for 30 min with either concentration of ABA. This activity persisted after 120 min; the longest time point for which data was collected.

Despite the large amounts of research on the various toxic effects of avermectins, there is a shortage of studies on repeated oral exposure of abamectin at subacute and/or subchronic doses. Hence, the present investigation was undertaken to assess the changes in some histological and biochemical indices of albino rat males who had been given abamectin. Doses were repeated for periods of 30 and 210 days.

MATERIALS AND METHODS

Chemical

The present study was designed as a oral toxicity study. Doses were repeated for periods of 30 and 210 days. The commercial formulation of abamectin (Vertemic[®], 1.8% EC) was supplied by Syngenta Agro Services AG, Egypt. Two sublethal doses of abamectin, equal to 1/10 and 1/30 LD₅₀ were orally administered in this study through repeated-dose tests. The oral LD₅₀ for the 1.8% w/v abamectin EC product in rats is 300 mg/kg (Dow AgroSciences Ltd. 1998).

Animals and treatments

Adult male albino rats (*Rattus norvegicus*), aged 8–10 weeks, with body weights of 145–200 g, were obtained from the Research Institute of Ophthalmology, Giza, Egypt. The animals were housed in small groups (5–6 each), inside propylene cages. The temperature in the experimental animal room was maintained at 25±2°C with 12 h dark: light cycle, and 70±10% humidity. The animals were provided with commercial pelleted rodent food and drinking water *ad libitum*. The animals were allowed to acclimatize to the laboratory conditions for one week prior to the start of the study. The experimental animals were divided into four groups of six adult males each. Animals of group-T1 were administered with abamectin at a dose of 30 mg/kg b.wt (1/10 LD₅₀), three times a week, for a period of 30 days. Rats in group-T2 were administered with abamectin at dose of 10 mg/kg body weight (b.wt.) (1/30 LD₅₀) once a week, for a period of 210 days. A stomach tube was used to administer abamectin (5 ml/kg b.wt) suspended in a corn oil vehicle. Two control groups were used for parallel studies: groups-C1 and C2 received only the corn oil vehicle three times a week for 30 days, and once a week for 210 days, respectively.

Fertility test

Fertility was estimated in both groups which had been administered abamectin at the selected sublethal doses for 30 and 210 days, respectively. Fertility was then, compared to the control treatments. At the end of each exposure period, four males from each treated group

were placed individually in a cage with two virgin untreated females. Similarly, males from the control groups which had received only the corn oil vehicle were mated with untreated females. The animals were left together for 10 days during which two estrus cycles should have elapsed (Elbetieha and Da'as 2003). The adult male rats that ingested abamectin and the control males were then removed. The females were maintained until giving birth. The mean numbers and body weights of the offspring were recorded for each group.

Biochemical estimations

The animals from all groups were sacrificed 48 h after the end of the experimental periods (30 and 210 days). The neck vessels were aseptically severed while the rats were under ether anesthesia. Blood was collected in heparinized test tubes from the served neck vessels of each animal. The blood was, then centrifuged at 3,000 rpm for 20 min. to obtain plasma. Plasma samples were used to estimate the activities of alanine aminotransferase (ALT) and aspartate aminotransferase (AST) (Retiman and Frankel 1957), and to estimate the levels of albumin (ALB) (Doumas *et al.* 1971), urea (Fawcett and Scott 1960) and creatinine (Houto 1985). Standard kits purchased from Sigma Supplies Co. and Alkan Medical Ltd., Cairo, Egypt, were used. Protein (Burtis and Bruns 2007) and RNA (Schneider 1957) levels were determined in tissues of the liver and kidneys from both the treated and the control groups.

Histological studies

Suitable pieces of liver, kidney, lung, and testes were removed, washed in saline, and fixed in Bouin's fluid for histopathological examinations. The Bouin fixed tissues were processed by the paraffin wax embedding method of tissue sectioning, as per method described by Culling (1974). A rotatory microtome was used to cut serial sections to a thickness of 4–5 microns. The sections were stained with Hematoxylin and Eosin (H & E) stains (Luna 1968). The H & E stained slides were observed under the microscope, and lesions were recorded.

Statistical analysis

Data obtained from the experiments were expressed as mean ±SEM. Significant differences of measurement traits were analysed using one-way analysis of variance (ANOVA) with Dunnett's post test using Co-Stat version 6.311 for Windows, (CoStat Program 2006), Berkeley, CA, USA. A p value < 0.05 was considered statistically significant.

RESULTS

Biochemical assessments

The effects of abamectin on certain blood biochemical parameters are summarized in table 1. Male rats of both treated groups, T1 and T2, exhibited a significant increase in the activity of ALT; by 68.3 and 87.9%, respectively, over those values obtained from the control groups. Subchronic poisoning with abamectin (group – T2), also

resulted in a significant increase in the levels of plasma AST, urea, and creatinine by 58.7, 90.8 and 273.9%, respectively, compared to the values obtained from the control group. However, the subacute treatment with abamectin (group – T1) did not result in a significant change in the levels of AST, urea, and creatinine when compared to the control group. Data also show a significant decrease in the level of plasma albumin observed in the rats of group I, whereas, subchronic treatment (group – T2) did not result in a significant change in albumin level compared to the control.

Data in table 2 show the effects of abamectin on total protein and RNA contents in both liver and kidney tissues from male rats of abamectin-treated groups compared to the control groups. Total protein content in liver was significantly decreased ($p < 0.05$) in male rats of both groups – T1 and T2, by 16.4 and 68.9%, compared to the value obtained from the control animals. Similarly, a significant decrease in protein content was found in the

kidneys of male rats from the groups T1 and T2, by 43.1 and 72.7%, respectively, when compared to the control groups. Moreover, the RNA level in liver of male rats of group T2 was significantly decreased ($p < 0.05$) from the control by 46.2%, while no significant change was found in rats of group T1. Also, RNA levels in the kidneys of male rats from both groups T1 and T2, were significantly decreased ($p < 0.05$) from that obtained from the control animals by 63.6 and 67.2%, respectively.

Adverse effect on fertility

The data depicted in table 3 demonstrate the adverse effects of abamectin on male fertility. Mean numbers of offspring were significantly reduced ($p < 0.05$) in both groups T1 and T2 by 33.9 and 68.3%, respectively. The reduction in offspring was due to repeated dosing with abamectin. Moreover, mean weight of offspring was significantly decreased in group T2 compared to that of the control. There was, no significant change in weight of group T1.

Table 1. Effects of abamectin on certain biochemical parameters in the blood plasma of male rats after repeated doses of 30- and 210-day oral treatment with 1/10 and 1/30 LD₅₀ of abamectin, respectively, compared to the control treatments

Parameters	Group-T1 (30-day repeated dose)		Group-T2 (210-day repeated dose)	
	control-C1	abamectin	control-C2	abamectin
ALT [IU/l]	27.76±1.13 c	46.72±2.53 b	28.26±1.63 c	53.11±2.17 a
AST [IU/l]	55.24±1.63 c	62.60±1.49 bc	56.34±1.22 c	89.39±2.65 a
Urea [mg/dl]	39.53±0.96 b	36.59±1.36 b	40.12±0.84 b	76.53±0.98 a
Creatinine [mg/dl]	0.024±0.008 b	0.029±0.010 b	0.023±0.009 b	0.086±0.024 a
Albumin [g/dl]	5.84±0.13 a	4.61±0.19 b	5.92±0.24 a	5.14±0.23 a

Values are means ±SEM. Means followed by the same letter(s) within each horizontal row are not significantly different at $p < 0.05$; ALT – alanine aminotransferase; AST – aspartate aminotransferase

Table 2. Effects of abamectin on total protein and RNA levels in the blood plasma of male rats after repeated doses of 30- and 210-day oral treatment with 1/10 and 1/30 LD₅₀ of abamectin, respectively, compared to the control treatments

Parameters [µg /mg wet weight of tissue]	Tissue	Group-T1 (30-day repeated dose)		Group-T2 (210-day repeated dose)	
		control-C1	abamectin	control-C2	abamectin
Total protein	liver	123.18±5.18 a	102.92±4.88 b	126.28±6.22 a	39.27±9.53 c
	kidney	146.29±8.29 a	83.21±6.23 b	151.27±6.24 a	41.29±9.78 c
RNA	liver	4.61±0.29 a	4.46±0.38 a	4.59±0.33 a	2.47±0.60 b
	kidney	10.62±0.36 a	3.87±0.72 b	10.64±0.32 a	3.49±0.28 b

Values are means ±SEM. Means followed by the same letter(s) within each horizontal row are not significantly different at $p < 0.05$

Table 3. Effects of repeated oral ingestion of sublethal doses of abamectin to adult male rats, on the fertility of females, and the mean weights of offspring, compared to the control treatment

Treatment	Exposure period [days]	Mean no. of offspring ±SEM	Mean weight of offspring [g] ±SEM
Group-T1			
Abamectin [30 mg/kg b.wt]	30	4.10±0.34 b	32.82±3.64 a
Control-C1	30	6.20±0.90 a	33.15±2.26 a
Group-T2			
Abamectin [10 mg/kg b.wt]	210	1.90±0.56 c	22.82±3.25 b
Control-C2	210	6.00±1.0 a	33.10±2.61 a

Means followed by the same letter within each column are not significantly different at $p < 0.05$; b.wt. – body weight

Histopathological observations

Histopathological changes were observed in all selected organs of abamectin-treated animals. Lobular structure in rats unexposed to abamectin showed normal hepatocytes cells which were well arranged, separated from sinusoid, and uniformly stained (Fig. 1A). In contrast to the normal histological examination of the liver tissue of the controls, marked degenerative changes of hepatocytes, congestion, and marked diffuse necrosis of hepatic tissue were observed in liver of abamectin-treated animal (Figs. 1B, 1C). Such necrobiotic changes were more intense in the livers of group T2. Moreover, fibrosis was observed in the portal triads associated with disruption of sinusoids and marked degenerative changes of hepatocytes along with evidence of marked congestion (Fig. 1C). Sections of the control rats' kidneys demonstrated normal renal histo architecture of the kidney glomerular, and surrounding tubules (Fig. 2A). Even the kidneys showed marked necrobiotic changes in abamectin-treated animals as compared to the normal histological examination of renal tissue in the control rats. A marked necrosis of tubular cells, atrophy of the glomeruli, and areas of interstitial infiltration of round cells were found (Figs. 2B, 2C). Also, selected lung sections of the control rats showed normal tissue morphology without any pathological deformities (Fig. 3A). However, some necrobiotic changes were observed in the lungs of abamectin-treated rats. Interstitial pneumonia with marked congestion and oedema were observed in lung of animals exposed for 30 days to abamectin (Fig. 3B). Moreover, diffuse local hemorrhages associated with atelectasis were seen in the lungs of animals exposed to abamectin for 210 days (Fig. 3C). The examination of selected sections of testes showed that the control group demonstrated normal testicular histology with all the successive stages of spermatogenesis (Fig. 4A). There was a degeneration of some spermatogonia cells in the testes of rats from group T1 (Fig. 4B). Moreover, a marked degenerative and necrosis of spermatogonia cells lining seminiferous tubules associated with peritubular oedema and lumen, contained a decreased number of spermatogenic elements in the testes from group T2 (Fig. 4C).

DISCUSSION

In toxicity studies, a variety of biochemical parameters are measured to evaluate a broad range of physiological and metabolic functions affecting target organ identification and tissue injury assessment (Akhtar *et al.* 2012). A combination of some common biochemical parameters provide better information from pattern recognition, e.g. enzymes like ALT and AST for hepatotoxicity, and urea and creatinine for glomerular function (Evans 1996). The results of the present study showed that *per os* administration of abamectin, at 1/30 LD₅₀ for a period of 210 days (group T2) significantly increased the levels of plasma ALT, AST, urea, and creatinine in treated male rats, compared to the control group. Changes in ALT and AST levels differ depending on the exposure time, where the increase in enzyme activities were markedly observed in animals of group T2 compared to those of

group T1. These findings were in agreement with the results obtained by Hsu *et al.* (2001). They indicated that the activities of ALT and AST levels were elevated in abamectin-dosed rats in a dose-dependent manner at 1, 3, and 12 h, respectively. Activities of serum enzymes like AST and ALT, represent the functional status of the liver (Cremer and Seville 1982). As certain hepatic damage is considered pathologically irreversible (Helling *et al.* 1995), the elevation of AST may render the liver to be more susceptible to other pathogen/toxicants (Chamulitrat and Spitzer 1996; Nayak *et al.* 1996). Aspartate aminotransferase is an important indicator of liver damage in clinical studies. During hepatocellular injury, AST was found to be secreted into the blood (Kalender *et al.* 2005). In dying or damaged cells, these enzymes leak into the blood stream (Mansour and Mossa 2010).

The elevation in the liver enzyme activities may be due to liver dysfunction with a consequent reduction in enzyme biosynthesis and altered membrane permeability permitting enzyme leakages into the blood (Mansour and Mossa 2010). The liver is susceptible to damage because of direct exposure to toxic products. The liver plays a role in the detoxification of metabolic by-products and xenobiotics. In the present study, the increased levels of AST and ALT could be due to hepatotoxicity causing permeability alterations and leakage of lysosomal enzymes enhancing the release of enzymes (Choudhary *et al.* 2003; Shrivastava *et al.* 1989). The elevation of ALT and AST levels in this study suggests probable liver tissue damage due to abamectin. The damage may be seen in the histopathological lesions in the livers of abamectin-treated rats. The liver is the organ which biotransforms most xenobiotics. Early pathological changes like congestion, haemorrhages, and other necrobiotic changes in the liver are probably associated, due to decreased free radical (O²) scavenger formation. Most prominent lesions produced by xenobiotics include vacuolar degeneration, degeneration of hepatic cords and hepatocytes, focal to extensive necrosis, and enlargement and dilation of sinusoids (Yavasoglu *et al.* 2006).

Our study also revealed the obvious significant increase in blood uric acid and creatinine concentrations with the subchronic abamectin administration (group T2) compared to group T1 and the control. Similar findings were demonstrated by Eissa and Zidan (2010), who reported a significant increase in serum uric acid and creatinine levels, in male rats administered with 1/10 and 1/100 LD₅₀ of abamectin for 30 days. The treated animals' elevation of uric acid and creatinine concentrations may be attributed to the reduction in glomerular filtration in the kidney. Such an elevation also reflects the dysfunction of the kidney tubules (Walmsley and White 1994). The increase of uric acid concentration is a demonstration of impaired kidney function since the organ primarily excretes urea in the urine. The increase in creatinine due to abamectin administration, was also correlated closely with the histopathological changes in the kidney. Marked hemorrhage, congestion, and other degenerative changes were seen in the kidneys. Elevated creatinine is correlated with an increased protein catabolism, as creatinine is the end product of protein catabolism. This is supported by

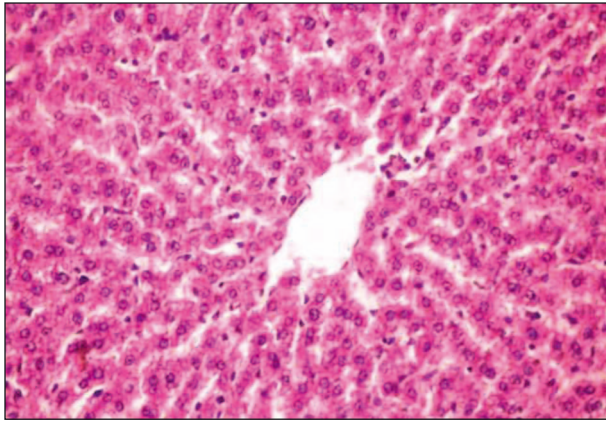


Fig. 1A. Photomicrograph of the liver from a control rat showing normal morphological architecture of the central vein and surrounding hepatocytes (H & E 200)

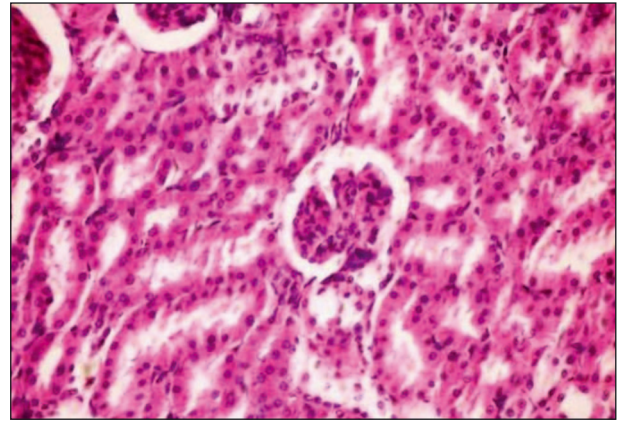


Fig. 2A. Photomicrograph of the kidney from a control rat showing normal renal histo architecture of the glomerular, surrounding tubules (H & E 200)

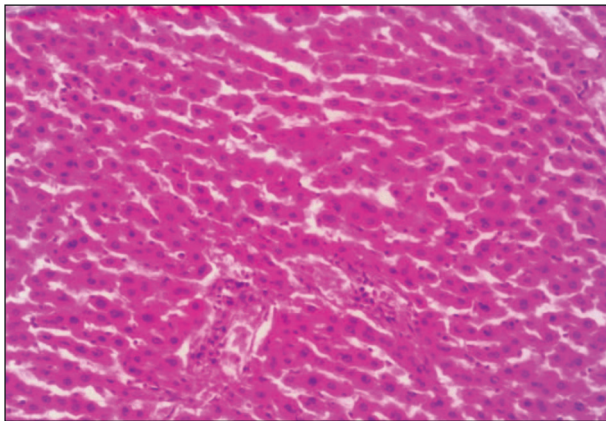


Fig. 1B. Photomicrograph of liver tissue showing congestion and disruption of sinusoids after oral administration of abamectin at 30 mg/kg for 30 days (H & E 200)

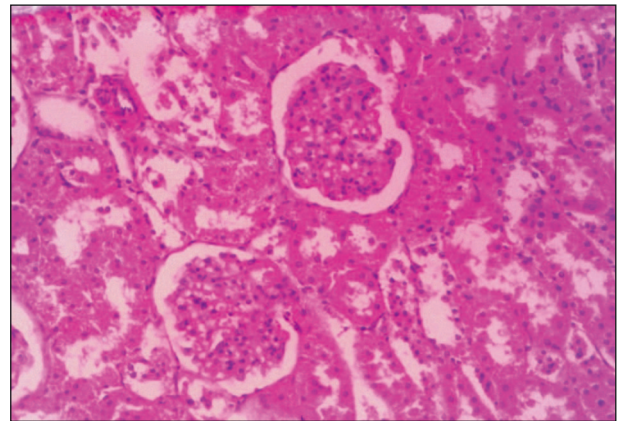


Fig. 2B. Photomicrograph of kidney tissue showing necrobiotic changes of renal tubular epithelium and vacuolation of endothelial lining glomerular tufts after oral administration of abamectin at 30 mg/kg for 30 days (H & E 200)

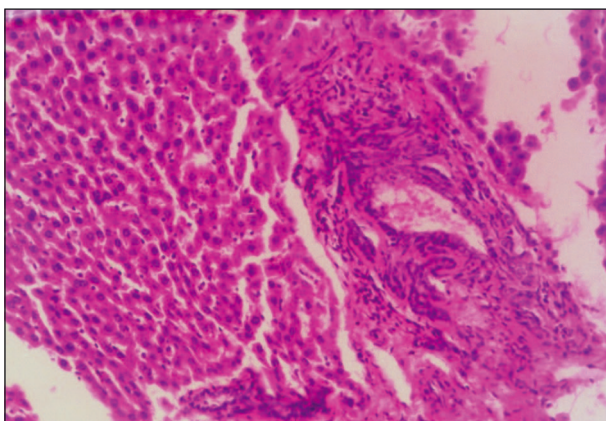


Fig. 1C. Photomicrograph of liver tissue showing fibroses in the portal triad associated with atrophy of hepatocytes congestion, disruption of sinusoids, marked degenerative changes of hepatocytes along with evidence of marked congestion, after oral administration of abamectin at 10 mg/kg for 210 days (H & E 200)

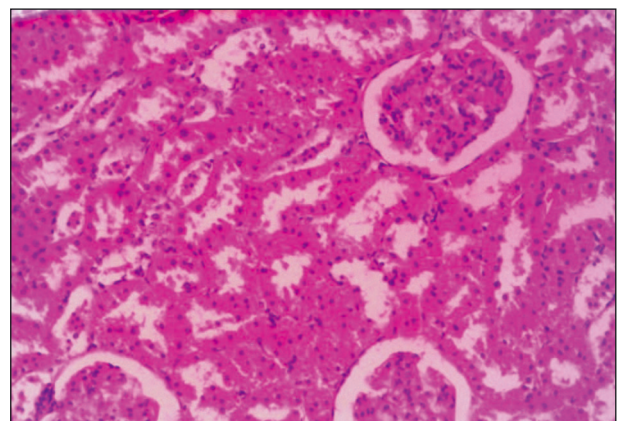


Fig. 2C. Photomicrograph of kidney tissue showing necrobiotic changes of renal tubular epithelium, and pyknosis of their nuclei after oral administration of abamectin at 10 mg/kg for 210 days (H & E 200)

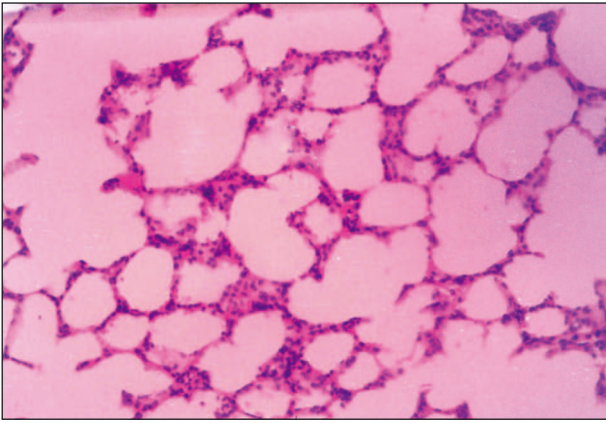


Fig. 3A. Photomicrograph of the lung from a control rat showing normal tissue morphology without any pathological deformities (H & E 200)

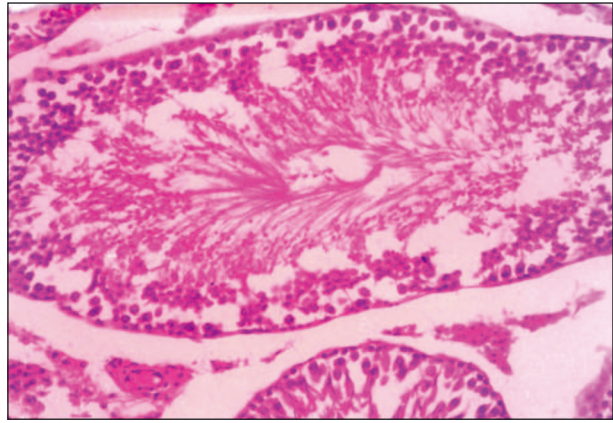


Fig. 4A. Photomicrograph of the testes of a control rat showing normal morphological structure with all the successive stages of spermatogenesis, and lumen filled with spermatozoa (H & E 200)

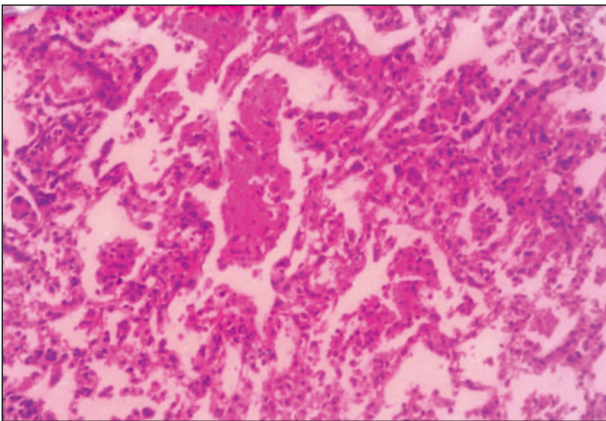


Fig. 3B. Photomicrograph of lung tissue showing interstitial pneumonia with marked congestion and oedema after oral administration of abamectin at 30 mg/kg for 30 days (H & E 200)

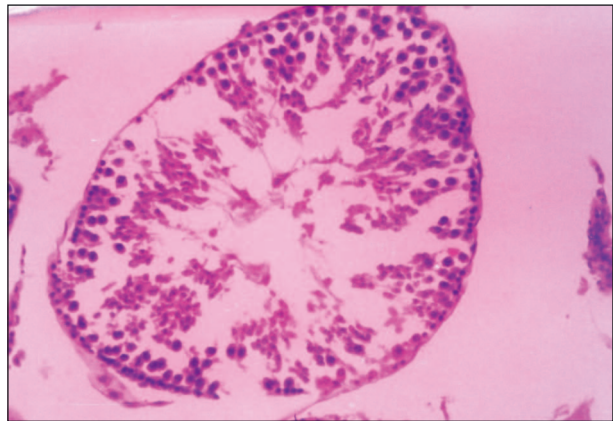

Fig. 4B. Photomicrograph of the tissue of testes showing degeneration of spermatogonia cells lining seminiferous tubules, and lumen contains fewer spermatozoa after oral administration of abamectin at 30 mg/kg for 30 days (H & E 200)

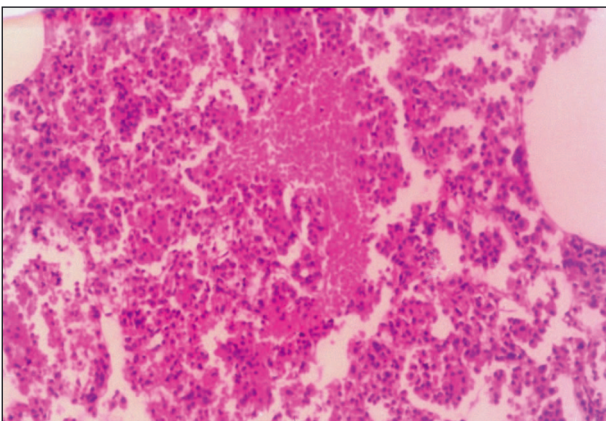


Fig. 3C. Photomicrograph of lung tissue showing local hemorrhage associated with atelectasis after oral administration of abamectin at 10 mg/kg for 210 days (H & E 200)

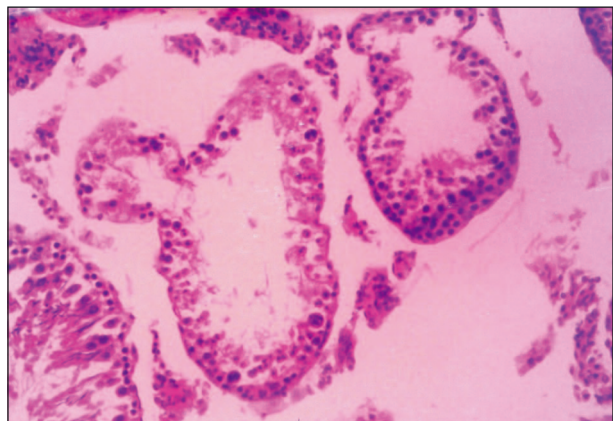


Fig. 4C. Photomicrograph of the tissue of testes showing marked degenerative and necrosis of spermatogonia cells lining seminiferous tubules associated with peritubular oedema, and lumen contains a decreased number of spermatogenic elements after oral administration of abamectin at 10 mg/kg for 210 days (H & E 200)

the result obtained in the present study, in which abamectin was noted to decrease the level of total protein due to its enhanced catabolism.

The present study also showed that a 210-day subchronic abamectin administration (group T2) caused a significant reduction in the protein and RNA levels of either liver or kidney tissues, when compared to those obtained from the control. Changes were obviously less in group T1, where animals were exposed to a 30-day repeated dose. The total protein concentration was significantly ($p < 0.05$) lower in Wistar rats exposed to subchronic-chlorpyrifos treatment (Ambali *et al.* 2011). Ksheerasagar and Kaliwal (2006) revealed that prolonged exposure of carbosulfan for 30 days caused a significant decrease in the levels of protein, glycogen, DNA, and RNA, in the livers of female and male mice. Shivanandappa and Krishnakumari (1981) have also reported that in the rats treated with BHC, significant reduction was caused in hepatic DNA and RNA, with an indication of cell death due to focal necrosis. In the present study, the reason for decreased RNA levels in the liver of rats under the influence of abamectin treatment, might due to decreased mitotic index and disturbed cell division (Topaktas *et al.* 1996) or caused by inhibitory action of pesticides on DNA and RNA synthesis (Walter *et al.* 1980) or by cell death due to focal necrosis (Shivanandappa and Krishnakumari 1981). The decrease in total proteins and soluble proteins indicates their metabolic utilization (Swamy *et al.* 1992). The increase in the activity of proteases was associated with the decrease of soluble and total protein. The changes in the levels of protein and glycogen suggest either an increased catabolism of the biomolecules to meet the enhanced energy demand of animals under stress or their reduced synthesis due to impaired tissue function (Ivanova-Chemishanska 1982).

The adverse effects of abamectin on the fertility of adult male rats have been demonstrated in the present study. Rat offspring were significantly reduced when male rats were treated with abamectin for 210 days (group T2) as compared with the control. Elbetieha and Da'as (2003) indicated that ingestion of abamectin for 6 weeks induced adverse effects on male rat fertility and reproduction. They also reported that epididymal and testicular sperm counts and daily sperm production were significantly decreased in males given abamectin. The serum level of testosterone was also significantly reduced, whereas the serum level of the follicle-stimulating hormone was significantly increased in males that ingested abamectin at a concentration of 2.13 mg/animal/day. In the present study, a histopathological examination showed some necrobiotic changes in the tissues of the testes from group T2 males, such as oedema in intertubular spaces with vacuolation within tubules. Such histopathological lesions are probably associated with the adverse effects of male fertility and offspring reduction. An explanation for the observed decrease in male fertility could be that abamectin may have acted directly on the testes and affected the androgen biosynthesis pathway. Similar studies have indicated a strong link between male infertility and the exposure to more than 50 pesticides including abamectin (Cox 1996). Rats given 0.04 mg/kg/day of abamectin had increased stillbirths, decreased pup viability, decreased lactation, and decreased pup weights (US EPA 1990).

CONCLUSION

The results of this study demonstrate that subchronic oral administration of abamectin, at 1/30 LD₅₀ for 210 days, induces toxic effects on biochemical functions which correlate well with the histopathological changes in the liver, kidneys and testes. Although the data on rats cannot be directly applied to human being, it may be concluded that use of abamectin may cause hazardous effects at various levels to non-target organisms.

REFERENCES

- Abd-Elhady H.K. 2012. Insecticidal activity and chemical composition of essential oil from *Artemisia judaica* L. against *Callosobruchus maculatus* (F.) (Coleoptera: Bruchidae). J. Plant Prot. Res. 52 (3): 347–352.
- Abd-Elhady H.K., Heikal H.M. 2011. Selective toxicity of three acaricides to the two-spotted spider mite *Tetranychus urticae* and predatory mite *Phytoseiulus persimilis* in apple orchards. J. Entomol. 8 (6): 574–580.
- Akhtar A., Deshmukh A.A., Raut C.G., Somkuwar A.P., Bhagat S.S. 2012. Prallethrin induced serum biochemical changes in Wistar rats. Pestic. Biochem. Physiol. 102 (2): 160–168.
- Ambali S.F., Akanbi D.O., Oladipo O.O., Yaqub L.S., Kawu M.U. 2011. Subchronic chlorpyrifos induced clinical, haematological and biochemical changes in swiss albino mice: protective effect of vitamin E. Int. J. Biol. Med. Res. 2 (2): 497–503.
- Burg R.W., Stapley E.O. 1989. Isolation and characterization of the producing organism. p. 24–32. In: "Ivermectin and Avermectin" (W.C. Campbell, ed.). Springer-Verlag, New York, 363 pp.
- Burtis C.A., Brunis D.E. 2007. Tietz Fundamentals of Clinical Chemistry. 6th ed. Saunders, Philadelphia, 976 pp.
- Chamulitrat W., Spitzer J.J. 1996. Nitric oxide and liver injury in alcohol-fed rats after lipopolysaccharide administration. Alcohol Clin. Exp. Res. 20 (6): 1065–1070.
- Choudhary N., Sharma M, Verma P., Joshi S.C. 2003. Hepato and nephrotoxicity in rat exposed to endosulfan. J. Environ. Biol. 24 (3): 305–308.
- Chung K., Yang C.C., Wu M.L., Deng J.F., Tsai W.J. 1999. Agricultural avermectins: and uncommon but potentially fatal cause of pesticide poisoning. Ann. Emerg. Med. 34 (1): 51–57.
- Clark J.M., Scott J.G., Campos F., Bloomquist J.R. 1995. Resistance to avermectins: extent, mechanisms, and management implications. Annu. Rev. Entomol. 40: 1–30.
- CoStat Program. 2006. Disclaimer and License for CoStat 6.3. Cohort Software Inc, Monterey (<http://www.cohort.com/DownloadCoStat.html>). Accessed: September 2011.
- Cox C. 1996. Pesticides and male fertility. J. Pestic. Rev. 16 (2): 2–7.
- Cremer J.E., Seville M.P. 1982. Comparative effects of two pyrethroids, deltamethrin and cismethrin on plasma catecholamines and on blood glucose and lactate. Toxicol. Appl. Pharmacol. 66 (1): 124–133.
- Culling C.F.A. 1974. A Hand Book of Histopathological and Histochemical Techniques. 3rd ed. Butter worth and Co. Ltd., 712 pp.

- Doumas B.T., Watson W.A., Biggs H.G. 1971. Albumin standards and measurement of serum albumin with bromocresol green. *Clin. Chim. Acta.* 31 (1): 87–96.
- Dow AgroSciences. 1998. Material Safety Data Sheet., Sanamectin 18 EC. Dow Agro Sciences LOC, Indianapolis, Indiana. Document No. PS 057, 5 pp.
- Eissa F.I., Zidan N.A. 2010. Haematological, biochemical and histopathological alterations induced by abamectin and *Bacillus thuringiensis* in male albino rats. *Acta Biol. Hung.* 61 (1): 33–44.
- Elbetieha A., Da'as S.I. 2003. Assessment of antifertility activities of Abamectin pesticide in male rats. *Ecotoxicol. Environ. Safety* 55 (3): 307–313.
- El-Shenawy N.S. 2010. Effects of insecticides fenitrothion, endosulfan and abamectin on antioxidant parameters of isolated rat hepatocytes. *Toxicol. In Vitro* 24 (4): 1148–1157.
- Evans C.O. 1996. General introduction. p. 1–9. In: "Animal Clinical Chemistry a Primer for Toxicologists" (G.O. Evans, ed.). USA Taylor & Francis Inc., Frost Road, Suite 101, Bristol, 216 pp.
- Fawcett J.K., Scott J.E. 1960. Determination of urea (urease modified Berthelot reaction). *J. Clin. Pathol.* 13 (2): 156–159.
- Fisher M.H., Mrozik H. 1989. Chemistry. p. 1-23. In: "Ivermectin and Abamectin" (W.C. Campbell, ed.). Springer-Verlag, New York, 363 pp.
- Helling T.S., Wogahn B.M., Olson S.A., Evans L.S., Reddy B.R., VanWay C. 1995. The effect of prostaglandin E1 on liver adenine nucleotides and cytoplasmic enzymes in a porcine model of normothermic hepatic ischemia. *Hepatology* 22 (5): 1554–1559.
- Houto O. 1985. Kinetic Determination of Creatinine. p. 220–234. In: "Interpretation of Clinical Laboratory Tests" (J. Henny, G. Siest, F. Schiele, D.S. Young, eds.). Biomedical Publications, California, USA, 459 pp.
- Hsu D.Z., Hsu C.H., Huang B.M., Liu M.Y. 2001. Abamectin effects on aspartate aminotransferase and nitric oxide in rats. *Toxicology* 165 (2–3): 189–193.
- Ivanova-Chemishanska L. 1982. Dithiocarbamates. p. 158–169. In: "Toxicity of Pesticides, Health Aspects of Chemical Safety". WHO Copenhagen. Interim Document 9.
- Kalender S., Ogutcu A., Uzunhisarcikli M., Acikgoz F., Durak D., Ulusoy Y., Kalender Y. 2005. Diazinon-induced hepatotoxicity and protective effect of vitamin E on some biochemical indices and ultrastructural changes. *Toxicology* 211 (3): 197–206.
- Kolar L., Erzen N.K., Hogerwerf L., Van Gestel C.A.M. 2008. Toxicity of abamectin and doramectin to soil invertebrates. *Environ. Pollut.* 151 (1): 182–189.
- Ksheerasagar R.L., Kaliwal B.B. 2006. Histological and biochemical changes in the liver of albino mice on exposure to insecticide, carbosulfan. *Caspian J. Env. Sci.* 4 (1): 67–70.
- Lankas G.R., Gordon L.R. 1989. Toxicology. p. 131–143. In: "Ivermectin and Abamectin" (W.C. Campbell, ed.). Springer-Verlag, New York, 363 pp.
- Lowenstein M., Loupal G., Baumgartner W., Kutzer E. 1996. Histology of the skin and determination of blood and serum parameters during the recovery phase of sarcoptic mange in cattle after avermectin (Ivomec) treatment. *Appl. Parasitol.* 37 (2): 77–86.
- Luna L.G. 1968. Manual of Histologic Staining Methods of the Armedforce Institute of Pathology. McGraw Hill Book Co., New York, 39 pp.
- Mansour S.A., Mossa A.H. 2010. Oxidative damage, biochemical and histopathological alteration in rat exposed to chlorpyrifos and the role of zinc as antioxidant. *Pest. Biochem. Physiol.* 96 (1): 14–23.
- McCavera S., Walsh T.K., Wolstenholme A.J. 2007. Nematode ligand-gated chloride channels: an appraisal of their involvement in macrocyclic lactone resistance and prospects for developing molecular markers. *Parasitology* 134 (8): 1111–1121.
- Nayak N.C., Sathar S.A., Mughal S., Dutttagupta S., Mathur M., Chopra P. 1996. The nature and significance of liver cell vacuolation following hepatocellular injury-an analysis based on observations on rats rendered tolerant to hepatotoxic damage. *Virchows Archiv.* 428 (6): 353–365.
- Reitman S., Frankel S. 1957. A colorimetric method for the determination of serum glutamic oxalacetic and glutamic pyruvic transaminases. *Am. J. Clin. Path.* 28 (1): 56–60.
- Schneider W.C. 1957. Determination of acids in tissues by pentose analysis. p. 680–684. In: "Method Enzymology" (S.P. Colwick, N.O. Kaplan, eds.). Vol. III, Academic Press, New York, 1154 pp.
- Seixas J.N., Peixoto P.V., Armien A.G., Jabour F.F., Brito M.F. 2006. Clinical and pathogenetic aspects of abamectin poisoning in calves. *Pesq. Vet. Bras.* 26 (3): 161–166.
- Shivanandappa T., Krishnakumari M.K. 1981. Histochemical and biochemical change in rats fed dietary benzene hexachloride. *Indian J. Exptl. Biol.* 19 (12): 1163–1168.
- Shrivastava A.K., Raina R., Choudhary R.K., Malik T.K. 1989. The acute toxicity and biochemical alterations in rats after single oral exposure to dichlorvos. *Pesticides* 2 (1): 35–40.
- Swamy K.V., Ravikumar R., Murali M.P. 1992. Effect of chronic sub lethal daily dosing of monocrotophos on some aspects of protein metabolism in rat brain. *Bull. Environ. Contam. Toxicol.* 49 (5): 723–729.
- Topaktas M., Rencuzogullari E., Ila H.B. 1996. *In vivo* chromosomal aberrations in bone marrow cells of rats with marshal. *Mutat Res.* 371 (3–4): 259–264.
- US EPA. 1990. Pesticide Fact Sheet Number 89.2: Avermectin B1. Office of Pesticides and Toxic Substances, Washington, DC., USA., 143 pp.
- Walmsley R.N., White G.H. 1994. A Guide to Diagnostic Clinical Chemistry. 3rd ed., Blackwell Publication, London, UK., 543 pp.
- Walter Z., Czakowska A., Lipecka K. 1980. Effect of malathion on the genetic material of human lymphocytes stimulated by phytohemagglutinin (PHA). *Human Genet.* 53 (3): 375–381.
- Yang C.C. 2008. Avermectin Poisoning. *Clin. Toxicol.* 46 (5): 351–421.
- Yavasoglu A., Sayim F., Uyanikgil Y., Turgut M., Karabay-Yavasoglu N.U. 2006. The pyrethroid cypermethrin induced biochemical histological alterations in rat liver. *J. Health Sci.* 52 (6): 774–780.