

DOI 10.1515/pjvs-2015-0031

Original article

Comparative analysis of markers of cell proliferation in canine mast cell tumours according to current classifications

M. Kandefer-Gola, J.A. Madej, S. Dzimira, M. Nowak, I. Janus, R. Ciaputa

Department of Pathology, Division of Pathomorphology and Veterinary Forensics,
Wrocław University of Environmental and Life Sciences, C.K. Norwida 31, Wrocław 50-375, Poland

Abstract

The study aimed at immunohistochemical analysis of various markers of cell proliferation and comparison of the results with canine mast cell tumours grading systems according to the Patnaik and Kiupel. Tissue sections were stained using classical technique with haematoxylin and eosin, and immunohistochemical studies were performed with Ki-67, PCNA and MCM-3 antibodies. Additionally the mitotic index was assessed. Statistical analysis including rank correlation Spearman's and ANOVA Friedman analysis was performed. The significance was set at $p < 0.05$. Expression of all examined antigens was detected. The results obtained allow concluding that there is a strong relationship between all the cell markers. However, due to the very strong response and positive reaction in the majority of tumours PCNA is not recommended as a prognostic indicator. Ki-67 and MCM-3 can be successfully used in the evaluation of canine mast cell tumours.

Key words: dog, Ki-67, Kiupel grading system, mast cell tumour, MCM-3, Patnaik grading system, PCNA

Introduction

Mast cell tumour (MCT) is currently one of the most common type of canine skin tumour (Patnaik et al. 1984, Amagai et al. 2013, Ciaputa et al. 2013). Its biological behaviour may vary from a single usually benign lesion to a malignant metastasizing tumour. To date, diagnosis of MCT was based mostly on the histological grading system proposed by Patnaik et al. (1984). According to this system, grade I tumours are benign. The nuclei are round with condensed chromatin, no mitotic figures are visible. Grade II

MCTs are characterized by the large, hyperchromatic nuclei with scattered chromatin and visible nucleolus. The mitotic index is low, usually corresponding to 0-2 figures per high power field (hpf). In the most malignant, grade III MCTs, vesiculated nuclei contain one or more nucleoli. The mitotic index usually corresponds to 3-6 figures per hpf (Patnaik et al. 1984).

The Patnaik system was introduced in 1984 and is still considered the gold standard for MCT grading. The most serious weakness of this scale is associated with the most prevalent grade II MCTs. The most frequently diagnosed malignancy II grade is charac-

terized by a large heterogeneity of tumours. Predicting clinical behaviour of the intermediate grade tumours can be challenging. Although most of the II grade MCTs can be successfully treated by surgical resection, some tumours from this group represent highly aggressive phenotype, with involvement of local lymph nodes and formation distant metastases (London and Seguin 2003). Moreover, histopathological diagnosis of MCT based on the Patnaik grading system was shown to be highly subjective (Northrup et al. 2005, Preziosi et al. 2007, Strefezzi et al. 2009). Therefore, Kiupel et al. (2011) proposed a two-tier grading system for canine MCTs. The 2-tier grading system is based on the number of mitotic figures (MFs, at least 10 per 10 hpf in the most highly mitotically active areas of the tumour), the presence of karyomegaly (nuclear diameters of at least 10% of cells are enlarged at least two-fold), multinucleated cells (at least three cells with three or more nuclei per 10 hpf) or bizarre nuclei (at least three kidney-shaped, segmented or irregular nuclei per 10 hpf) (Kiupel et al. 2011). Unfortunately, previous studies verifying the usefulness of the 2-tier grading system for canine MCTs included relatively small number of specimens. This stimulated us to verify the accuracy of the Patnaik and Kiupel grading systems with an aid of markers of cell proliferation.

The aim of the present study was to assess the proliferation rate based on the analysis of the expression of the PCNA (proliferating cell nuclear antigen), Ki-67 and MCM-3 (mini-chromosome maintenance protein) proteins in canine mast cell tumours. The comparison of results with canine mast cell tumours grading systems according to the Patnaik and Kiupel was the another goal. Additionally the mitotic index (MI) was assessed. MI is a relatively simple method for assessing the proliferation rate, research should show whether it may be comparable with markers of cell proliferation. We hypothesized that determination of such markers can be useful to compare the accuracy of the Patnaik and Kiupel grading systems. It should allow to determine proliferation rate more precisely and therefore will indicate which scale is more accurate to predict the prognosis. Consequently, another aim of this study was to determine the usefulness of various markers of cell proliferation. Statistical analysis of relationships between the expressions of various proteins should disclose the most reliable markers of proliferating rate, which can be helpful in predicting the prognosis. High proliferation potential is associated with faster growth of the tumour, and is often associated with greater risk for local recurrence and formation of distant metastases. Therefore, the markers of cell proliferation are often used to distinguish between benign and malignant lesions (Romanik et al. 2007).

Materials and Methods

The study included 60 MCTs collected at the Department of Pathology, Wrocław University of Environmental and Life Sciences (Poland) in 2013. The tumours were excised from dogs of various breeds, sex and ages. Although the age of dogs with MCTs ranged between 0.5 and 14 years, the vast majority of tumours (n=42) were obtained from the animals aged between 6 and 9 years. The specimens originated from 27 females and 33 males. Most MCTs were excised from mongrels (n=14), boxers (n=12), and Labrador Retrievers (n=8), followed by American Staffordshire Terriers (n=6), bull terriers (n=3), Weimaraners (n=2), and single representatives of other breeds.

The specimens were fixed in 7% buffered formalin for 24 h, embedded in paraffin wax, cut into 3-4 µm-thick sections, and routinely stained with hematoxylin and eosin (H&E). The immunohistochemical analyses were conducted on 4 µm-thick paraffin sections mounted on silanized slides. The slides were heated in citrate buffer (pH 6.0, 97°C, 20 min) to retrieve the antigens. Then the slides were double washed with TBS, block in 10% normal serum with 1% BSA in TBS. Afterwards, respective primary antibodies: Monoclonal Mouse Anti-Human Ki-67 Antigen Clone MIB-1 (DAKO®, 1:50 dilution), PCNA Clone PC10 (DAKO®, 1:100 dilution) and MCM-3 Clone 101 (Novocastra, 1:100 dilution) were applied, and the slides were incubated at room temperature for 20 min. Subsequently, the slides were washed in TBS. After rinsing, endogenous peroxidase was blocked in 3% solution of hydrogen peroxide for 10 minutes. The immunohistochemical reactions were developed with 3,3-diaminobenzidine tetrahydrochloride (DAB). Finally, the slides were counterstained with hematoxylin. Either a positive or a negative control was performed for each marker studied. The specificity of the immunolabelling was verified by incubation with PBS instead of the specific primary antibody, and the sections of the canine skin were used as positive controls.

MI was counted as an average number of cells in mitosis per 5 randomly chosen hpf (under 40x objective lens).

Nuclear expressions of PCNA, Ki-67 and MCM-3 were scored according to a semi-quantitative scale (0-5% of stained nuclei: no reaction [-], 6-25%: weak reaction [+], 26-50%: moderate reaction [++], above 50%: intense reaction [+++]). The number of cells showing the positive nuclear reaction to the studied antigens was determined in 5 randomly selected areas of each slide examined at 400 x.

The microphotographs of all specimens examined were taken with an Olympus BX53 optic microscope

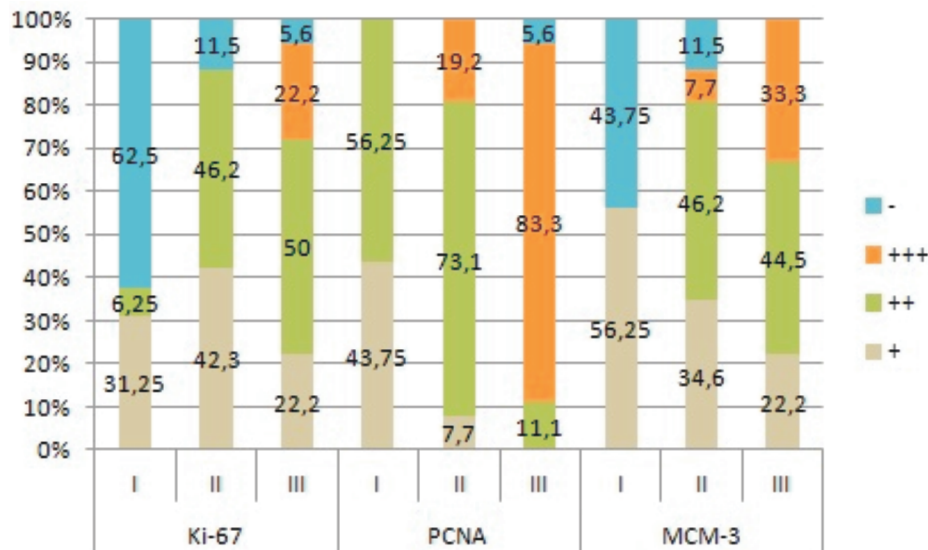


Fig. 1. The percentages of Ki-67-, PCNA- and MCM-3-positive lesions among grade I, II and III mast cell tumours according to the Patnaik system.

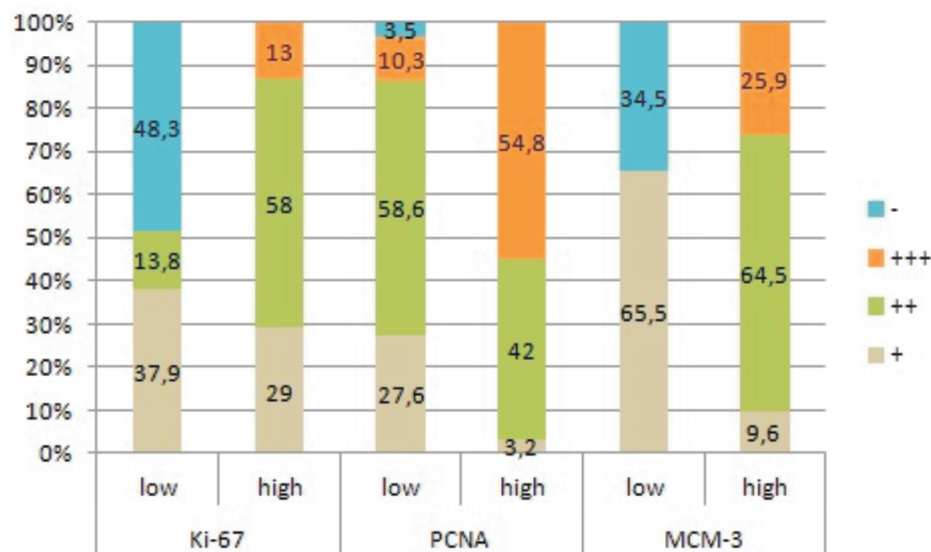


Fig. 2. The percentages of Ki-67-, PCNA- and MCM-3-positive lesions among low- and high-grade mast cell tumours according to the Kiupel system.

(Olympus, Japan) equipped with a Color View IIIa digital camera (Olympus, Japan).

The results were subjected to statistical analysis with Statistica PL package (StatSoft, Poland). The power and direction of associations between pairs of variables were determined on the basis of the Spearman's rank coefficients of correlation (R). The correlation between the grade of tumour malignancy determined by H&E staining in both scales [according to Patnaik et al. (1984) and Kiupel and al. (2011) grading systems], as well as the correlation between the score in each of scales and expression of examined proteins (PCNA, Ki-67 and MCM-3), and the correlation between the expression of individual protein pairs (PCNA – Ki-67, PCNA – MCM-3, Ki-67 – MCM-3)

were analysed. Additionally, the correlation between MI and tumour malignancy grade and the expression of markers of cell proliferation was performed. The significance of intergroup differences (between the expression of PCNA, Ki-67 and MCM-3) was verified with the Friedman ANOVA. The statistical significance of all the tests was set at $p < 0.05$.

Results

Based on the microscopic examination of H&E-stained specimens, 16 tumours were classified as Patnaik grade I, 26 as grade II, and 18 as grade III. The analyzed material included 28 low-grade and 32 high-grade MCTs according to the Kiupel system.

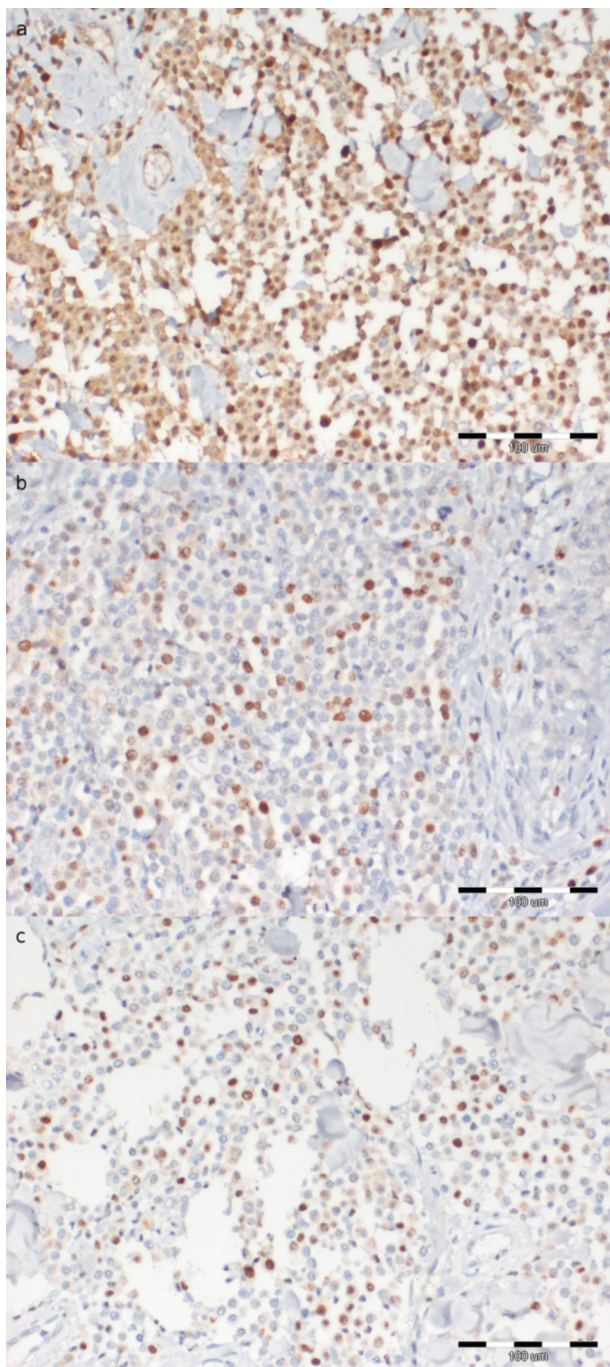


Fig. 3. Poorly differentiated mast cell tumour. The expression of PCNA is visible within nuclei. The cytoplasmic reaction was not considered during the evaluation (a). Immunolabelled nuclei in Ki-67 staining (b). The nuclear pattern in MCM-3 (c). x200.

Nearly all the tumours (98.3%) showed the expression of PCNA. Only one lesion (1.7%) did not show any reaction to PCNA. Detailed information about the percentages of PCNA-positive lesions according to the Patnaik and Kiupel grading systems are included in Fig. 1 and Fig. 2. Apart from brown nuclear staining, also the cytoplasmic reaction to PCNA

was observed in some cells. However, only the nuclear reaction was considered as a positive result during further analyses. The number of PCNA-positive cells per specimen varied considerably. Nuclear and cytoplasmic reaction were observed (Fig. 3a).

The expression of Ki-67 was determined on the basis of nuclear reaction to this protein. Fourteen out of the 60 MCTs (23.3%) did not show any reaction to this protein. The percentage of Ki-67-positive neoplasms according to the Patnaik and Kiupel grading systems are specified (Fig. 1, 2). Pronounced expression of Ki-67 in aggressive mast cell tumour was disclosed (Fig. 3b).

Also the expression of MCM-3 was analyzed on the basis of nuclear reaction to this protein. A total of 10 (16.7%) tumours did not show any reaction to MCM-3 [-]. The percentage of MCM-3 positive lesions according to both scales are presented in Fig. 1 and 2. MCM-3 showed strong reaction in malignant lesions (Fig. 3c).

Mitotic index was at the average level of 0.2 in MCT I, 2.9 in MCT II and 6.8 in MCT III; 1 in low-grade and 5.6 in high-grade lesions.

Prognostic value of the analyzed markers of cell proliferation was additionally verified on statistical analysis. We found significant ($p < 0.05$) correlations between the Patnaik grades and expressions of Ki-67 ($R = 0.63$), PCNA ($R = 0.6$) and MCM-3 ($R = 0.67$). The correlation between H&E staining [according to Kiupel et al. (2011)] was at the level of Ki-67 ($R = 0.85$), PCNA ($R = 0.53$) and MCM-3 ($R = 0.67$). Moreover, significant correlations were found between the expressions of PCNA and Ki-67 ($R = 0.5$), PCNA and MCM-3 ($R = 0.61$), Ki-67 and MCM-3 ($R = 0.7$). The coefficient of correlation between the Patnaik and Kiupel grades amounted to 0.71 (Fig. 4). Also a significant correlation between the MI and Patnaik grading ($R = 0.83$), Kiupel grading ($R = 0.78$), MCM-3 ($R = 0.76$), Ki-67 ($R = 0.82$) and PCNA ($R = 0.66$) was observed. The expression of PCNA turned out to be significantly stronger than the expressions of Ki-67 and MCM-3 ($p < 0.05$). The abovementioned findings point to strong associations between the analyzed markers of cell proliferation.

Discussion

Estimation of a proliferation potential is an essential component of histopathological evaluation of every tumour. Irrespective of the grading system used, the evaluation of MCTs should include determination of their mitotic index and nuclear morphology. This points to the usefulness of cell proliferation studies. PCNA and Ki-67 have been used for many years as

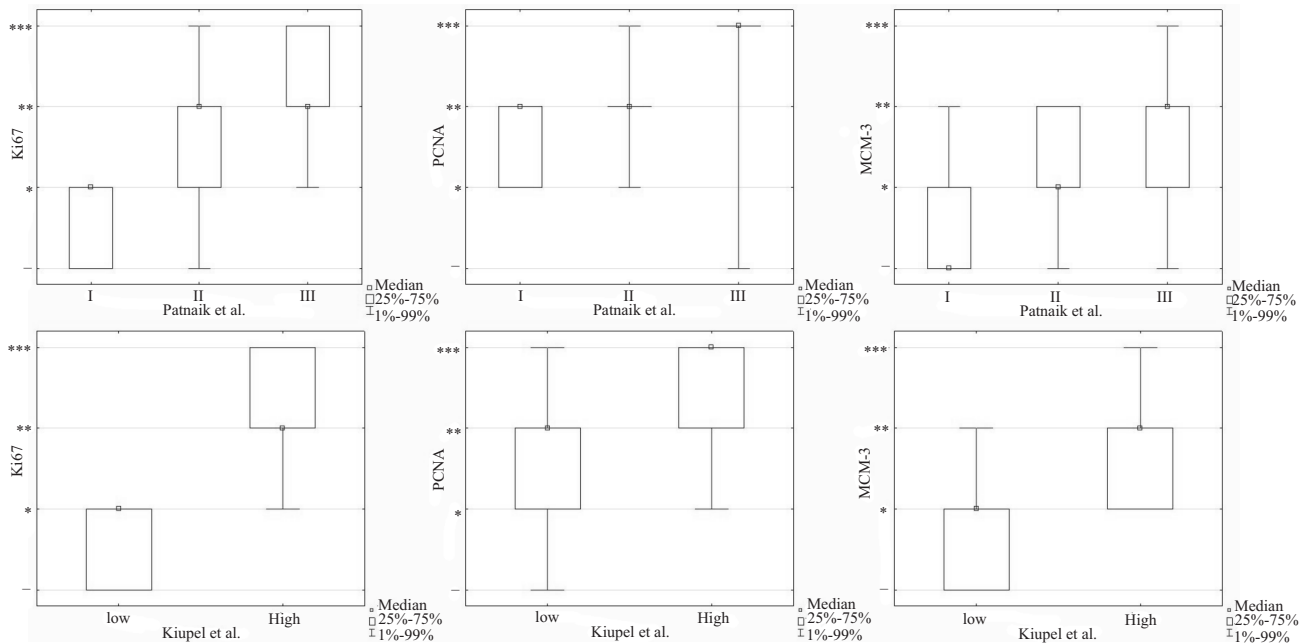


Fig. 4. Expressions of Ki-67, PCNA and MCM-3 stratified according to the Patnaik and Kiupel grades, $p < 0.05$.

markers of cell proliferation, and both constitute established prognostic factors for MCT (Simoes et al. 1994, Abadie et al. 1999, Bergman et al. 2004). However, to the best of our knowledge, this study was the first analysis of MCM-3 expression in canine mast cell tumours.

Ki-67, expressed solely by active cells, is one of the most often determined markers of cell proliferation. This protein can be detected during all phases of the cell cycle except from G_0 . The expression of Ki-67 increases from G_1 phase, and reaches its peak level during the M phase (Scholzen and Gerdes 2000). Since many previous studies showed that Ki-67 is an accurate prognostic marker for MCT (Abadie et al. 1999, Scase et al. 2006, Webster et al. 2007, Dos Santos Costa Poggiani et al. 2012), we used its expression as a reference value for other analyzed proteins and histopathological grading systems. We showed that the expression of Ki-67 increased proportionally to the MCT grade. This observation is consistent with the results published by other authors (Abadie et al. 1999, Scase et al. 2006, Webster et al. 2007), according to whom the expression of Ki-67 should be routinely examined in MCTs. Moreover, we observed strong, positive correlations between the expression of Ki-67 and MCT grade determined with either the Patnaik or the Kiupel system ($R=0.63$ and $R=0.85$ for the Patnaik and Kiupel system, respectively). The higher coefficient of correlation documented in the case of the Kiupel system points to greater accuracy of the latter classification.

PCNA is another widely used marker of cell proliferation. This protein is vital for the continuity of the

cell cycle; therefore, its expression is observed from G_1 to M phase, with the peak values during the S phase. The expression of PCNA may be also associated with the processes of DNA repair (Maga and Hubscher 2003). Furthermore, PCNA is characterized by a long half-life, and thus the activity of this protein can be also detected in post-mitotic cells (Bravo and Macdonald-Bravo 1987, Maga and Hubscher 2003). Similar to Ki-67, many previous studies analyzed PCNA as a marker for MCT (Maga and Hubscher 2003, Bergman et al. 2004, Scase et al. 2006, Webster et al. 2007). The distributions of PCNA expression in our series did not differ significantly between the two analyzed grading systems. Noticeably, only one tumour did not show the nuclear reaction to this antigen. Furthermore, the correlations between the expression of PCNA and MCT grades determined with the two hereby analyzed systems turned out to be the weakest of all the studied markers of cell proliferation, and the expression of this protein was significantly stronger than that of the remaining markers. This can be explained by the fact that the expression of PCNA is associated not only with cell proliferation, but can be also detected during the processes of DNA repair and in post-mitotic cells. This evidence does not support the use of PCNA as a marker for MCT proliferation. Our findings in this matter are consistent with the data published by other authors (Scase et al. 2006, Webster et al. 2007).

The MCM proteins (2-9) control initiation and elongation of DNA (Aparicio et al. 1997). During G_1 phase of the cell cycle, the inactive proteins are bound to the replication initiation sites. Subsequently, during

the S phase, they are transformed into enzymatically active helicases (Lei and Tye 2001). Similar to Ki-67, MCM-3 is specific solely for proliferating cells (Musahl et al. 1998). In our study, the expression of this protein did not increase proportionally to the Patnaik grade. The greatest variance was observed in the case of grade II MCTs that showed either no reaction [-] (0-5% of cells with the nuclear reaction) or very strong reaction to MCM-3 [+++] (more than 50% of positive cells). This might result from an inappropriate grading of H&E-stained slides, but the correctness of diagnosis of results obtained was confirmed with anti Ki-67. The results of immunohistochemical staining for MCM-3 were concordant with the results of staining for Ki-67. It is noteworthy that the expression of MCM-3 in most tumours examined was slightly stronger than the expression of Ki-67. This difference likely reflected longer activity of the MCM proteins throughout the cell cycle (Giaginis et al. 2010). The expression of MCM-3 increased proportionally to the MCT grade determined according to Kiupel et al. (2011), probably due to the lack of intermediate grade in this classification. The values of Spearman's coefficients of correlation between either the Patnaik or the Kiupel grades, and the expression of MCM-3 were the same ($R=0.67$). These findings suggest that MCM-3 can be a useful prognostic marker for canine MCT.

The expression of PCNA showed the weakest correlations with the expressions of the remaining proteins. MI is a good prognostic parameter of proliferation rate; its results are comparable with immunohistochemical ones. The immunohistochemical analysis of proliferation rate is essential in cases of undifferentiated mast cell tumours. In turn, the strongest correlation was observed between the expressions of Ki-67 and MCM-3; this points to the accuracy of the two proteins as adjunct diagnostic and prognostic markers for canine MCT. Statistical analysis of the tumour malignancy grade determined by H&E staining also showed a strong positive correlation between the two evaluation scales (0.71), indicating their comparable usefulness in histopathological diagnostic. However, immunohistochemical studies and statistical data between the grade of tumour malignancy and Ki-67 and MCM-3 expression suggest a slightly higher usefulness of the scale by Kiupel et al. (2011) to assess the proliferation rate of the tumour cells.

References

- Abadie JJ, Amardeilh MA, Delverdier ME (1999) Immunohistochemical detection of proliferating cell nuclear antigen and Ki-67 in mast cell tumors from dogs. *J Am Vet Med Assoc* 215: 1629-1634.
- Amagai Y, Tanaka A, Matsuda A, Oida K, Jung K, Matsuda H (2013) The phosphoinositide 3-kinase pathway is crucial for the growth of canine mast cell tumors. *J Vet Med Sci* 75: 791-794.
- Aparicio OM, Weinstein DM, Bell SP (1997) Components and dynamics of DNA replication complexes in *S. cerevisiae*: redistribution of MCM proteins and Cdc45p during S phase. *Cell* 91: 59-69.
- Bergman PJ, Craft DM, Newman SJ, Baer K, Camps-Palau MA, McKnight JA, Leibman NF, Brenn S, Finora K, Hohenhaus AE, Bartick T, Patnaik AK, Scase T (2004) Correlation of histologic grading of canine mast cell tumors with Ki67/PCNA/AgNOR/c-Kit scores: 38 cases (2002-2003). *Vet Comp Oncol* 2: 98.
- Bravo R, Macdonald-Bravo H (1987) Existence of two populations of cyclin/proliferating cell nuclear antigen during the cell cycle: association with DNA replication sites. *J Cell Biol* 105: 1549-1554.
- Ciaputa R, Kandefer-Gola M, Nowak M, Madej JA (2013) Prevalence of tumours in domestic animals in the Lower Silesia (Poland) in 2009-2011. *Bull Vet Inst Pulawy* 57: 53-59.
- Dos Santos Costa Poggiani S, Terra EM, Neto RT, Costa MT, Amorim RL (2012) Canine Cutaneous Mast Cell Tumour: Biologic Behavior and its Correlation with Prognostic Indicators. *OJVM* 2: 255-261.
- Giaginis C, Vgenopoulou S, Vielh P, Theocharis S (2010) MCM proteins as diagnostic and prognostic tumors marker in the clinical setting. *Histol Histopathol* 25: 351-370.
- Kiupel M, Webster JD, Bailey KL, Best S, DeLay J, Detrisac CJ, Fitzgerald SD, Gamble D, Ginn PE, Goldschmidt MH, Hendrick MJ, Howerth EW, Janovitz EB, Langohr I, Lenz SD, Lipscomb TP, Miller MA, Misdorp W, Moroff S, Mullaney TP, Neyens I, O'Toole D, Ramos-Vara J, Scase TJ, Schulman FY, Sledge D, Smedley RC, Smith K, W Snyder P, Southorn E, Stedman NL, Stefcick BA, Stromberg PC, Valli VE, Weisbrode SE, Yager J, Heller J, Miller R (2011) Proposal of a 2-tier histologic grading system for canine cutaneous mast cell tumours to more accurately predict biological behavior. *Vet Pathol* 48: 147-155.
- Lei M, Tye BK (2001) Initiating DNA synthesis: from recruiting to activating the MCM complex. *J Cell Sci* 114: 1447-1454.
- London CA, Seguin B (2003) Mast cell tumors in the dog. *Vet Clin North Am Small Anim Pract* 33: 473-489.
- Maga G, Hubscher U (2003) Proliferating cell nuclear antigen (PCNA): a dancer with many partners. *J Cell Sci* 116: 3051-3060.
- Musahl C, Holthoff HP, Lesch R, Knippers R (1998) Stability of the replicative Mcm3 protein in proliferating and differentiating human cells. *Exp Cell Res* 241: 260-264.
- Northrup NC, Howerth EW, Harmon BG, Brown CA, Carmicheal KP, Garcia AP, Latimer KS, Munday JS, Rakich PM, Richey LJ, Stedman NL, Gieger TL (2005) Variation among pathologists in the histologic grading of canine cutaneous mast cell tumors with uniform use of a single grading reference. *J Vet Diagn Invest* 17: 561-564.
- Patnaik AK, Ehler WJ, MacEwen EG (1984) Canine cutaneous mast cell tumor: morphologic grading and survival time in 83 dogs. *Vet Pathol* 21: 469-474.

- Preziosi R, Sarli G, Paltrinieri M (2007) Multivariate survival analysis of histological parameters and clinical presentation in canine cutaneous mast cell tumours. *Vet Res Commun* 31: 287-296.
- Romansik EM, Reilly CM, Kass PH, Moore PF, London CA (2007) Mitotic index is predictive for survival for canine cutaneous mast cell tumors. *Vet Pathol* 44: 335-341.
- Scase TJ, Edwards D, Miller J, Henley W, Smith K, Blunden A, Murphy S (2006) Canine mast cell tumors: correlation of apoptosis and proliferation markers with prognosis. *J Vet Intern Med* 20: 151-158.
- Scholzen T, Gerdes J (2000) The Ki-67 protein: from the known and the unknown. *J Cell Physiol* 182: 311-322.
- Simoes JP, Schoning P, Butine M (1994) Prognosis of canine mast cell tumors: a comparison of three methods. *Vet Pathol* 31: 637-647.
- Strefezzi RdeF, Xavier JG, Kleeb SR, Catao-Dias JL (2009) Nuclear morphometry in cytopathology: a prognostic indicator for canine cutaneous mast cell tumors. *J Vet Diagn Invest* 21: 821-825.
- Webster JD, Yuzbasiyan-Gurkan V, Miller RA, Kaneene JB, Kiupel M (2007) Cellular proliferation in canine cutaneous mast cell tumors: associations with c-KIT and its role in prognostication. *Vet Pathol* 44: 298-308.