

FOLIA MEDICA CRACOVIENSIA

Vol. LVII, 4, 2017: 55–62

PL ISSN 0015-5616

Canaliform median raphe cysts (MRCs) lined by squamous epithelium in a 5 year old male patient; report of a rare case and comprehensive review of the literature

DIMITRIOS PATOULIAS¹, MARIA KALOGIROU², KYRIAKOS CHATZOPOULOS³,
IOANNIS PATOULIAS⁴

¹Department of Internal Medicine, General Hospital of Veria, Veria, Greece

²Department of Internal Medicine, General Hospital of Trikala, Trikala, Greece

³Department of Pathology, General Hospital 'G. Gennimatas', Thessaloniki, Greece

⁴1st Department of Pediatric Surgery, Aristotle University of Thessaloniki, General Hospital 'G. Gennimatas', Thessaloniki, Greece

Dimitrios Patoulis: MD, Resident in Internal Medicine

Maria Kalogirou: MD

Kyriakos Chatzopoulos: MD, Resident in Pathology

Ioannis Patoulis: MD, PhD, Consultant Pediatric Surgeon

Corresponding author: Dimitrios Patoulis, MD

M. Alexandrou 3B, Pefka, Thessaloniki, Postal code 57010, Greece

Phone: +30 23 102 250 83; E-mail: dipatoulis@gmail.com

Abstract: Median raphe cysts (MRCs) are rare, benign congenital lesions of unknown origin, that can be found anywhere on the ventral side of the genital area, between the urethral meatus and the anus. The rarity of our case is attributed to the canaliform type, the scrotal and perineal localization and the epidermoid epithelium. A 5 year old boy, with free perinatal and family history, was admitted to our department as an outpatient due to the presence of an elongated and mildly painful lesion in the middle of the scrotum, gradually increasing in size. During physical examination the presence of a painful, subcutaneous, yellowish lesion, extending from the scrotal to the perineal raphe, was documented. Patient underwent elective surgery, under general endotracheal anesthesia, and complete resection of the lesion was conducted. Histopathological examination revealed the presence of a canaliform lesion consisting of five cysts, lined by squamous epithelium and filled with lamellate keratin.

In conclusion: a) preventive removal of MRCs is considered as the safest treatment option, in order to be avoided future, potential complications regarding urination and sexual intercourse, b) if therapeutic intervention is delayed, especially after development of inflammation of MRCs, then the likelihood both of iatrogenic injury to underlying structures, mainly to the penile or perineal urethra, and of relapse after resection increases significantly and c) if orchidopexy precedes the development of MRCs, the possibility of presence of ovarian serous border line tumor with Müllerian duct remnants should always be excluded.

Key words: Median raphe cyst, perineum, scrotal raphe, canaliform, squamous epithelium, male patient.

Introduction

Median raphe cysts (MRCs) are rare benign congenital lesions of unknown origin, 0.2–2.1 cm in diameter, that can be present anywhere on the ventral side of the genital area, between the external urethral meatus and the anus (parameatal area, glans, penile shaft, scrotum, and perineum) [1–3].

Mermet first reported a case of MRC in “Revue de Chirurgie” [4]. MRCs present with a bimodal age distribution at approximately 1–10 and 21–40 years old. MRCs were previously designated with multiple terms such as mucoïd cyst of the penile skin, genitoperineal cyst of the median raphe, parameatal cyst, hydrocystoma and apocrine cystadenoma [5].

Three different mechanisms have been described including fusion defect of the urethral folds, development of the ectopic para-urethral glands of Littre, and development from urethral columnar epithelium followed by separation [6]. According to Nagore *et al.* the histopathological features of the MRC are related to its embryonic origin and pathogenesis [7]. The epithelial lining of MRCs includes urethral type (55%), epidermoid type (5%), glandular type (3%), and mixed type epithelium (37%) [6]. MRCs stratified by ciliated epithelium are extremely rare [8, 9].

MRCs mostly present at birth and may remain asymptomatic or unrecognized during childhood [2, 3, 7]. 25.5% of all cases are diagnosed within the first decade of life [6]. Due to the fact that the majority of children (up to 75% of all cases) are asymptomatic, it has been suggested that MRCs are more common than it is considered [2, 6, 7]. MRCs usually develop slowly and gradually, but in rare cases they may grow rapidly, even in the absence of trauma or infection [10].

Infection and trauma are the main causes that lead to rapid development of MRCs or clinical manifestation [5, 11, 12]. Other causes include rupture of a cyst or ulcer’s development on the surface of MRCs. Pain during sexual intercourse or even rarely discomfort during urination, especially when the cyst is located near the urethral meatus, are the main symptoms. *Staphylococcus aureus* and *Neisseria gonorrhoeae* are the commonest pathogens that cause infection of MRCs [13].

MRCs should be differentially diagnosed from other conditions such as epidermal inclusion cyst, pilonidal cyst, dermoid cyst and urethral diverticulum [7, 14]. Especially in cases of perianal localization, differential diagnosis should include condyloma, viral wart, hemorrhoid, hypertrophied papilla, glomus tumor and steatocystoma [7, 15, 16].

The aim of the present case study is to highlight this rare entity, after systematic and comprehensive research of the relevant current literature. Rarity of our case is attributed to the canaliform type, the scrotal and perineal localization and the epidermoid epithelium.

Case report

A 5 year old male patient, with free perinatal and family history and without co morbidities, was admitted to our department as an outpatient complaining of the presence of an elongated, mildly painful lesion in the middle of the scrotum. Patients first noticed the presence of this lesion 6 months earlier, while the gradual increase in lesion's size was their main worry and the reason of patient's admission. During physical examination the presence of a painful, subcutaneous, yellowish lesion, extending from the scrotal to the perineal raphe, 1 cm above the anus and corresponding to 12 o'clock in lithotomy position was documented (Fig. 1).

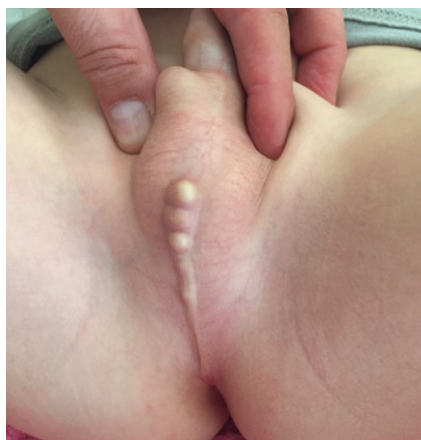

Fig. 1. Canaliform MRCs. Notice the lesion consisting of 5 cystic formations in raw that extends from scrotal to perineal raphe, 1 cm above the anus.

Ultrasound examination was then conducted. The presence of 5 consecutive cystic formations with hyperechoic content was documented, without evidence of expansion deeper to the endoscrotal structures or membranous segment of urethra at the level or perineal raphe. The patient underwent elective surgery under general endotracheal anesthesia. After the performance of an attractoid incision, the lesion

was resected within healthy limits. Anatomy course restoration of the surgical wound followed (Fig. 2–4).

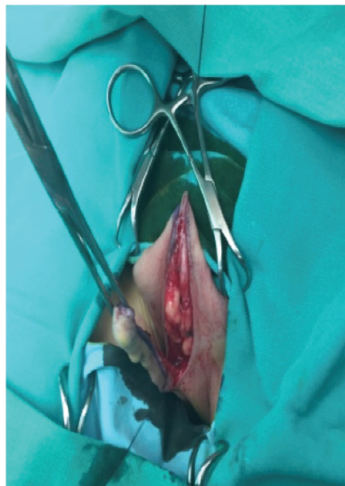


Fig. 2. Atractoid incision and resection of the MRCs within healthy limits.

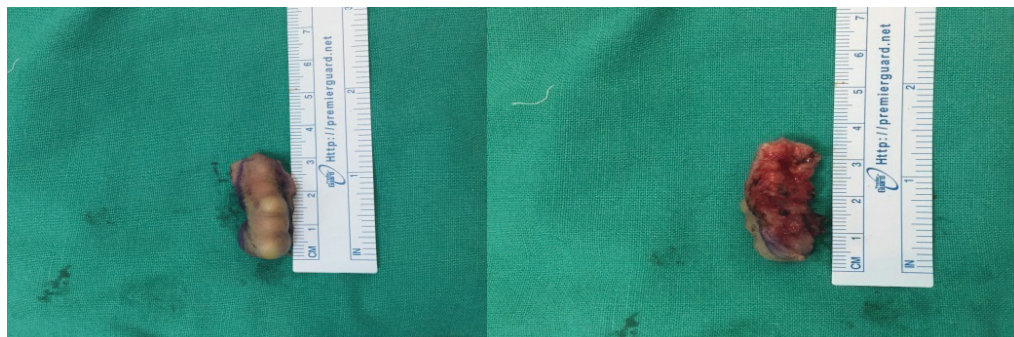

Fig. 3, 4. MRCs, 3.5 cm in length, after complete resection.

Results

Patient was easily awakened after surgery. Postoperative course was uneventful and the patient was discharged home on the 1st postoperative day in excellent general condition. Histopathological examination revealed the presence of a canaliform lesion consisting of five cysts, lined by squamous epithelium (epidermoid type) and filled with lamellate keratin (Fig. 5, 6). Postoperative follow up, on a 6-month basis, lasted 4 years. Patient remains asymptomatic, without evidence of recurrence.

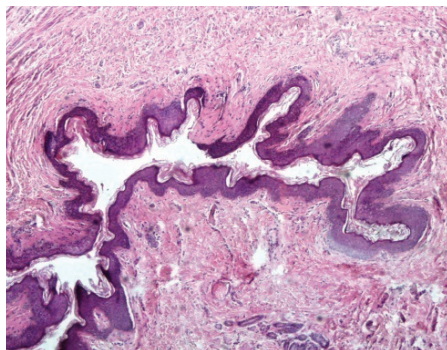


Fig. 5. Canaliform MRCs lined by thin stratified squamous epithelium and filled with lamellate keratin (HE X40).

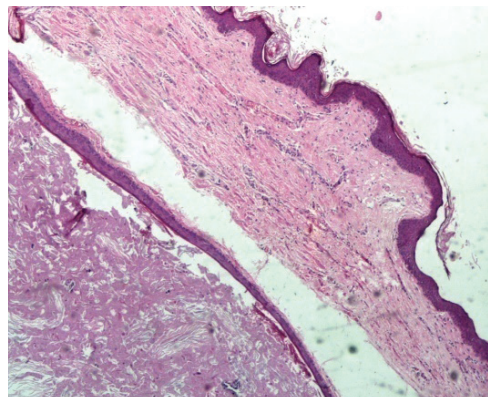


Fig. 6. The cysts were lined by thin stratified squamous epithelium and filled with lamellate keratin (HE X100).

Discussion

In their retrospective study, Shao *et al.* present 56 cases of MRCs found in 55 patients they encountered (mean age: 26.7 y.o) [6]. Cysts were found on the parameatal site in 19/56 (33.9%), on penile shaft in 24/56 (42.9%), on the glands of the penis in 4/56 (7.1%), on the scrotum in 2/56 (3.6%) and finally on the prepuce in 7/56 cases (12.7%). This is the largest retrospective study in current relevant literature, where the rarity of scrotal localization is easily recognized. Out of 56 cases, none is found on the perineal raphe, evidence of the rarity of our case. Lopez-Candel *et al.* [17] and Amaranathan *et al.* [18] also emphasize the extreme rare localization of MRCs on the perineal raphe.

Lee *et al.* report a case of a 26 year old male patient, in whom both canaliform and isolated MRCs of scrotal and perineal localization stratified by squamous epithelium co-existed [3]. It is also an extremely rare case resembling to ours, differing only as to the age of diagnosis and therapeutic intervention. Kruel *et al.* report a case of a 6 year old boy with a solitary MRC of perineal localization, lined by squamous epithelium [7]. The main difference with our case is the fact that in our patient 5 consecutive cystic formations (canaliform MRCs) were found localized both at scrotal and perineal raphe. Shin *et al.* encountered a 7 month old infant with multiple canaliform MRCs found both in scrotal and perineal raphe, lined by mixed type epithelium, which differentiates their case from ours [19]. Takahashi *et al.* described a case of a 9 year old boy with canaliform and isolated MRCs of perineal localization [20]. Distinctive characteristic from our case is that cysts were stratified by transitional epithelium of urethral origin.

MRCs may regress spontaneously [13, 21]. Shibagaki *et al.* believe that small and asymptomatic MRCs can be observed without excision, because there is the possibility of regression [22]. Therapeutic intervention may be indicated due to secondary infection leading to pain or cosmetic reasons [15, 20, 23]. Optimal treatment of MRCs is surgical excision and primary closure, which prevents infection or cosmetic sequelae [2, 6]. Aspiration alone is not recommended as a treatment option for MRCs [24]. Performance of marsupialization or unroofing in cases of deeply located large MRCs will result in a gaping sinus, which is cosmetically unacceptable [15, 25]. Alternatively, opening of the cyst's wall and cauterization of the epithelial lining by the use of diathermy coagulation has been attempted [26]. Total resection of MRCs is considered as safe, usually without postoperative complications. Shao *et al.* report that one out of the fifty-five patients they encountered (0.02%) developed postoperatively a urethrocutaneous fistula, that was attributed to the difficult removal of the MRC, due to repeated episodes of cyst's inflammation preoperatively [6].

Presence of squamous cell epithelium lining (epidermoid type of MRCs) can be interpreted embryologically either by ectodermal in growth or endodermal differentiation [27]: the stratified squamous epithelium arises from rests containing ectodermal epithelium incidental to incomplete closure of urethral or genital folds [7, 13, 27] or spit-off out growths of embryonic epithelium after closure of the urethral or genital folds [7, 28]. Park *et al.* believe that the squamous epithelium in cases of perineal MRCs arises from spit-off out growths of embryonic epithelium and not from epithelium rests [13].

Unal *et al.* consider as safe the 4 year postoperative follow up period, a point of view which we approve [5]. Shao *et al.* do not report malignant potential of MRCs during a long term follow up period of 2–11 years in their retrospective study [6]. Deliktas *et al.* report a case of a 26 year old man with a MRC found on the penile raphe, lined by pseudostratified columnar epithelium with focal squamous metaplasia [15]. The latter was documented by positive reaction for cytokeratin 7 (CK7) and carcinoembryonic antigen (CEA) after immunohistochemical examination. Hara *et al.* describe a case of a 9 year old boy suffering from bilateral cryptorchidism, who was treated by performance of orchidopexy and placement of testes in subcutaneous pouch. During the postoperative period the authors noticed the presence of a protruding, probably subcutaneous, lesion in the middle of the scrotal raphe, arising from tunica albuginea. After complete resection, histopathologic and immunohistochemical examination revealed the presence of ovarian serous border line tumor with Müllerian duct remnants. During postoperative follow up course, no recurrence or metastatic disease was documented [29].

Conclusions

1. Preventive removal of MRCs is considered as safer, in order to be avoided future, potential complications regarding urination and sexual intercourse.
2. If therapeutic intervention is delayed, especially after development of inflammation of MRCs, then the likelihood both of iatrogenic injury to underlying structures, mainly to the penile or perineal urethra, and of relapse after resection increases significantly.
3. If orchidopexy precedes the development of MRCs, the possibility of presence of ovarian serous border line tumor with Müllerian duct remnants should always be excluded.

Conflict of interest

None of the contributing authors have any conflict of interest, including specific financial interests or relationships and affiliations relevant to the subject matter or materials discussed in the manuscript.

References

1. *LeVasseur G., Perry V.E.*: Perineal median raphe cyst. *Pediatr Dermatol.* 1997; 14 (5): 391–392.
2. *Soyer T., Karabulut A.A., Boybeyi O., Gunal Y.D.*: Scrotal pearl is not always a sign of anorectal malformation: median raphe cyst. *Turkish J Pediatr.* 2013; 55 (6): 665–666.
3. *Lee J.N., Kim H.T., Cung S.K.*: Median raphe cysts of the scrotum and perineum presenting with recurrent infection. *Korean J Urogenit Tract Infect Inflamm.* 2014 9 (2): 119–121.
4. *Mermet P.*: Congenital cysts of the genitoperineal raphe. *Revue de Chirurgie.* 1895 15: 382–435.
5. *Betül Ü., Başsorgun C.I., Meryem I.E.K., Gülsüm O.E.*: Perianal Median Raphe Cyst: A Rare Lesion with Unusual Histology and Localization. *Case Reports in Dermatol Med* 2015 (2015), Article ID 487814, 3 pages.
6. *Shao I.H., Chen T.D., Shao H.T., Chen W.*: Male median raphe cysts: serial retrospective analysis and histopathological classification. *Diagn Pathol.* 2012; 7, article 121.
7. *Krauel L., Tarrado X., Garcia-Aparicio L., Lerena J., Sunol M., Rodo J., et al.*: Median raphe cysts of the perineum in children. *Urol.* 2008; 71: 830–831.
8. *Sagar J., Sagar B., Patel A.F., Shak D.K.*: Ciliated median raphe cyst of perineum presenting as perianal polyp: a case report with immunohistochemical study, review of literature, and pathogenesis. *The Scientific World Journal.* 2006 (6): 2339–2344.
9. *Fernández Aceñero M.J., García-González J.*: Median raphe cyst with ciliated cells: report of a case. *Am J Dermatopathol.* 2003; 25 (2): 175–176.
10. *Kurzrock E.A., Baskin L.S., Cunha G.R.*: Ontogeny of the male urethra: theory of endodermal differentiation. *Differentiation.* 1999; 64: 115–122.
11. *Soendjojo A., Pindha S.*: Trichomonasvaginalis infection of the median raphe of the penis. *Sex Transm Dis.* 1981; 8: 255–257.
12. *Cardoso R., Freitas J.D., Reis J.P., Tellechea O.*: Median raphe cyst of the penis. *Dermatol Online J.* 2005; 11: 37.

13. Park C.O., Chun E.Y., Lee J.H.: Median raphe cyst on the scrotum and perineum. *J Am Academy of Dermatol.* 2006; 55 (5): 114–115.
14. Little J.S., Keating M.A., Rink R.C.: Median raphe cysts of the genitalia. *J Urol.* 1992; 148 (6): 1872–1873.
15. Deliktas H., Sahin H., Celik O.I., Erdogan O.: Median raphe cyst of the penis. *J Urol.* 2015; 12 (4): 2287–2288.
16. Scelwyn M.: Median raphe cyst of the perineum presenting as a perianal polyp. *Pathol.* 1996; 28 (2): 201–202.
17. Lopez-Candel E., Roig-Alvaro J., Lopez-Candel J., Fernandez Dozagarat S., Soler J., Hernandez Bermejo J.P., et al.: Median raphe cysts of the perineum in childhood. *An Esp Pediatr.* 2000; 52 (4): 395–397.
18. Amaranathan A., Sinhasan S.P., Dasiah S.D.: Median raphe cysts of the prepuccial skin, with triple histological linings: A case report and review of the literature. *J Clin Diagn Research.* 2013; 7 (7): 1466–1468.
19. Shin S., Hamm S.K., Kim D.Y.: A case of multiple canaliform median raphe cysts showing a mixed type lining of epithelium: a case report and review of the literature. Letter to the Editor. *Ann Dermatol.* 2016; 28: 398–399.
20. Takahashi M., Watanabe T., Sato K., Ohno M., Yamada K., Takezoe T., Fuchimoto Y., Ohkita H., Matsuoka K., Kanamori Y.: Congenital median raphe cysts: Coexistence of cystic lesions and canal-like lesions. *Open Journal of Pediatrics.* 2013; 3: 274–275.
21. Willis H.L., Snow B.W., Cartwright P.C., Wallis M.C., Oottamasathien S., DeVries C.: Parametatal urethral cysts in prepubertal males. *J Urol.* 2011; 185: 1042–1045.
22. Shibagaki N., Ohtake N., Furue M.: Spontaneous regression of congenital multiple median raphe cysts of the raphe scrota. *Br J Dermatol.* 1996; 134: 376–378.
23. Pellice I., Vilalta C., Luelmo I., Aguilar J.: Cysts of the median raphe (prepuce and perineum). Brief contribution. *Actas Urol Esp.* 1997; 21 (8): 803–805.
24. Otsuka T., Ueda Y., Teraucho M., Kinoshita Y.: Median raphe (parametatal) cysts of the penis. *J Urol.* 1998; 159: 1918–1920.
25. Shiraki I.W.: Parametatal cysts of the glans penis: a report of 9 cases. *J Urol.* 1975; 114: 544–548.
26. Golitz L.E., Robin M.: Median raphe canals of the penis. *Cutis.* 1981; 27: 170–172.
27. Dini M., Baroni G., Colafranceschi M.: Median raphe cyst of the penis: a report of two cases with immunohistochemical investigation. *Am J Dermatopathol.* 2001; 23: 320–324.
28. Asarch R.G., Golitz L.E., Sausker W.F., Kreye G.M.: Median raphe cysts of the penis. *Arch Dermatol.* 1979; 115: 1084–1086.
29. Hara N., Kawaguchi M., Koike H., Takahashi K.: Median raphe cyst of the scrotum ,mimicking a serous borderline tumor, associated with cryptorchidism after orchidopexy. *Int J Urol.* 2004; 11: 1150–1152.