

DOI 10.1515/pjvs-2017-0050

*Short communication*

# Identification of Transmissible Viral Proventriculitis (TVP) in broiler chickens in Poland

M. Śmiątek<sup>1</sup>, M. Gesek<sup>2</sup>, A. Śmiątek<sup>3</sup>, A. Koncicki<sup>1</sup>

<sup>1</sup> Department of Poultry Diseases, Faculty of Veterinary Medicine, University of Warmia and Mazury, Oczapowskiego 13, 10-719 Olsztyn, Poland

<sup>2</sup> Department of Pathological Anatomy, Faculty of Veterinary Medicine, University of Warmia and Mazury, Oczapowskiego 13, 10-719 Olsztyn, Poland

<sup>3</sup> Private veterinary practice “Punkt Weterynaryjny”, Leszczynek 11A, 99-300 Kutno, Poland

## Abstract

The aim of the study was to investigate the possibility of Transmissible Viral Proventriculitis (TVP) occurrence in broiler chickens in Poland. In march 2016 proventriculi samples were collected from broiler chickens showing poor uniformity and decreased body weight, accompanied by enlarged proventriculi. Histopathological examination of affected proventriculi revealed typical lesions associated with TVP (vacuolar degeneration and necrosis of glandular epithelium, replacement of glandular epithelium by hyperplastic ductal epithelium and moderate to severe lymphocytic infiltration). To our best knowledge, up to date there is no report indicating the presence of TVP in Poland nor in Central and Eastern Europe.

**Key words:** Transmissible Viral Proventriculitis, broiler chickens, histopathology, Poland

## Introduction

Transmissible Viral Proventriculitis (TVP) is an infectious disease described in chickens of all production groups. TVP was first diagnosed in The Netherlands in 1978, when Kouwenhoven and others described a case of infectious proventriculitis in broiler chickens. Ever since, cases of TVP have been identified and described in, among others, the USA, Australia, China, South Korea, Spain, France, and recently Great Britain. It is suggested, however, that the range of TVP spreading in the chicken population may be significantly larger.

Until recently, the etiological agent inducing TVP had not been explicitly established (Dormitorio et al. 2007). Recent findings indicate that chicken birnavirus – called chicken proventriculitis necrosis virus (CPNV), is strongly associated with the development of TVP lesions (Guy et al. 2011, Grau-Roma et al. 2016).

TVP affects mainly broiler chickens between 3 – 6 weeks of age, but the disease has also been identified in 9 – 20 week old broiler breeders and chicken hens (Dormitorio et al. 2007). Production losses associated with TVP result from decreased body weight gains, reduced uniformity of birds in

a flock and increased feed conversion ratio. Anatomopathological lesions associated with TVP include: enlargement of proventriculus outline with simultaneous thickening and reduced resistance of its walls as well as elongation of the isthmus between the proventriculus and the gizzard (Dormitorio et al. 2007).

Considering the not fully elucidated etiology, it is believed that histopathological (HP) examination is the most reliable procedure to confirm the occurrence of TVP. Histopathological lesions noted in the case of TVP concern exclusively the proventriculus and are characterized by the necrosis of epithelial glandular cells, strong lymphocytic infiltration in the lamina propria of the mucous membrane and – among the proventricular glands – by the hyperplastic and metaplastic changes of ductal epithelial cells of proventricular glands with successive substitution of epithelial glandular cells with hyperplastic epithelial cells of excretory ducts (Dormitorio et al. 2007, Grau-Roma et al. 2016).

The aim of our study was to investigate if the observed field case of enlarged proventriculi in broiler chickens in Poland could be diagnosed as TVP.

## Materials and Methods

Between March and April 2016 samples of proventriculi for HP examination were collected from Ross 308 broiler chickens from a farm located in the province of Łódź in central Poland. The farm comprised of one chicken house with approximately 50 000 chickens. Selection of the farm for further studies was done based on the clinical course and observed anatomopathological lesions that suggested TVP occurrence.

**Sample collection and HP.** Fragments of the wall of the proventriculus (the central part, sampled from 4-week old birds) were embedded in 10% formalin (pH 7.4) and processed for HP examination. After passing the samples through intermediate liquids (increasing concentrations of alcohol and xylene) they were embedded in paraffin blocks. 4 µm microscope sections of the examined samples were stained with hematoxylin-eosin. Microscope samples were scanned with a Panoramic MIDI (3DHIS-TECH, Hungary) scanner.

## Results and Discussion

Clinical problems at the farm started to emerge once the birds were 3 weeks old and lasted until they were transferred for slaughter (at 45 days of age). The clinical course was identified as decreased body

weight gains, reduced uniformity of birds (well pronounced in older birds) and slightly increased death rate concerning mainly weaker and smaller birds (Fig. 1). Overall, the disease occurred in approximately 55% of the birds, and the mortality did not exceed standard values for broiler chicken production (below 5%). The necropsy revealed characteristic enlargement of the proventriculus outline with thickening of the walls (Fig. 2). In its lumen, macroscopic analysis demonstrated a small amount of mucus. In single cases, hemorrhages were also noted in proventriculi mucosa.



Fig. 1. Six week old broiler chickens from the flock diagnosed with TVP. Clinical TVP (broiler on the left) does not affect 100% of birds in the flock. Uneven growth, causing poor uniformity is usually the first sign of TVP.

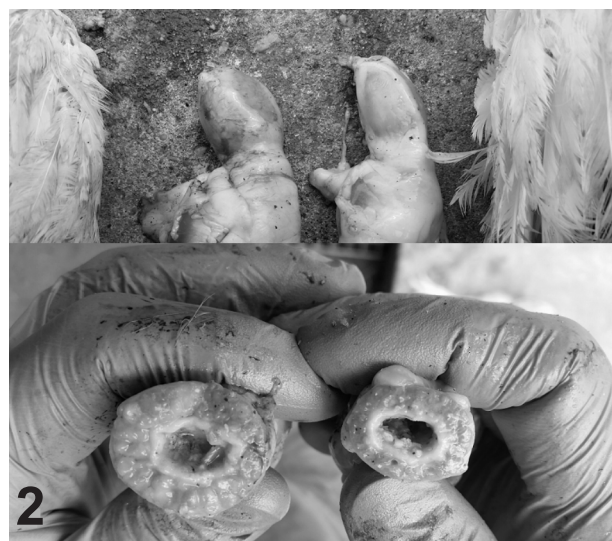

Fig. 2. Six week old broiler chickens from the flock diagnosed with TVP. Affected proventriculi (left) is enlarged (top) with thickened wall (bottom; cross section of proventriculus cut in the middle of the organ in comparison to non-affected one (right)).

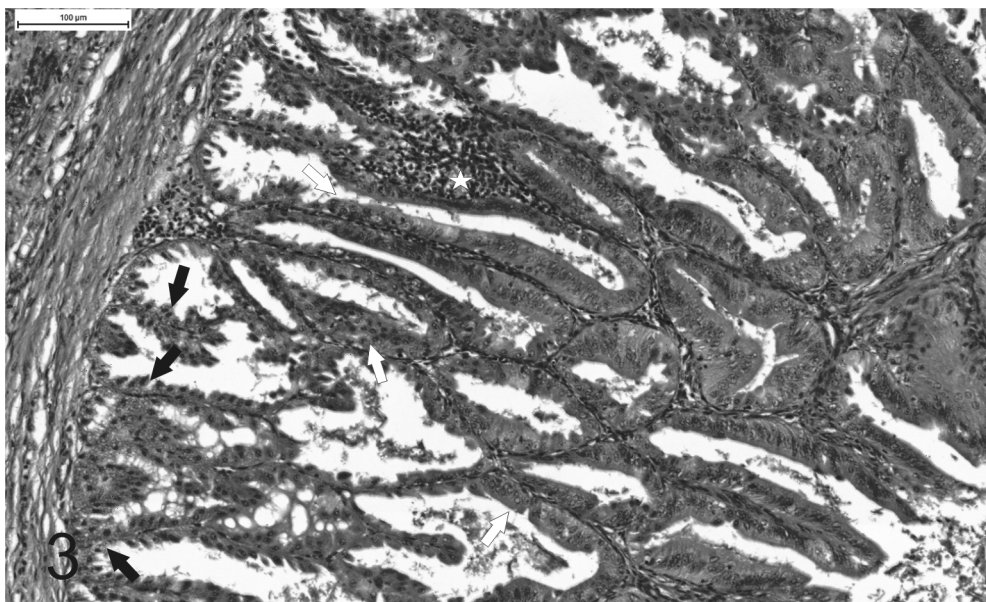


Fig. 3. Proventriculus from 4 week old broiler chicken diagnosed with TVP. Photomicrograph showing vacuolar degeneration and necrosis of glandular epithelium (black arrows); replacement of glandular epithelium by hyperplastic ductal epithelium (white arrows); infiltration of lymphoid cells (asterisk). Hematoxylin and eosin.

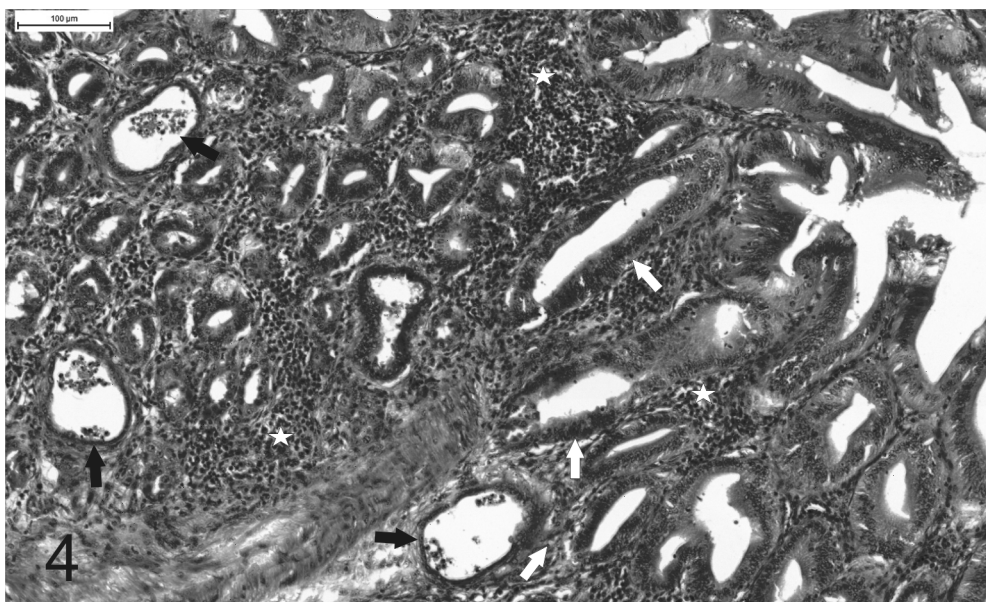


Fig. 4. Proventriculus from 4 week old broiler chicken diagnosed with TVP. Photomicrograph showing necrotic debris in dilated glandular lumen (black arrows); replacement of glandular epithelium by hyperplastic ductal epithelium (white arrows); infiltration of lymphoid cells (asterisks). Hematoxylin and eosin.

HP examination of proventriculi revealed (I) vacuolar degeneration and necrosis of glandular epithelium with pyknotic nuclei which all together created necrotic debris in dilated glandular lumen, (II) replacement of glandular epithelium by hyperplastic ductal epithelium and (III) moderate to severe, usually multifocal, lymphocytic infiltration (Figures 3 and 4); these are the three main HP changes characteristic for TVP (Dormiotrio et al. 2007, Grau-Roma et al. 2016).

The results confirmed TVP diagnosis and our field observations suggest that this was not an isolated case of TVP in broiler chickens in Poland and so far the disease is underdiagnosed. Further research is necessary in order to establish the etiology and the possible source of TVP infection and these studies are currently being undertaken. Chicken TVP could become an emerging disease not only in Poland but also in Central and Eastern Europe.

### Acknowledgements

The authors would like to thank Dr Llorenc Grau Roma, from the School of Veterinary Medicine and Science, University of Nottingham, United Kingdom for the help with the interpretation of HP scans.

### References

Dormitorio TV, Giambrone JJ, Hoerr FJ (2007) Transmissible proventriculitis in broilers. *Avian Pathol* 36: 87-91

Grau-Roma L, Reid K, de Brot S, Jennison R, Barrow P, Shnchez R, Nofrartas M, Clark M, Majó N (2016) Detection of transmissible viral proventriculitis and chicken proventricular necrosis virus in the UK. *Avian Pathol* 46: 68-75

Guy JS, West AM, Fuller FJ (2011) Physical and genomic characteristics identify chicken proventricular necrosis virus (R11/3 virus) as a novel birnavirus. *Avian Dis* 55: 2-7

Kouwenhoven B, Davelaar FG, Van Walsum J (1978) Infectious proventriculitis causing runting in broilers. *Avian Pathol* 7: 183-187