

FOLIA MEDICA CRACOVIENSIA
Vol. LVIII, 3, 2018: 83–87
PL ISSN 0015-5616
DOI: 10.24425/fmc.2018.125074

Covered perforation of Meckel's diverticulum ulcer to transverse colon: highlighting the urgent intervention and the avoidance of a dramatic evolution (case report and literature review)

IOANNIS PATOULIAS¹, MARIA KALOGIROU², EVANGELIA RACHMANI¹,
KYRIAKOS CHATZOPOULOS³, THOMAS FEIDANTSI¹, DIMITRIOS PATOULIAS⁴

¹1st Department of Pediatric Surgery, Aristotle University of Thessaloniki, General Hospital 'G. Gennimatas'
Thessaloniki, Greece

²Health Center of Kalambaka, General Hospital of Trikala, Trikala, Greece

³Department of Pathology, General Hospital 'G. Gennimatas', Thessaloniki, Greece

⁴Department of Internal Medicine, General Hospital of Veria, Veria, Greece

Corresponding author: Dimitrios Patoulias, MD
M. Alexandrou 3B, Pefka, Thessaloniki, Postal code 57010, Greece
Phone: +30 23 102 250 83; E-mail: dipatoulias@gmail.com

Abstract: Meckel's diverticulum represents a remnant of the proximal end of the omphalomesenteric duct, which constitutes a connection between the middle intestine and the vitelline vesicle. It is the most common congenital anomaly of the gastrointestinal tract and is found in approximately 0.3–2% of the general population. Complications such as hemorrhage, bowel obstruction, inflammation, perforation, intussusception, volvulus and malignant transformation develop in only 4–4.8% of all patients, with most cases presenting in childhood, while relative risk decreases during life.

The aim of the present study is to present our experience in managing a 15-year old male patient with Meckel's diverticulum covered perforation.

It was a case of disguised perforation of the Meckel's diverticulum, with development of adhesions to the anterior surface of the right third of the transverse colon, which was successfully treated on the basis of emergency. Diagnosis was made intraoperatively and was documented by histological examination of the excised diverticulum.

Key words: Meckel's diverticulum, diverticulitis, covered perforation, transverse colon.

Introduction

Meckel's diverticulum is a remnant of the proximal end of the omphalomesenteric duct, constituting a connection between the middle intestine and the vitelline vesicle [1]. It is the commonest congenital anomaly of the gastrointestinal tract, found in approximately 0.3–2% of the general population [2].

Complications such as hemorrhage, bowel obstruction, inflammation, perforation, intussusception, volvulus and malignant transformation develop in only 4–4.8% of patients, with most cases presenting in childhood with most cases presenting in adulthood, while relative risk decreases during life. Eighty percent of the symptomatic cases are diagnosed during the first 3 decades of life [1, 3, 4].

Controversy exists regarding the management of asymptomatic Meckel's diverticulum that is incidentally identified intraoperatively. Towards this direction, a number of criteria indicative of diverticulectomy have been established, including age (<40 years old), gender (males), the size of the diverticulum (diameter >2cm) and the below mentioned intraoperative findings: presence of vitelline ligament, palpable ectopic tissue and inflamed and thickened Meckel's diverticulum [5, 6]. However, palpation does not always predict the presence of ectopic tissue, while the latter is much more difficult during a laparoscopic procedure [6, 7].

The purpose of this case study is to describe this rare evolution of one common complication of Meckel's diverticulum, after comprehensive research of the relevant literature.

Case description

A 15-years old male patient with free medical history was admitted to the Emergency Department complaining of gradually worsening colicoid abdominal pain over the last here days. Physical examination revealed tenderness and rigidity in the right abdominal wall. Laboratory tests were indicative of inflammation (WBC: 13834/mm³, PMN: 87.6%, CRP: 3.4 mg/dl, limit <0.5), while ultrasonography did not reveal any pathology.

Due to gradual deterioration and the high index of clinical suspicion for the presence of intra abdominal inflammation requiring surgical intervention, we performed exploratory laparotomy, after Lanz incision. Appendix was not inflamed, but preventive appendectomy was performed. Meckel's diverticulum was found approximately 55 cm from the ileocecal valve, with observed adhesions between its posterolateral surface with the anterior surface of the right third of transverse colon. We then performed excision of the Meckel's diverticulum, with segmental bowel resection and end to end anastomosis of bowel stumps. Macroscopic evaluation of Meckel's diverticulum revealed the presence of an ulcer on its posterolateral surface in the serosa (Fig. 1).

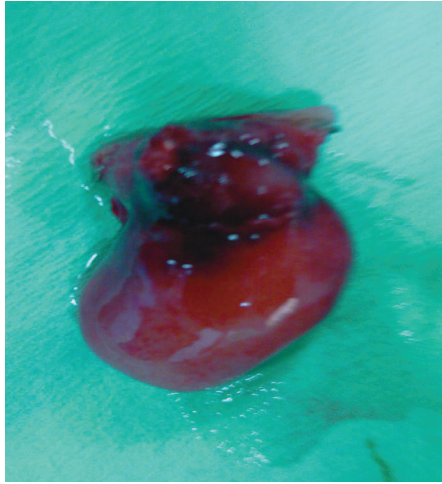


Fig. 1. Observe the ulcer in the postero lateral surface of Meckel's diverticulum in the serosa.

Postoperative course was uneventful and the patient was discharged the third postoperative day. Histological examination revealed the presence of deep covering ulcer of Meckel's diverticulum and the presence of ectopic gastric tissue. Additionally, presence of fibrous tissue in the muscle and the serosal layer of diverticulum at the level of covering ulcer was documented (Fig. 2).

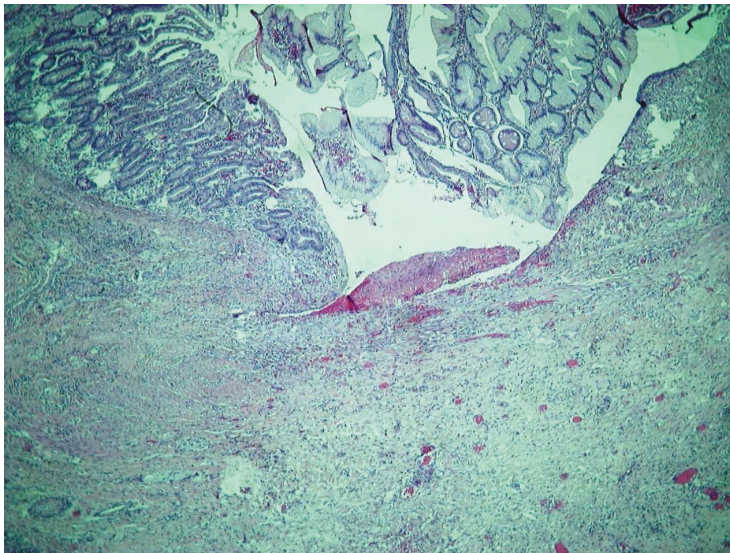


Fig. 2. Presence of an active ulcer, outlined by necrobiotic tissue, under which there was evident formation of granulation tissue (H/E \times 100).

Discussion

Ulcer's development due to the presence of ectopic gastric or pancreatic tissue or even the presence of a closed cavity into its lumen are the main causes of Meckel's diverticulum inflammation [8, 9]. The wide basis, the presence of limited lymphatic tissue and the ability of emptying its content are restrictive parameters regarding the risk of Meckel's inflammation (diverticulitis) development.

Other causes leading to diverticulitis are: a) lumen's obstruction (small dimensions of its base or accumulation of secretions within its lumen), b) adhesions or angulations, c) intussusception, d) foreign body intraluminal impaction, e) blunt abdominal trauma and finally f) stromal tumor or carcinoid arising from its wall [3, 4, 10].

Diverticulitis, present in 20 % of patients with symptomatic Meckel's diverticulum, may lead to perforation [10]. Perforation of a Meckel's diverticulum in the presence of foreign body intraluminal impaction develops due to pressure necrosis, or progressive inflammation of its wall.

Preoperative diagnosis of a patient with complicated Meckel's diverticulum is usually challenging, due to the non-specific clinical manifestation and the wide spectrum of differential diagnosis. Moreover, ultrasonography is not useful in those cases [4, 10, 11].

Additionally, performance of an abdominal CT scan or scintigraphy with technetium-99 to investigate the presence of ectopic gastric tissue in Meckel's diverticulum mucosa is an uncommon practice in cases indicative of urgent surgical exploration, as in our case [10, 11]. An open laparotomy is often required for the clinician in order to establish definite diagnosis and appropriate treatment [3]. Laparoscopy is a useful diagnostic modality in highly suspected cases [5].

In our case the presence of ectopic gastric tissue was the strong etiologic factor for Meckel's inflammation. Further potential complications due to progression of the disease could be an ileocolic fissure, generalized peritonitis or inflammatory mass development [1, 5, 12].

Lemale and colleagues reported a case of a 14-month old female patient with Meckel's diverticulum perforation and inflammatory mass development, $3 \times 2.8 \times 2$ cm in dimensions, initially evaluated as Burkitt lymphoma. Definite diagnosis was made after histopathological examination of perforated Meckel's diverticulum, which contained ectopic gastric tissue [12].

Conflict of interest

None declared.

References

1. Stănescu G.L., Pleșea I.E., Diaconu R., et al.: Meckel's diverticulum in children, clinical and pathological aspects, Rom J Morphol Embryol. 2014; 55 (3 Suppl): 1167–1170.
2. Rattan K.N., Singh J., Dalal P., Rattan A.: Meckel's diverticulum in children: Our 12-year experience. Afr J Paediatr Surg. 2016; 13 (4): 170–174.
3. Farah R.H., Avala P., Khaiz D., et al.: Spontaneous perforation of Meckel's diverticulum: a case report and review of literature. Pan Afr Med J. 2015; 20: 319.
4. Butz N., Krones C.J., Bohm G., et al.: Perforation of the sigmoid colon as a result of Meckel's diverticulitis in a child. Grand Rounds. 2004; 4: 16–18.
5. Anyfantakis D., Kastanakis M., Papadomichelakis A., et al.: Perforation of Meckel's diverticulum by a wood splinter in a 4-year-old child: a case report. J Med Life. 2013; 6 (2): 195–197.
6. Robijn J., Sebrechts E., Miserez M.: Management of incidentally found Meckel's diverticulum. A new approach: Resection based on a risk score. Acta Chir Belg. 2006; 106: 467–470.
7. Varcoe R.L., Wong S.W., Taylor C.F., Newstead G.L.: Diverticulectomy is inadequate treatment for short Meckel's diverticulum with heterotopic mucosa. ANZ J Surg. 2004; 74: 869–872.
8. Chen J.J., Lee H.C., Yeung C.Y., et al.: Meckel's Diverticulum: Factors Associated with Clinical Manifestations. ISRN Gastroenterol. 2014; 2014: 390869.
9. Alkan M., Güler G., Yildirim F., Doran F., Zorludemir U., Olcay I.: Perforation of an inflamed Meckel's diverticulum in a newborn: report of a case. Turk J Gastroenterol. 2009; 20 (3): 235–236.
10. Miyata S., Bliss D.W.: A gastrointestinal stromal tumor found in perforated Meckel's diverticulum. Surg Case Rep. 2016; 2: 67.
11. Pietrzak J., Obuchowicz A., Majda D., Kiedos A.: Meckel's diverticulum — a congenital defect of the gastrointestinal tract underestimated in differential diagnosis. Own experience. Dev Period Med. 2017; 21 (1): 38–42.
12. Lemale J., Boudjemaa S., Parmentier B., et al.: A pseudotumoral lesion revealing Meckel's diverticulum. Arch Pediatr. 2016; 23 (11): 1157–1160.