

FOLIA MEDICA CRACOVIENSIA

Vol. LX, 3, 2020: 113–119

PL ISSN 0015-5616

DOI: 10.24425/fmc.2020.135800

Intramuscular hemangioma in the anterior scalene muscle in an infant boy: a case report

IOANNIS PATOULIAS¹, IOANNA GKALONAKI¹, MAGDALINI MITROUDI¹, THOMAS FEIDANTISIS¹,
CONSTANTINE THEOCHARIDIS², DIMITRIOS PATOULIAS³

¹First Department of Pediatric Surgery, Aristotle University of Thessaloniki,
General Hospital “G. Gennimatas”, Greece

²Department of Pathology, General Hospital “G. Gennimatas”, Thessaloniki, Greece

³Second Propedeutic Department of Internal Medicine, Aristotle University of Thessaloniki,
General Hospital “Hippokraton”, Greece

Corresponding author: Dimitrios Patoulias, M.D., M.Sc., Ph.D. candidate
Second Propedeutic Department of Internal Medicine, General Hospital “Hippokraton”, Thessaloniki, Greece
Konstantinoupoleos 49, Thessaloniki, Postal code 54642, Greece
Phone: +30 69 46 900 777; E-mail: dipatoulias@gmail.com

Abstract: The extremely rare localization of an intramuscular hemangioma (IMH) into the anterior scalene muscle was the motive for the present case report, aiming to highlight major, atypical characteristics. An 11-month-old boy with free medical history presented with a painless and progressively growing lesion 4.5 × 4 cm in diameter, located in the left supraclavicular region over the last 4 months. During physical examination, the presence of a painless, non-pulsating, non-adhesive to the overlying skin lesion was documented. Color Doppler flow ultrasonographic examination demonstrated the increased blood supply to the aforementioned lesion. Thus, we planned an elective surgical excision of the lesion in healthy limits. The postoperative course was uneventful, and the patient was discharged on the second postoperative day in good general condition. Histopathologic examination revealed the presence of hemangioma surrounded by connective tissue bundles and striated muscle fibers.

IMHs do not follow the general rule of regression, beyond the age of 6–12 months, with no trend to increase over time. Accurate preoperative diagnosis is challenging. Color Doppler flow ultrasonographic examination is the imaging modality of choice during the preoperative assessment. Surgical excision of the IMH in healthy limits is the most appropriate treatment option.

Key words: intramuscular hemangioma, anterior scalene muscle, child, surgical excision.

Submitted: 12-Sep-2020; **Accepted in the final form:** 25-Oct-2020; **Published:** 30-Nov-2020.

Introduction

Hemangiomas are benign proliferative vascular lesions characterized by increased endothelial cell turnover, which usually appear after birth, grow rapidly, and then evolve over the years [1]. Liston was the first to describe benign and congenital neoplasms found in lower extremity muscles as intramuscular hemangioma (IMH) [2]. IMH accounts for about 1% of all hemangiomas, and 14%–21% of them are found in the head and neck regions [3].

The extreme rarity of IMH localization in the anterior scalene muscle was the motive for the present case report, aiming at highlighting features that do not fall under the typical manifestation of hemangiomas.

Case description

An 11-month old boy was admitted by his parents to the Outpatient Department due to the presence of a painless, growing over the last 4 months lesion, found in the left supraclavicular region. Physical examination revealed the presence of a painless, lobular, pulseless, non-adhesive to the overlying skin lesion, 4.5×4 cm in dimensions. No bruit or systolic-diastolic murmur was identified, while the lesion was non-expandible during the performance of the Valsalva maneuver. No cervical lymphadenopathy was detected, as well.

Color Doppler ultrasonographic evaluation revealed the increased blood supply to the lobular lesion, with well-demarcated boundaries and increased flow velocity, findings indicative of a vascular lesion (Fig. 1). Chest radiograph was unremarkable.

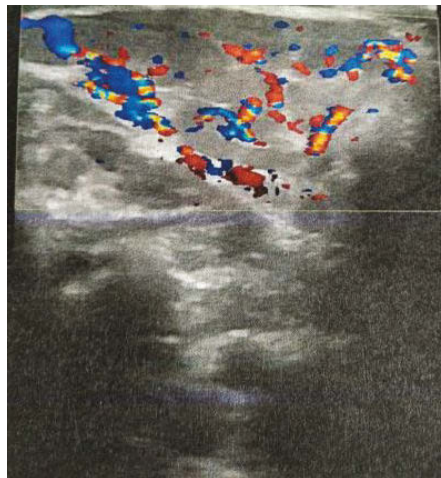


Fig. 1. Color Doppler ultrasonographic evaluation revealed the increased blood supply to the lobular lesion, with well-demarcated boundaries and increased flow velocity.

Elective surgical excision under general endotracheal anesthesia followed. Lesion was excised in healthy limits, while it was non-encapsulated (Fig. 2–4). No signs of iatrogenic injury of the common carotid artery, the internal jugular vein, the vagus nerve, the spinal accessory nerve and finally the phrenic nerve were present. Meticulous hemostasis and surgical wound closure without the application of a drainage followed.

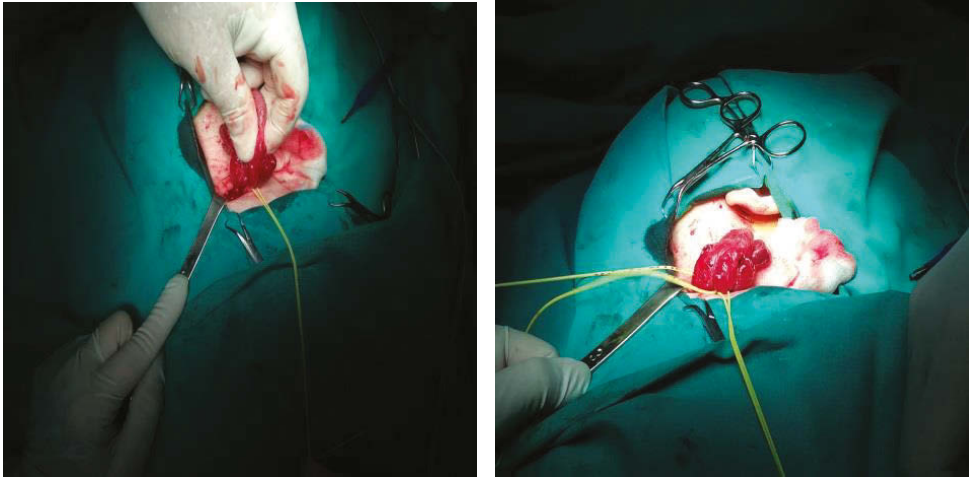


Fig. 2, 3. Excision of the non-encapsulated lesion.

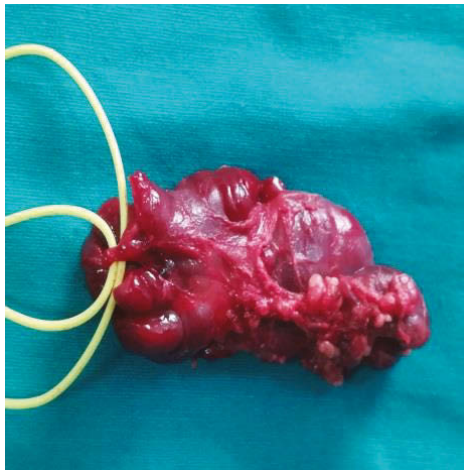


Fig. 4. Notice the completely excised multilobular lesion, with increased vascularization, as demonstrated by the multiple engorged veins on its surface.

Postoperative course was uneventful and the patient was discharged home on the second postoperative day in good general condition.

Histopathologic examination revealed the presence of an IMH, as shown in Fig. 5–6. Since then, patient is followed-up in our Outpatient Department on a 6-month basis without signs of recurrence, remaining asymptomatic.

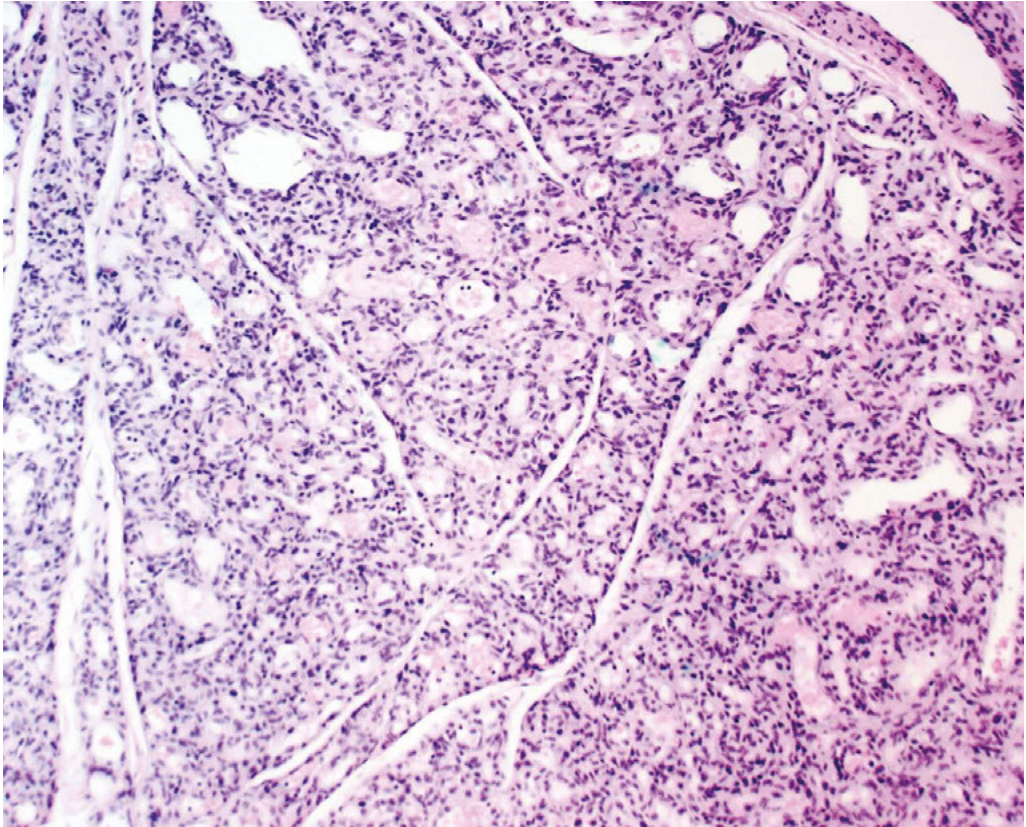


Fig. 5. The lesion is composed of vascular tissue in a roughly lobular arrangement. Numerous tiny vascular spaces are present (Haematoxylin & Eosin stain, 100 \times).

Discussion

IMHs frequently arise within the skeletal muscle of the trunk and extremities. The most usually involved muscle in the head and neck is the masseter and very few cases have been reported regarding the occurrence of these hemangiomas in the trapezius, sternocleidomastoid, temporalis, orbital and anterior scalene muscles [3, 4].

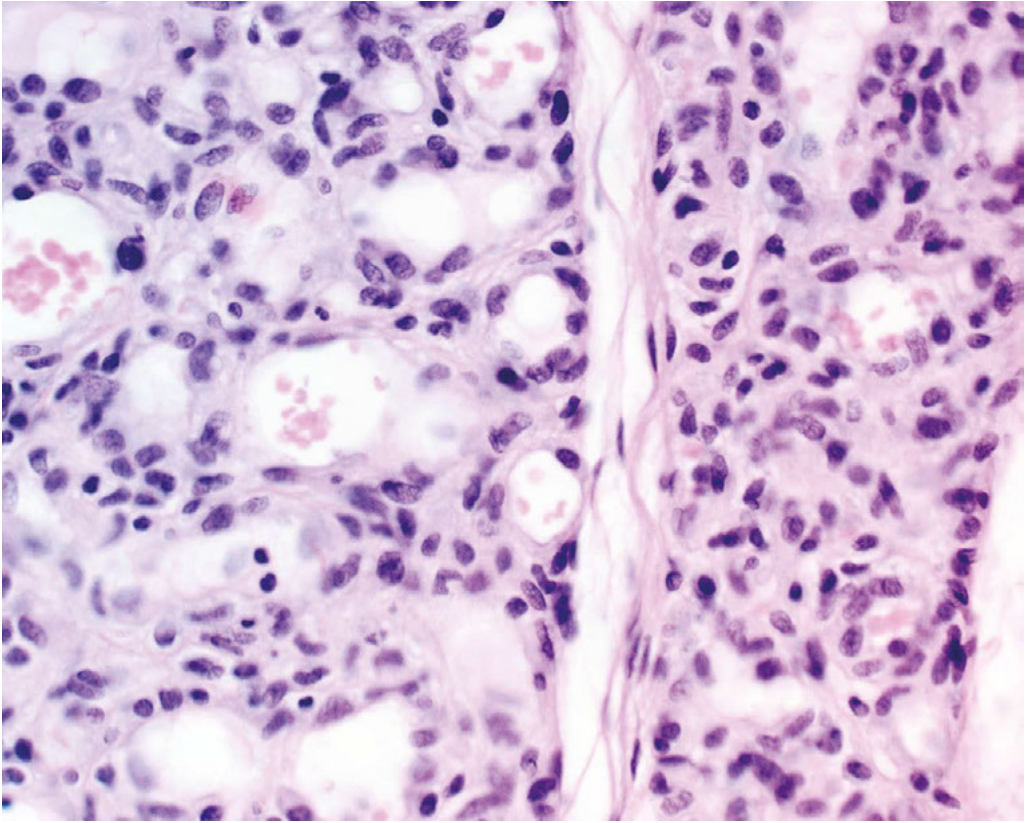


Fig. 6. Capillary hemangioma of infancy. Closely packed vascular channels lined by single layer endothelium. Intraluminal erythrocytes are visible. Lobules are partially separated by scant fibromuscular septa (Haematoxylin & Eosin stain, 400 \times).

IMHs rarely display any clinical symptoms or signs that reveal their vascular nature. There are no relevant vascular findings on examination due to the surrounding muscular fibrosis [5]. IMHs represent a challenging diagnosis due to the presence of limited signs in physical examination [1, 3, 5]. Overlying skin is usually normal, although there may be occasionally reddish blue discoloration [4, 5]. IMHs can be distinguished from other soft tissue lesions by the features of abundant vascularization and high blood flow velocity. Angiomyolipoma and vagal paraganglioma should always be included in differential diagnosis [6].

Definitive preoperative diagnosis is reached in less than 8% of all cases [1]. Ultrasonography appears to be extremely useful, in order to depict the increased vascularization of the lesion, and thus it should represent the first-line imaging modality [1, 3, 4]. The extent of the lesion is not always clinically apparent on physical examination and imaging modalities usually reveal the true extent of IMHs.

The diagnostic value of magnetic resonance imaging (MRI) in soft tissue tumors is undisputed [4, 6]. IMH features a hypointense signal voiding in T1-weighted images and hyperintense signal voiding in T2-weighted images and is also characterized by extensive enhancement in gadolinium-enhanced MRI [7]. We believe that the indication for performing an MRI is to highlight the anatomic correlation of the lesion with the surrounding anatomic structures. Thus, we consider that MRI has a low indication in most cases. Although calcification foci may also be observed in computed tomography (CT) scans of hemangiomas, MRI is superior to CT in the differential diagnosis of hemangiomas such as a posttraumatic IMH arising from scalene muscles in supraclavicular region [7].

Fine Needle Aspiration Cytology (FNAC) usually results in a misdiagnosis or no diagnosis due to obtaining an excessively bloody specimen [7]. There is a widespread perception that ultrasonography-guided core needle biopsy is contraindicated in hemangiomas due to a high risk of bleeding. On the contrary, IMHs contain variable amounts of nonvascular tissue such as fat, smooth muscle, and fibrous tissue. These nonvascular elements with compression by surrounding structures may prevent stagnation of blood within the tumor and may therefore reduce the possibility of bleeding during needle biopsy [8].

Unlike cutaneous and mucosal hemangiomas, IMH usually do not regress spontaneously [1–5]. Management of an IMH depends on its localization, extent, growth rate, accessibility, age of the patient, and cosmetic factors [3, 9].

Various treatment methods have been used for the treatment of hemangiomas such as intralesional steroid injection, sclerotherapy using ethanol or sodium tetradecyl sulphate, cryotherapy, vascular ligation, embolization, and surgical excision. Radiation therapy should be contraindicated for IMH due to its low curability and the risk of malignant transformation [2, 4, 9]. Treatment of choice for IMH includes excision of the lesion along with adequate surrounding normal tissue due to the lack of encapsulation and the infiltrative nature of the hemangioma into surrounding muscular tissue plane [3–5, 9]. However, the recurrence rate, ranging from 9 to 28%, has been reported following surgical excision [1, 3, 4]. To prevent massive intraoperative bleeding, Cho and colleagues have proposed the performance of an elective angiography and tumor embolization two days prior to elective surgical excision [7].

Conclusion

1. IMH does not follow the general rules of spontaneous regression, after the age of 6–12 months. On the contrary, there is an increasing trend over time.
2. Accurate preoperative diagnosis remains difficult and challenging.

3. Color Doppler ultrasonography is usually sufficient for the preoperative imaging of the lesion. MRI and FNAC indications are limited in our opinion.
4. Surgical excision in healthy limits is the treatment of choice.

Conflict of interest

None declared.

Funding source

None declared.

References

1. Biswas A.C., Chowdhuri N.H., Feroz A., et al.: Huge Intramuscular Cavernous Hemangioma involving SCM, Trapezius and scalene anterior: A Case Report. *Bangladesh J Otorhinolaryngol.* 2017; 23 (2): 203–207.
2. Liston R.: Case of erectile tumour in the popliteal space: removal. *Med Chir Trans.* 1843; 26: 120–132.
3. Parajuli R., Thapa S., Maharjan S.: Intramuscular Hemangioma of Thyrohyoid Muscle. *Case Rep Otolaryngol.* 2016; 2016: 7158691.
4. Giudice M., Piazza C., Bolzoni A., Peretti G.: Head and neck intramuscular haemangioma: report of two cases with unusual localization. *Eur Arch Otorhinolaryngol.* 2003; 260 (9): 498–501.
5. Zengin A.Z., Celenk P., Sumer A.P.: Intramuscular hemangioma presenting with multiple phleboliths: a case report. *Oral Surg Oral Med Oral Pathol Oral Radiol.* 2013; 115 (1): e32–e36.
6. Van Abel K.M., Carlson M.L., Janus J.R., et al.: Intramuscular hemangioma of the scalene musculature masquerading as a paraganglioma: a case series. *Am J Otolaryngol.* 2013; 34 (2): 158–162.
7. Cho J.K., Cha W., Sung M.W.: Intramuscular Hemangioma in the Anterior Scalene Muscle Diagnosed by Core Needle Biopsy. *Clin Exp Otorhinolaryngol.* 2015; 8 (3): 298–301.
8. Salzman R., Buchanan M.A., Berman L., Jani P.: Ultrasound-guided core-needle biopsy and magnetic resonance imaging in the accurate diagnosis of intramuscular haemangiomas of the head and neck. *J Laryngol Otol.* 2012; 126 (4): 391–394.
9. Nurlizams I., Kenalims M.S., Sani A.: Intramuscular haemangioma in the head and neck. *Med J Malaysia.* 2007; 62 (5): 409–410.