

DOI 10.24425/pjvs.2024.152955

Short communication

Innervation of the female internal genital organs in 12-week-old porcine foetuses

A. Franke-Radowiecka¹, N.V. Demus², A. Bossowska³

¹Department of Animal Anatomy,
University of Warmia and Mazury, Faculty of Veterinary Medicine,
Oczapowskiego 13, 10-719 Olsztyn, Poland

²Department of Normal and Pathological Morphology and Forensic Veterinary Medicine,
Stepan Gzhytskyi National University of Veterinary Medicine and Biotechnologies of Lviv,
Pekarska 50, Lviv, Ukraine

³Department of Human Physiology and Pathophysiology,
School of Medicine, University of Warmia and Mazury in Olsztyn, Warszawska 30, 10-082, Olsztyn, Poland

Correspondence to: A.Franke-Radowiecka, e-mail: ameliarf@uwm.edu.pl

Abstract

This is the first study aimed to investigate the innervation of the internal genital organs in 12-week-old female pig foetuses using single and double-labelling immunofluorescence methods. Immunostaining for protein gene product 9.5 (PGP, general neural marker) revealed that the most numerous PGP-positive nerve fibres were found in the mesenchyme of the uterovaginal canal height. Numerous nerve fibres were distributed in the uterine segment, less in the tubal segment of paramesonephric ducts (PD), and they usually occurred at the edge of the mesenchyme. A low number of fibres was visible in the developing ovary cortex and medulla. Many fibres expressed dopamine β -hydroxylase (D β H) and/or vesicular acetylcholine transporter (VAcHT) in the studied period. Most D β H-positive nerve fibres were observed in all segments of PD. VAcHT-positive were mainly distributed in the uterovaginal canal of PD. D β H/VAcHT-positive nerve fibres were observed in the mesenchyme of all segments of the PD, but they were most common in the uterovaginal canal and the uterine segment of PD. In the ovary, nerves were mainly D β H-positive and single nerve fibres containing VAcHT. Few D β H/VAcHT-positive nerve fibres were observed in the ovary.

Keywords: genital organs, innervation, peptide, prenatal development, pig



Introduction

Scarce attention in the literature is paid to non-infectious factors (Nogalski and Barański 2023), especially developmental abnormalities, which are difficult to recognise, rarely diagnosed, and have a huge impact on the fertility of female animals. Based on post-slaughter examinations of the reproductive organs of sows (Szostak et al. 2015), for example, the presence of infantilism of the uterus and ovaries or unicornuate uterus was found. These anomalies may have a genetic source, such as Klinefelter or Turner syndrome, but the source of many developmental abnormalities has not yet been investigated. Numerous studies have shown that the nervous system has a huge influence on the functioning of individual organs of the reproductive system. It is known that the uterus is one of the organs showing the greatest morphological and neural plasticity. The innervation of the pregnant and non-pregnant uterus differs in the density of nerve fibres present and their neurochemical coding (Podlasz and Wasowicz 2008). Research on the development of the innervation in female reproductive organs may provide a new perspective on reproductive challenges. This is particularly relevant because there is a close correlation between the development of these organs and their innervation (Keast et al. 2015). Therefore, there is a need for in-depth research on the development of innervation in various organs in the prenatal period. This area lacks sufficient data, particularly regarding the innervation of the reproductive system organs. Therefore, this study was aimed to investigate the innervation of the internal genital organs in a 12-week-old female pig foetus and presented the distribution of D β H (adrenergic marker) and/or VAcHT (cholinergic marker) in nerve fibres supplying the developing ovary, fallopian tube, and uterus in this period of prenatal development.

Materials and Methods

The porcine foetuses were obtained from a slaughterhouse. According to Polish law and the EU directive (No. 2010/63/EU), the experiments performed in the present study do not require the approval of the Ethics Committee. The current study used 12-week-old female foetuses ($n=5$, 17-17.5 cm in length). The age of the foetuses was marked according to the crown-rump length (CRL) method. CRL sets the distance from the top of the head of the foetus entering the lower limit of the rump (Evans and Sack 1973). The tissue fixation and all single and double immunohistochemical staining procedures, as well as controls applied in this study, were precisely described in the previous

articles (Franke-Radowiecka et al. 2019, Sienkiewicz 2022, Dudek et al. 2024). Forming internal genital organs were cut transversely or longitudinally into 12 μ m-thick cryostat sections and were labelled using primary antibodies against PGP 9.5, D β H and/or VAcHT and appropriate secondary antibodies (Table 1). The labelled sections were viewed under a Zeiss Axio-phot fluorescence microscope equipped with epifluorescence and an appropriate filter set for AlexaFluor 488 and AlexaFluor 555. The colocalisation patterns of the substances within the nerve elements were analysed by interchanging filters. The slides were evaluated by a team of two investigators, and each of them analysed the same number of sections (ten for each segment of paramesonephric ducts and ovary) in each animal studied. Microscopical analyses were conducted on the whole slide. The relative frequency of PGP-, D β H-, VAcHT-, and D β H/VAcHT-positive nerve fibres (Table 2) were defined with quantifiable criteria: many fibres +++++ (>40), moderate number ++++ (30-40), low number +++ (20-30), few ++ (10-20), single fibres + (<10). Images were recorded with a Zeiss LSM 700 confocal laser scanning microscope (Zeiss, Jena, Germany) and ZEN Software 2009. Channels were scanned consecutively to avoid cross-talk. A set of figures was prepared with CorelDRAW X7 ver. 17.6.0.1021 (Ottawa, ON, Canada) graphical software.

Results and Discussion

In female pigs, genital ridges, which are primordia of ovaries, appear in the fourth week of prenatal development. At the same time, genital ducts develop, i.e. the paramesonephric ducts (Müllerian ducts, PD) and they constitute the primordia of the fallopian tubes, uterus, and upper part of the vagina (Patten 1948).

In 12-week-old pig foetuses, the internal reproductive organs are represented by the uterovaginal canal (Fig. 1A, B), uterine (Fig. 1C) and tubal segments (Fig. 1D, E) of the PD and developing ovaries (Fig. 1F, G). Rudimentary mesonephroi were visible near the mesovarian border of the ovary. Immunostaining for PGP showed that nerve fibres were present in the mesenchyme of all PD sections during the examined period of prenatal development. The largest number of nerve fibres were observed in the uterovaginal canal of PD (Fig. 1A, B), where they were evenly distributed throughout the mesenchyme. Numerous fibres were observed in the uterine segments, less numerous in the tubal segments of PD, and in these parts, the nerves were mainly located at the edge of the mesenchyme. Generally, nerve fibres run in single strands or in bundles. Thicker nerve bundles were most

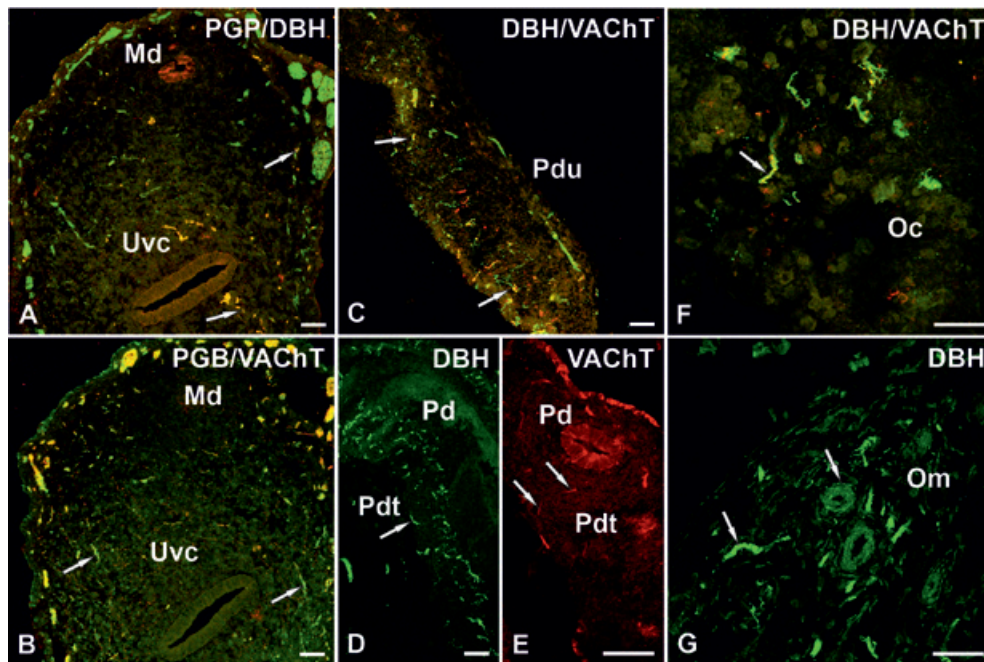


Fig. 1. Confocal laser scanning microscope image showing nerve fibres supplying different sections of paramesonephric ducts (PD) (A, B, C, D, E) and ovary (F, G) in 12-week-old porcine fetuses. The most numerous PGP-positive (A, B, green) nerve fibres were observed in the mesenchyme of the uterovaginal canal height (cross-section). A moderate number of DBH-positive (A, red) and many VACHT-positive (B, red) nerve terminals were visible in the uterovaginal canal of PD (A and B - consecutive section). A longitudinal section of the uterine segment of PD (C). A low number of D β H- (green) and a moderate number of VACHT-positive nerve fibres (red) were observed. A longitudinal section (D) and cross-section (E) of the tubal segment of PD. DBH-positive nerve fibres (D) were visible mainly on the edge of the mesenchyme. Few VACHT-positive nerve fibres (E) were observed, mainly in the mesenchyme. A cross-section of the ovary (F - cortex, G - medulla). Few D β H- (F, G, green) and single VACHT-positive fibres (F, red) were visible. Arrowhead - DBH/VACHT-positive nerve fibres. Md - mesonephric duct; Uvc - uterovaginal canal; Pdu - uterine segment of PD; Pdt - tubal segment of PD; Oc - ovary cortex; Om - ovary medulla

Table 1. List of primary antisera and secondary reagents used in the study.

Primary antibodies					
Antigen	Clonality	Host	Dilution	Company	Catalog no
PGP 9.5	monoclonal	mouse	1:400	Biorad	7864-2004
D β H	monoclonal	mouse	1:500	Millipore	MAB308
D β H	polyclonal	rabbit	1:500	Enzo	BML-DZ1020-0050
VACHT	polyclonal	rabbit	1:5000	Sigma	V5387
Secondary antibodies					
Antigen	Fluorophore	Host	Dilution	Company	Catalog no
Mouse IgG	Alexa 488	goat	1:1000	Invitrogen	A-11001
Rat IgG	Alexa 488	goat	1:1000	Invitrogen	A-11006
Rabbit IgG	Alexa 555	goat	1:1000	Invitrogen	A-21428

Table 2. Relative frequency of PGP-, D β H-, VACHT-, and D β H/VACHT-positive nerve fibres in 12-week-old porcine foetus developing internal genital organs.

	Paramesonephric ducts (PD)			Ovary	
	uterovaginal canal	uterine segment	tubal segment	cortex	medulla
PGP 9.5	+++++	++++	++++	+++	+++
D β H	+++	+++	+++	++	++
VACHT	++++	++++	++	+	+
D β H/VACHT	++	++	+	+	+

many fibres +++++, moderate number of fibres +++++, low number of fibres +++, few fibres ++, single fibres +

often found at the edge of the mesenchyme. Double immunohistochemical staining revealed that many D β H-positive nerve fibres were observed in each segment of PD, and many nerve terminals expressing VAcHt were visible in the uterovaginal canal of PD (Fig. 1B). The fewest VAcHt-positive nerve fibres were observed in tubal segments of PD (Fig. 1E). D β H/VAcHt-positive nerve fibres were found in the mesenchyme of all sections of the PD, but they were most common in the uterovaginal canal (Fig. 1A, B) and the uterine segments (Fig. 1C) of PD. In the uterine segments of PD D β H/VAcHt, nerve fibres were observed mainly at the edge of the mesenchyme.

The developing cortex (Fig. 1F) and the medulla (Fig. 1G) of the ovary were supplied with several short PGP-positive nerve fibres, or sometimes fibres running in bundles. In the ovarian medulla (Fig. 1G), they were most often observed around blood vessels or in the vessel wall. Generally, there were many D β H- and single VAcHt-positive fibres in the ovary, some of these fibres containing the two studied substances.

The results obtained in a 12-week-old pig foetus showed an increase in the innervation density in each PD section compared to week 10 of prenatal development. Nerve fibres were also observed in the ovary, which had not yet been noted in the previous period studied (Franke-Radowiecka et al. 2019). It is assumed that the development of organs occurs in parallel with the development of their innervation (Keast et al. 2015). The increase in the intensity of innervation of the developing uterus and fallopian tube in a pig foetus between weeks 10 and 12 of prenatal development may indicate progressive differentiation processes involving the formation of a layered structure of the uterus and fallopian tube wall. It was also observed that in 12-week-old pig foetuses, nerve fibres supplying PD segments contained both D β H and VAcHt, which was not observed in previous developmental stages in the pig (Franke-Radowiecka et al. 2019). The presence of D β H/VAcHt-positive nerve fibres in the mesenchyme of developing organs may indicate a progressive change in the phenotype of their nerve body cells in terms of the neurotransmitter synthesised (Yang et al. 2011). Previous studies have shown that between weeks 7 and 10 of porcine prenatal development, intensive development of the paracervical ganglion was observed, which is an important source of innervation of the uterus, the fallopian tube, and the ovary (Czaja et al. 2001, Podlasz and Wąsowicz 2008; Franke-Radowiecka 2020). It was also noted that between weeks 7 and 10 of prenatal development, the number of neurons in porcine paracervical ganglion increased by almost 1/3, and a significant increase in the number of cholinergic neurons compared to adrenergic ones was visible.

Moreover, in 10-week-old foetuses, the size of neurons in the ganglion varied greatly. Many of the neurons were D β H/VAcHt- positive, but in the developing uterus, such encoded nerve fibres were not present (Franke-Radowiecka et al. 2019). It follows that between weeks 7 and 10 of prenatal development in the pig, many changes primarily concern the ganglion but not the innervated tissue of the neurons of this ganglion. These changes were related to neuronal differentiation, apoptosis, and the parallel process of sacral neural crest cell migration (Yang et al. 2011, Wiese et al. 2017) or the transformation of the neurotransmitter phenotype. Due to neuronal apoptosis or lack of signal from the target tissue, many neuronal cell projections may fail to reach that tissue. This could explain the absence of D β H/VAcHt-positive fibres in the developing uterus of a 10-week-old pig foetus (Franke-Radowiecka et al. 2019). Between weeks 10 and 12 of prenatal development, further changes in the ganglion along with the elongation of nerve cells reaching various organs take place. These processes may occur simultaneously, resulting in a noticeable increase in innervation by week 12, especially at the edges of the mesenchyme in each PD segment. Some axons that have recently reached the organ wall may be phenotypically indeterminate, like their perikarya. This may explain the presence of D β H/VAcHt-positive nerve fibres in all segments of PD and in the ovary, as well as indicate intensive developmental processes of female internal genital organs. Discussing the developing innervation of the ovary is challenging due to the limited data available on this topic in the literature. However, it is already known that nerve fibres in this organ have been observed in 12-week-old porcine foetuses.

This study is the first to describe the development of adrenergic and cholinergic innervation in the developing female reproductive organs of pigs in the 12th week of foetal life. The rapid advancement of new medical fields, such as regenerative medicine and xenotransplantation (Wiater 2018), heavily relies on understanding neuroanatomy. Therefore, there is a pressing need for in-depth research on the development of organ innervation during prenatal life at every stage of development.

References

- Czaja K, Kaleczyc J, Pidsudko Z, Franke-Radowiecka A, Łakomy M (2001) Distribution of efferent neurons innervating the oviduct in the pig. *Folia Morphol* 60: 243-8.
- Dudek A, Sienkiewicz W, Lepiarczyk E, Kaleczyc J (2024) Immunohistochemical properties of motoneurons supplying the porcine trapezius muscle. *Pol J Vet Sci* 27: 75-84.
- Evans HE, Sack WO (1973) Prenatal Development of Domestic

- and Laboratory Mammals: Growth Curves, External Features and Selected References. *Anat Histol Embryol* 2: 11-45.
- Franke-Radowiecka A (2020) Paracervical ganglion in the female pig during prenatal development: morphology and immunohistochemical characteristics. *Histol Histopathol* 35: 1363-1377.
- Franke-Radowiecka A, Prozorowska E, Zalecki M, Jackowiak H, Kaleczyc J (2019) Innervation of internal female genital organs in the pig during prenatal development. *J Anat* 235: 1007-1017.
- Keast JR, Smith-Anttila CJ, Osborne PB (2015) Developing a functional urinary bladder: a neuronal context. *Front Cell Dev Biol* 3: 53.
- Nogalski Z, Barański W (2023) Pelvic dimensions and occurrence of dystocia in Black-and-White and Holstein-Friesian heifers. *Pol J Vet Sci* 26: 687-693.
- Patten BM (1948) *Embryology of the pig*, 3rd ed., Home Farm Books Publication.
- Podlasz P, Wasowicz K (2008) Neurochemical characteristics of paracervical ganglion in the pig. *Vet Med* 53: 135-146.
- Salogni C, Lazzaro M, Giacomini E, Giovannini S, Zanoni M, Giuliani M, Ruggeri J, Pozzi P, Pasquali P, Boniotti MB, Alborali GL (2016) Infectious agents identified in aborted swine fetuses in a high-density breeding area: a three-year study. *J Vet Diagn Invest* 28: 550-554.
- Sienkiewicz W, Klimczuk M, Gulbinowicz-Gowkielewicz M, Lepiarczyk E, Kaleczyc J (2022) Immunohistochemical characterization of nerve elements in porcine intrinsic laryngeal ganglia. *Pol J Vet Sci* 25: 325-334.
- Szostak B, Stasiak A, Gonet M (2015) Post-mortem evaluation of sows' reproductive organs – a valuable source of information about reproductive problems on pig farms (in Polish). *Przegląd hodowlany* 5: 25-27.
- Wiater J (2018) Will genetic engineering methods make xenotransplantation a reality? Transgenic pigs as potential organ donors for humans (in Polish). *Kosmos* 320: 541-553.
- Wiese CB, Deal KK, Ireland SJ, Cantrell VA, Sounthard-Smith EM (2017) Migration pathways of sacral neural crest during development of lower urogenital tract innervation. *Dev Biol* 429: 356-369.
- Young HM, Cane KN, Anderson CR (2011) Development of the autonomic nervous system: A comparative view. *Auton Neurosci* 165: 10-27.