

DOI 10.24425/pjvs.2025.154023

Original article

Efficacy of Patin (*Pangasius sp.*) gelatin on macrophage and fibroblast proliferation in traumatic ulcer rats

A. Puspa Sari¹, M. Prima Anugrah¹, R. Novita^{2,3}

¹ Faculty of Medicine, University of Sriwijaya, Jl. Dr Muhammad Ali, Sekip Jaya, Palembang, Indonesia

² Primatology Study Program, Graduate School of IPB University, Jl. Lodaya II No 5, Bogor, Indonesia

³ Research Center for Pharmaceutical Ingredients and Traditional Medicine, National Institute Research, and Innovation Agency, Jl. Raya Bogor-Jakarta KM. 46, Cibinong, Indonesia

Correspondence to: R. Novita, e-mail: rn_smile01@yahoo.com, tel.: +6281119333638

Abstract

Traumatic ulcers are oral mucosa lesions caused by thermal, mechanical, and chemical factors. Long-term topical medication use can lead to fungal resistance. Patin fish skin contains glycine and glutamic acid, which can enhance macrophage activation and fibroblast proliferation, aiding wound healing. This study aimed to determine the effect of Patin skin gelatin on increasing macrophages and fibroblasts and reducing the diameter of traumatic ulcers in Wistar rats.

An experimental laboratory study with a post-test-only control group design was conducted. Ulcers were induced on the labial mucosa of the mandible in rats using thermal induction. Treatments included a placebo gel and Patin skin gelatin at concentrations of 10%, 20%, and 30% for 7 days. Rats were euthanized on days 3, 5, and 7, and ulcerated mucosal tissue was biopsied to count macrophages and fibroblasts using an Olympus microscope.

Results showed significant macrophage and fibroblast count differences between the gelatin and placebo treatment groups. Patin skin gelatin at all concentrations increased the number of fibroblasts and decreased ulcer diameters significantly compared to the control group ($p \leq 0.05$). Patin skin gelatin effectively enhanced fibroblast cell proliferation and reduced ulcer size over the 7-day treatment period.

The 10% concentration of Patin skin gelatin showed the most significant increase in fibroblast count and the greatest reduction in ulcer diameter.

Keywords: fish, immunity, oral ulcers, Wistar rats



Introduction

Traumatic ulcers are wounds on the oral mucosa that affect the epithelium and generally extend to the propria epithelium (Wardani et al. 2017). This lesion had a clinical appearance characterized by yellowish fibrin exudate in the center with erythematous edges (Laskaris 2003). They are caused by physical, chemical, and thermal factors, with a global prevalence of about 4%, mainly due to mechanical trauma. These ulcers can reduce quality of life and interfere with eating, drinking, and speaking. Treatment includes anti-inflammatory, antibiotic, and analgesic therapies and dental health education to reduce inflammation (Amtha et al. 2017).

Gelatin, a biopolymer protein derived from animal collagen in the skin, bones, and connective tissue, promotes fibroblast growth and collagen synthesis, aiding wound healing (Sun et al. 2020). Typically sourced from cattle and pigs, there is a growing need for alternative sources of gelatin due to the increasing demand for halal products (Suptijah et al. 2018).

Patin fish, found in Southeast Asian waters with a tropical climate, is an alternative. It contains high levels of protein, essential amino acids, and non-essential amino acids, surpassing those in milk and meat proteins. Research indicates that Patin gelatin at 100% concentration contains amino acids such as glutamine, which promote fibroblast proliferation and collagen formation (Mardiyantoro and Andriani 2019). Additionally, gelatin exhibits good biocompatibility, biodegradability, hemostatic effects, and macrophage activity, accelerating granulation and epithelialization, which are beneficial for cell migration, adhesion, and growth during tissue regeneration (Wu et al. 2017).

Further studies show that fish skin gelatin, including salmon, contains the same 20 amino acids with variations in proline and hydroxyproline. Gelatin at 100% concentration can enhance fibroblast activity and wound vascularization (Zang et al. 2011b). It helps release the basic Fibroblast Growth Factor (bFGF), accelerating dermal tissue formation (Ito et al. 2013). Arginine in gelatin improves T-lymphocyte function and macrophage activation (Pratiwi et al. 2020). Fish collagen hydrolysate ointments at 10% concentration increase fibroblast growth factor-2 and fibroblast growth (Pratiwi et al. 2020).

Given these findings, this study will investigate the effect of gelatin from Patin fish on macrophage cell count, wound diameter reduction, and fibroblast activity in traumatic ulcer rats.

Materials and Methods

The use of animals was approved by the Animal Care and Use Committee of the Medicine Faculty of Sriwijaya University, number 113-2021.

Natural materials

Patin (*Pangasius sp.*) fish were delivered from Patin Breeding Farm, Kalidoni, Palembang, South Sumatra, Indonesia.

Preparation of Patin skin gelatin

Fresh Patin skin was cleaned of meat, scales, and outer layers containing fat. The skin was then washed with running water until it was clean. The skin was then soaked in cold water and stirred using a stirrer bar to remove fat, and the skin was then washed until clean. It was then cut into 2x2 cm pieces, these pieces were then soaked in an acidic solution, namely 5% HCl. Soaking was done for 12 hours. The soaked skin was weighed and washed with running water until the pH became neutral (6-7). It skin was then placed in a glass beaker, and distilled water was added with a ratio of 1:3 skin to distilled water. The skin was then extracted in a water bath at 80-90°C for 3 hours. The extract was filtered through a four-layered cotton cloth to remove impurities, and the obtained filtrate was measured. The filtrate was placed in a refrigerator at a temperature of 4-10°C for 10-12 hours until it formed a gel (See SF et al. 2010).

Preparation of Patin skin gelatin concentration

The concentration of Patin skin gelatin was prepared using the formula:

$$M1V1 = M2V2$$

V1: Volume of diluted Patin skin gelatin, M1: Concentration of Patin skin gelatin (100%), V2: Volume of water + Patin skin gelatin extract solution, M2: Concentration of Patin skin gelatin to be made

The gelatin was dissolved in water and heated, and Sodium CMC, glycerin, and propylene glycol were added. Stirring was performed until a gel formed, which was stored overnight at a temperature of 10-15°C.

Experimental design and animal subjects

This study used Wistar strain rats (*Rattus norvegicus*), male white rats aged 2-3 months, weighing 200-250 grams, in good health, indicated by active movement, clear non-red eyes, and thick white fur. An acclimatization of 2 weeks was provided to avoid fear and stress. The rats were divided into four groups, consisting

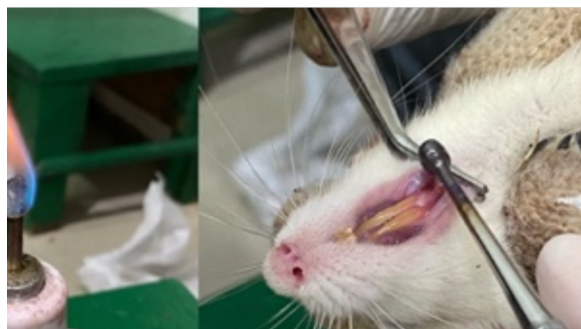

Fig. 1. Method for creating traumatic ulcers in rats using a heated burnisher.

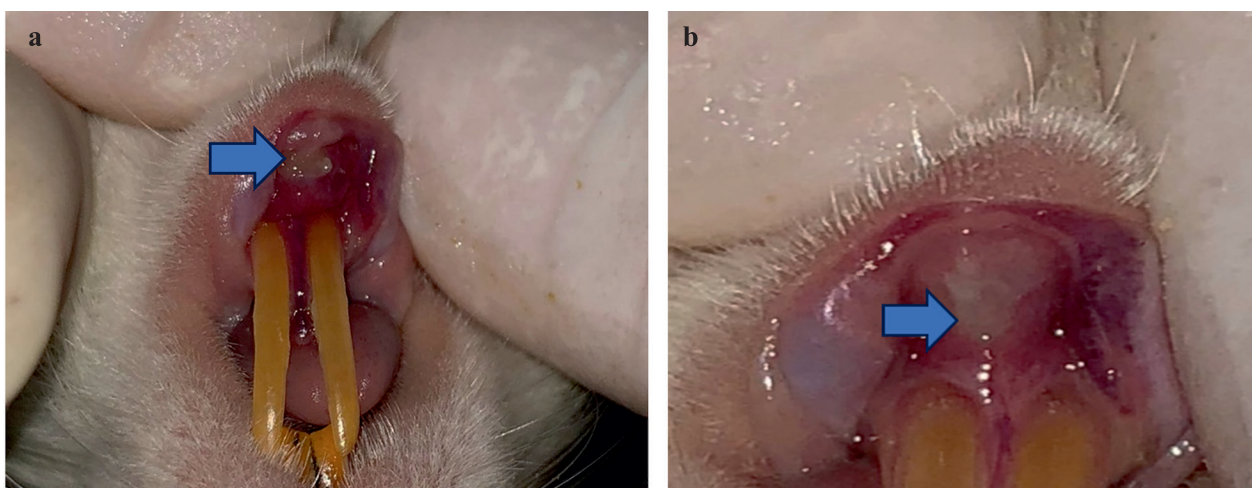


Fig. 2a. Traumatic ulcers in rats formed 24 hours after being induced with thermal trauma. Fig. 2b. Ulcer no longer visible on day 3 (rat treatment group).

of 6 rats each. The ulcer was made on the labial mucosa of the mandibular by thermal induction. The rats were anesthetized using Ket-A at a dose of 0.2 mg/kg BW intraperitoneally before the thermal induction. The traumatic ulcer was created after the rats were anesthetized (approximately 5 minutes after the ketamine injection). The labial mucosa was then given a topical anesthetic with 20% benzocaine and left for 5 minutes to produce a numbing effect. A 2 mm-sized ball burnisher was heated over a Bunsen burner until it turned red for 60 seconds; the ulcer was created on the labial mucosa by gently applying the ball burnisher to the lower lip labial mucosa of the rat for 1 second without pressure, with a depth limit of no more than 1 mm (Fig. 1). The area injured with the ball burnisher was left for 24 hours until it became a traumatic ulcer.

Groups A, B, and C consecutively received Patin skin gelatin with 10%, 20%, and 30% concentrations, and Group D received a placebo. The gelatin was applied to the ulcer surface slowly and evenly using a cotton bud. The gelatin was applied three times a day for seven consecutive days. The rats were terminated by injection with ketamine at a dose of 80 mg/kg BW intra-muscular. Specimens were made by cutting the rat's lower lip labial mucosa tissue into 5x5 mm pieces

with a 2-3 mm thickness. The tissues were fixed with 10% buffered neutral formaldehyde. Tissue staining was performed using hematoxylin-eosin. Macrophages and fibroblasts were observed using a microscope with 100x and 400x magnification from three different viewpoints (Mardiyantoro and Andriani 2019).

Statistical analysis

The data were analyzed to determine the effectiveness of Patin skin gelatin in accelerating the healing process of traumatic ulcers in white rats using a two-way ANOVA statistical test. The Tukey post hoc test was then used to compare the means between groups. Data analysis was conducted using SPSS version 25.

Results

The traumatic ulcer formed 24 hours after being induced with thermal trauma can be seen in Fig. 2a, and, by day 3, the ulcer was no longer visible in the treatment group (Fig. 2b). Data on the number of macrophages were obtained from the treatment groups of 10%, 20%, and 30% Patin skin gelatin. The placebo gel group from the observation of macrophage cells

Table 1. Average number of macrophages in the rat treatment and control groups on days 3, 5, and 7.

Groups	Average number of macrophages		
	Day 3	Day 5	Day 7
Patin skin gelatin 10%	3.3	1.6	0.6
	2.6	1.0	0.3
Patin skin gelatin 20%	2.0	0.6	0.3
	2.0	0.3	0.3
Patin skin gelatin 30%	1.0	0.6	0.3
	1.0	0.3	0.3
Control (Gel Placebo)	3.0	2.6	1.6
	2.0	1.0	0.6

Table 2. Average number of fibroblasts in the rat treatment and control groups on days 3, 5, and 7.

Group	Average number of fibroblast		
	Day 3	Day 5	Day 7
Patin skin gelatin 10%	51.33	87.00	43.00
	51.33	87.00	47.66
Patin skin gelatin 20%	84.66	79.00	58.33
	84.00	80.33	58.33
Patin skin gelatin 30%	87.00	87.33	47.00
	87.00	83.33	47.66
Control (Gel Placebo)	64.66	64.33	80.00
	63.00	64.33	79.66

in the traumatic ulcers of the lower lip labial mucosa on the third day, and histological examination was performed using an Olympus microscope at a magnification of 400x and observed with three fields of view as shown in Fig. 1. Macrophage cells appeared to be sized 10-80 μm , with oval-shaped nuclei, cytoplasm containing granules, endocytic vesicles, mitochondria, lysosomes, and with pseudopodia on the cell surface.

The average number of macrophages on the third day was obtained at a concentration of 10% Patin skin gelatin. In the control group, the lowest average was obtained at a concentration of 30% Patin skin gelatin. The average fibroblast results can be seen in Table 1 after treatment with 10%, 20%, and 30% Patin skin gelatin on the third, fifth, and seventh days for traumatic ulcers of the labial mandibular mucosa in rats. The Friedman test results yielded a value of $p < 0.05$, indicating a significant difference between the treatment groups and concentrations of macrophage cells.

Data on the number of fibroblasts were obtained from the treatment groups with Patin skin gelatin concentrations of 10%, 20%, and 30% and the placebo gel. Observation of fibroblast cells in the traumatic ulceration of the lower lip mucosa rats were conducted on the third, fifth, and seventh days, and histological examination was performed using an Olympus microscope at 400x magnification with three fields of view. Fibroblast cells appeared as significant, flattened, branched cells,

shaped like an oval or elongated nucleus in the middle, as seen in Fig. 2.

On the third day, the highest average number of fibroblasts was observed in the Patin skin gelatin 30% treatment group, and the lowest average number of fibroblasts was observed in the 10% treatment group. The highest number of fibroblasts on the fifth day was observed in the 20% and 30% concentration groups, while the lowest number was found in the control group. There was a decrease in the average number of fibroblasts on the seventh day compared to the fifth day for the 10%, 20%, and 30% concentrations. In the control group, there was an increase in the number of fibroblasts compared to the third and fifth treatment days. The average number of fibroblasts on the seventh day at 30% concentration showed an increase compared to the fifth day and a decrease compared to the seventh day.

The average number of fibroblasts on the seventh day decreased at concentrations of 10%, 20%, and 30% compared to the fifth day. The average number of fibroblasts in the control group increased compared to the treatments on the third and fifth days. The average number of fibroblasts obtained can be seen in Table 2 after treatment with Patin skin gelatin at concentrations of 10%, 20%, and 30% on the third, fifth, and seventh days for traumatic ulcers of the lower lip mucosa of rats.

The results of the two-way ANOVA test yielded

Table 3. Traumatic ulcer diameter during treatment.

Group	Average diameter of fibroblast		
	Day 3	Day 5	Day 7
Patin skin gelatin 10%	51.33	87.00	43.00
	51.33	87.00	47.66
Patin skin gelatin 20%	84.66	79.00	58.33
	84.00	80.33	58.33
Patin skin gelatin 30%	87.00	87.33	47.00
	87.00	83.33	47.66
Control (GelPlacebo)	64.66	64.33	80.00
	63.00	64.33	79.66

a p-value <0.05, indicating significant differences among the groups in the treatment between concentration, treatment days, and concentration with treatment days. The two-way ANOVA results showed a p-value <0.05, indicating a significant difference in patin fish skin gelatin treatment on fibroblasts based on concentration, treatment days, and concentration with treatment days. Subsequently, a post-hoc test was conducted to determine which groups had significant differences. The post-hoc test results showed that patin fish skin gelatin with concentrations of 10%, 20%, and 30% had substantial differences compared to the control group.

A comparison between concentration groups revealed that patin fish skin gelatin with concentrations of 20% and 30% did not have significant differences. After treatment with patin fish skin gelatin concentrations of 10%, 20%, and 30% on the third, fifth, and seventh days for traumatic ulcers on the mandibular labial mucosa of rats, measurements were taken of the ulcer diameter as shown in Table 3. After measurements on the third, fifth, and seventh treatment days, the most minor ulcer diameter was found in the group treated with a 30% concentration of Patin skin gelatin.

Discussion

It was found that the highest average number of macrophages was in the group treated with 10% Patin skin gelatin concentration, and the control group was based on the average macrophage results on the third, fifth, and seventh days. Meanwhile, the lowest average was in the group treated with 30% Patin skin gelatin concentration.

Normality tests were conducted using the Shapiro-Wilk test, and there were some data with a significance of $p < 0.05$ after obtaining the average macrophage count, so homogeneity tests could not proceed. Therefore, non-parametric tests were conducted using the Friedman test. In the Friedman test, a significance value of <0.05 was found, indicating differences between

macrophage groups, but differences between concentration and treatment days were not observed.

The results of the average fibroblast test showed that the highest average number of fibroblast cells was in the group treated with 30% Patin skin gelatin concentration, and the lowest was in the group treated with 10% Patin skin gelatin concentration. Subsequently, normality and homogeneity tests were conducted to determine whether the data were normally distributed; after normality and homogeneity tests were conducted, a two-way ANOVA test was performed, and differences were found between concentration, treatment days, and concentration with treatment days. Therefore, treatment group comparisons were continued using post-hoc tests. Post-hoc tests in this study showed that Patin skin gelatin concentrations of 10%, 20%, and 30% had significant differences compared to the control group, which only received a placebo. The 20% and 30% Patin skin gelatin groups showed no significant differences when comparing treatment concentration groups.

Macrophages can accelerate the inflammatory phase into the proliferation phase in healing traumatic ulcers, with macrophages appearing 48-72 hours after injury (Rosada et al. 2020). During inflammation, macrophages produce proinflammatory cytokines, including TNF- α , IL-1, and IL-6. TNF- α induces endothelial and leukocyte activation at the infection site, while IL-1 and IL-6 induce hepatocytes to release acute-phase proteins such as kaolin and pentraxin (Siregar 2019). This is consistent with research conducted by Violeta et al. (2020), which states that macrophages appear 24-96 hours after ulcer formation and produce Growth Factor- β (GF- β), Vascular Endothelial Growth Factor (VEGF), and Fibroblast Growth Factor (FGF), initiating the next phase, the proliferation phase (Violeta and Hartomo 2020).

Patin gelatin contains the amino acid glycine. Glycine is a non-essential amino acid that can accelerate wound healing by triggering macrophages and platelets to secrete growth factors such as Platelet-

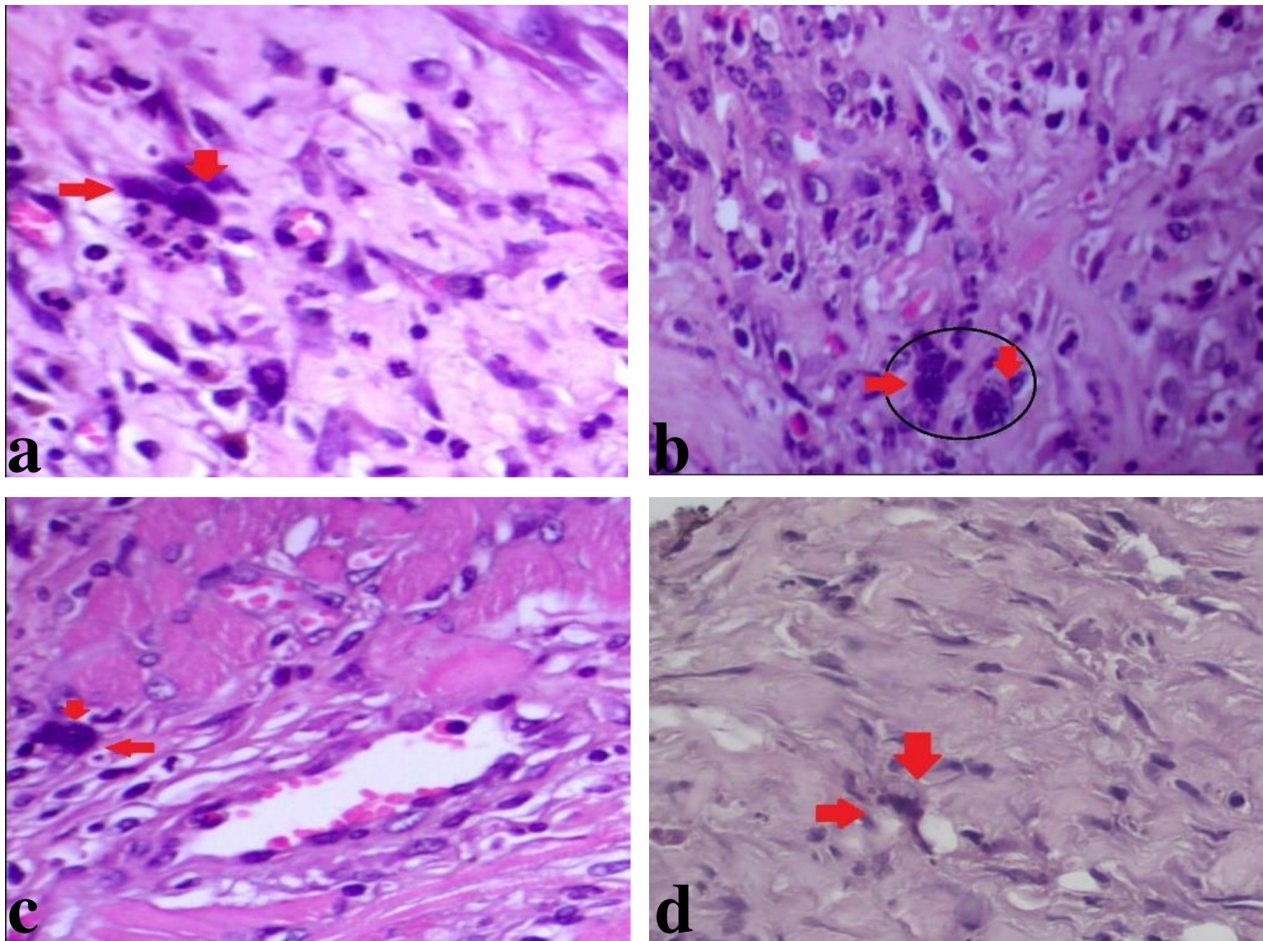


Fig. 3. Representation of hematoxylin and eosin (HE) staining rat of macrophage cells with x400 magnification on day 3 (a) placebo gel, (b) 10% Patin skin gelatin, (c) 20% patin skin gelatin, (d) 30% Patin skin gelatin. Macrophage cells measuring 10–80 μm are observed, with an oval-shaped nucleus, cytoplasm containing granules, endocytic vesicles, mitochondria, and lysosomes, as well as having pseudopodia on the cell surface, indicated by the red arrow.

-Derived Growth Factor (PDGF), Fibroblast Growth Factor (FGF), and Transforming Growth Factor- β (TGF- β) (Fatimatuzzahro et al. 2021). This is consistent with the results of the study, where the groups treated with 10% *Pangasius Patin* skin gelatin and the control group were still in the inflammation phase, while the group treated with 30% *Pangasius Patin* skin gelatin had already progressed to the proliferation phase. This is consistent with the research by Hendrik et al. (2017), stating that macrophages induce fibroblast proliferation and extracellular matrix production on the second day. The decrease in the number of macrophages on the fifth day indicates that inflammation has significantly decreased, and the wound will be filled with tissue proliferation.

Fibroblasts play an essential role in cell regeneration in the proliferation phase of traumatic ulcers. This is consistent with the research by, stating that Patin gelatin can increase the number of fibroblasts in post-extraction sockets from the third day (Mardiyantoro and Andriani 2019). Lutfiana et al. (2020) also showed an increase in fibroblast cells in second-degree burn wound

areas treated with 10% fish collagen hydrolysate ointment (Pratiwi et al. 2020).

Gelatin has antimicrobial properties. Thus, it can inhibit wound bacterial growth. Patin gelatin contains the amino acid glutamine. Glutamine plays a role in increasing collagen synthesis, thereby increasing the proliferation of fibroblast cells, leading to an increase in the number of fibroblast cells in wound tissue. This is consistent with the research conducted by, stating that the amino acid content in gelatin is effective in wound healing (Zhang et al. 2011a).

Rats and humans have differences in wound healing regarding morphology and immunology.

Humans have thicker epidermises than rats and have epidermal ridges, whereas rats do not. In human granulation tissue forms wound closure, while it is through a contraction in rats. Immunologically, humans have 50-70% neutrophils and 30-50% lymphocytes, while rats have 10-25% neutrophils and 75-90% lymphocytes. Additionally, humans have IL-8 and monocyte chemoattractants (Zomer HD 2018).

The diameter measurements during the treatment

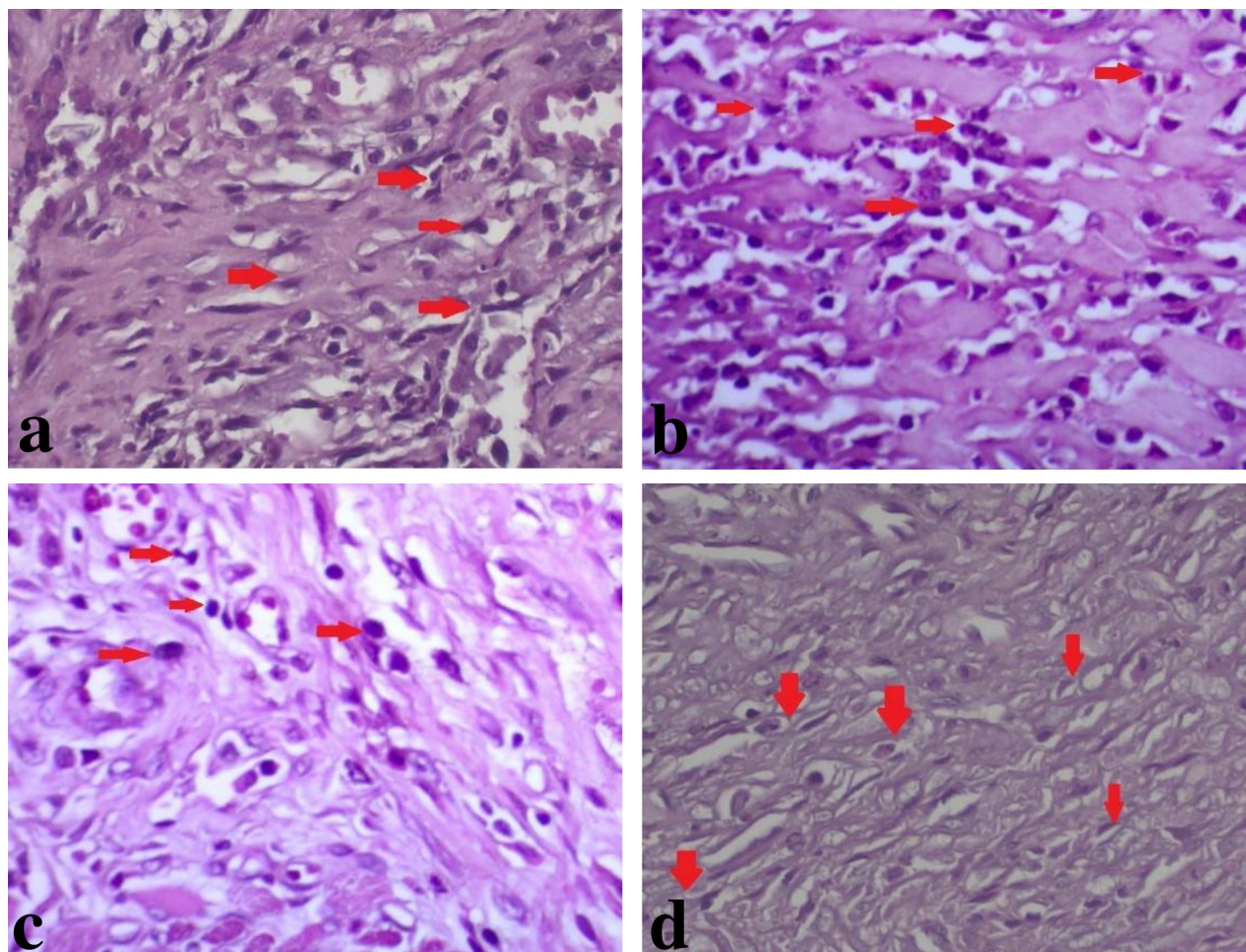


Fig. 4. Histopathological staining of HE fibroblast cells at x400 magnifications on day 7 (a) placebo gel, (b) 10% Patin skin gelatin, (c) 20% Patin skin gelatin, (d) 30% Patin skin gelatin. The average number of fibroblasts on the seventh day decreased at concentrations of 10%, 20%, and 30% compared to the fifth day. The red arrow indicates fibroblasts. The appearance of fibroblast cells shows large, flat, and branched cells, spindle-shaped with an oval or elongated nucleus in the center.

on the third, fifth, and seventh days in the group treated with a 30% concentration of Patin skin gelatin also showed the most minor diameter compared to the group treated with a 10%, and 20% concentration of Patin skin gelatin. The difference in the effect between 20% and 30% Patin skin gelatin concentrations could be due to uncontrolled factors, including the rat's immune response and stress. Stress can reduce proinflammatory cytokines such as IL-1 β , IL-6, and TNF- α at the wound site, thereby reducing fibroblast proliferation and slowing ulcer healing (Guo and DiPietro 2010, Gouin and Kiecolt-Glaser 2011).

This condition indicates that Patin skin gelatin could be an alternative for healing traumatic ulcers. This is in line with the research by Zhaofeng et al. (2011), which stated that the amino acid content in gelatin can aid in wound healing. Further research is needed to compare Patin skin gelatin with positive control, such as sodium hyaluronate gel for traumatic ulcers, the gold standard drug for traumatic ulcers. Further research is needed on the bioactive compounds

in Patin skin gelatin, which may also have wound-healing effects. This is crucial for developing Patin skin gelatin clinical research to treat traumatic ulcers.

Limitations in this study include the absence of macrophages on the first and second days, whereas, in normal conditions, macrophages would appear 24 to 72 hours after ulcer formation. In this study, macrophages were observed on the third, fifth, and seventh days. Thus, no increase in the number of macrophage cells was found. Further research is needed to investigate the rise in fibroblasts in rat traumatic ulcers treated with Patin skin gelatin compared to commonly used ulcer treatment medications.

References

- Amtha R, Marcia M, Aninda A (2017) Thrush plasters effectively accelerate the healing of recurrent aphthous stomatitis and traumatic ulcers. *Maj Kedokt Gigi Indones* 3: 69. <https://doi.org/10.22146/majkedgiind.22097>
- Fatimatuzahro N, Pujiastuti P, Alicia RS (2021) Potential of 5%

- Argiope modesta spiders cocoon extract gel on the fibroblasts number and collagen density. *J Kedokt Gigi Univ Padjadjaran* 33: 233.
- Gouin JP, Kiecolt-Glaser JK (2011) The Impact of Psychological Stress on Wound Healing: Methods and Mechanisms. *Immunol Allergy Clin North Am* 31: 81-93.
- Guo S, DiPietro LA (2010) Critical review in oral biology & medicine: Factors affecting wound healing. *J Dent Res* 89: 219-229.
- Ito R, Morimoto N, Pham LH, Taira T, Kawai K, Suzuki S (2013) Efficacy of the controlled release of concentrated platelet lysate from a collagen gelatin scaffold for dermis-like tissue regeneration. *Tissue Eng Part A* 19: 1398-1405.
- Laskaris G (2003) *Color Atlas of Oral Diseases*. 3rd edition. Thieme: New York
- Mardiyantoro F, Andriani D (2019) The effect of Patin (Pangasius Djambal) gelatin on the number of fibroblasts in wounds after tooth extraction in Rats (*Rattus norvegicus*). [article in Indonesian]. *Odonto Dent J* 6: 1-5.
- Pratiwi L, Prasetyawan S, Vidiastuti D (2020) The Effect of Hydrolyzed Fish Collagen Ointment to Healing Burns Level IIB by Fibroblast Growth Factor 2 (FGF-2) and Fibroblast in Rats (*Rattus norvegicus*). *MKH* 31: 52. [Available at <https://e-journal.unair.ac.id/MKH/index>]
- Rosada A, Mujayanto R, Poetri AR (2020) Salam Leaf Extract in Increasing Fibroblast Growth Factor Expression in Traumatic Ulcers of the Oral Cavity. *Odonto in Dent J* 7: 90. <http://dx.doi.org/10.30659/odj.7.2.90-96>
- See SF, Hong PK, Ng KL, Wan Aida, and Babji AS (2010) Physicochemical properties of gelatins extracted from skins of different freshwater fish species. *Int Food Res J* 17: 809-816
- Siregar FM (2019) Immunosenescence : Aging of Macrophage Cells. [article in Indonesian]. *J Ilmu Kedokt* 13: 14.
- Sun M, Xie Q, Cai X, Liu Z, Wang Y, Dong X, Xu Y (2020) Preparation and characterization of epigallocatechin gallate, ascorbic acid, gelatin, and chitosan nanoparticles and their beneficial effect on wound healing of diabetic mice. *Int J Biol Macromol* 148: 777-784.
- Suptijah P, Indriani D, Wardoyo SE (2018) Isolation and Characterization of Collagen from the Skin of Catfish (*Pangasius sp.*). *J Sains Nat* 8: 8.
- Violeta BV, Hartomo BT (2020) Management of Traumatic Ulcer Care in Traumatic Occlusion Patients: Case Report. [article in Indonesian]. *e-GiGi*. 8: 86-92.
- Wardani RP, Kholifa M, Yuletnawati SE (2017) Effect of Lime Peel Ethanol Extract (*Citrus aurantifolia (Christm.) Swingle*) on Traumatic Ulcer Healing in *Rattus norvegicus* Wistar Strain. *JIKG* 1: 23-27. [<https://journals.ums.ac.id/index.php/jikg/article/view/4149>]
- Wu S, Deng L, Hsia H, Xu K, He Y, Huang Q, Peng Y, Zhou Z, Peng C (2017) Evaluation of gelatin-hyaluronic acid composite hydrogels for accelerating wound healing. *J Biomater Appl* 31: 1380-1390.
- Zhang Z, Zhao M, Wang J, Ding Y, Dai X, Li Y (2011a) Oral administration of skin gelatin isolated from Chum salmon (*Oncorhynchus keta*) enhances wound healing in diabetic rats. *Mar Drugs* 9: 696-711.
- Zhang Z, Wang J, Ding Y, Dai X, Li Y (2011b) Oral administration of marine collagen peptides from Chum Salmon skin enhances cutaneous wound healing and angiogenesis in rats. *J Sci Food Agric* 91: 2173-2179.
- Zomer HD, Trentin GA (2018) Skin wound healing in humans and mice: Challenges in translational research. *J Dermatol Sci* 90: 3-12.