

DOI 10.2478/v10181-012-0110-7

Original article

Overexpression of aldolase A and cytokeratin 19 in ovine pulmonary adenocarcinoma

A. Kycko, M. ReichertDepartment of Pathology, National Veterinary Research Institute,
Al. Partyzantow 57, 24-100 Pulawy, Poland

Abstract

Ovine pulmonary adenocarcinoma (OPA) is a transmissible lung cancer of sheep caused by jaagsiekte sheep retrovirus (JSRV). In the present study the protein profiles of five neoplastic and three non-neoplastic sheep lung tissues were examined for the identification of proteins overexpressed in ovine pulmonary adenocarcinoma. Lung sections of the experimental group of sheep were collected during necropsies for proteomic and immunohistochemical examination. Two dimensional electrophoresis (2DE) was performed using gel strips with immobilized pH gradient 3-10. As a result of 2DE gel analysis 14 spots characterized by over 2-fold higher expression in tumour proteomes were selected for mass spectrometry. In eleven spots more than one polypeptide was identified indicating overlapping of proteins in gels. In two spots demonstrating over 3-fold higher expression in OPA proteomes, single proteins: cytokeratin 19 (CK19) and aldolase A were identified. Immunohistochemical studies revealed that CK19 and aldolase A were expressed in the cytoplasm of epithelial cells of bronchioles in non-neoplastic lung sections, as well as epithelial cells of bronchioles and neoplastic cells in lung sections of OPA affected sheep. The results indicate that the overexpression of the two proteins reflects the presence of neoplastic cells in the lungs of OPA affected sheep.

Key words: ovine pulmonary adenocarcinoma, cytokeratin 19, aldolase A, proteomic, immunohistochemistry

Introduction

Ovine pulmonary adenocarcinoma (OPA) is a transmissible lung cancer of sheep caused by jaagsiekte sheep retrovirus (JSRV). The virus induces neoplastic transformation of alveolar type II pneumocytes and Clara cells in sheep lung (Rosadio et al. 1988, Platt et al. 2002). According to the OIE (World Organization for Animal Health, Handistatus II), the disease is present worldwide, except of Australia, New Zealand and Iceland. OPA has a long incubation period, which may vary from 3 weeks in experimentally infected

lambs to over 2 years in adult sheep. The clinical signs are those of respiratory tract distress reflecting the extent of tumour development in the lungs. Frothy mucoid fluid accumulates within the respiratory tract and may be seen leaking out from the nostrils after raising the back and lowering the head of the sheep ("the wheelbarrow test") (Sharp and DeMartini 2003, York and Querat 2003). The infection is persistent and no immune response has been detected, apparently due to the presence of similar endogenous retroviruses in the sheep genome (DeMartini et al. 2003). Diagnosis of OPA is usually possible only in the late

stage of the disease and the neoplastic growth in the lungs may be not recognized until post-mortem examination. Diagnosis is based on histological examination of the lungs and PCR methods applied to detect the virus in infected cells (De Las Heras et al. 2005). OPA has been found to be clinically and histologically similar to human lung adenocarcinomas of mixed subtypes (Palmarini and Fan 2001, De las Heras et al. 2003, Mornex et al. 2003). The possibility of experimental induction of the tumour in animals makes it a good model for the study of oncogenesis as well as possibilities for diagnostics and therapy of lung tumors. Proteomic methods such as two dimensional electrophoresis and mass spectrometry are widely used in human medicine to determine the differential expression of proteins in neoplastic tissues, which may lead to the discovery of protein markers or targets for specific anti-tumour therapy (Srinivas et al. 2002, Granville and Dennis 2005).

In the present study the protein expression profiles (proteomes) of neoplastic and non-neoplastic sheep lung tissues were examined for the identification of proteins differentially expressed in ovine pulmonary adenocarcinoma affected lung.

Materials and Methods

Tissue samples. The examined material consisted of lung tissue sections collected post mortem from an experimental group of 8 sheep. The samples of lung adenocarcinoma originated from 5 sheep which had been experimentally inoculated with JSRV, as described earlier (Kycko and Reichert 2010). Non-tumour lung tissue samples were collected from the three remaining, non-infected animals. Each tissue sample was divided and one part of the tissue was fixed in 10% buffered formalin for histopathological and immunohistochemical examination, while the remaining part was frozen at -80°C for proteomic study.

Two-dimensional electrophoresis. Frozen lung tissue sections were lysed in appropriate lysis buffer containing 9 M urea, 4% CHAPS, 50 mM dithiothreitol (DTT), 0.001% protease inhibitor cocktail (Sigma Aldrich), and 0.2% Bio-Lyte 3/10 ampholytes (BioRad, USA). For the isoelectrofocusing 17 cm gel strips with immobilized pH gradient 3-10 (BioRad) were used. Two dimensional electrophoresis was performed, in two repetitions, as described earlier (Kycko and Reichert 2008). The resulting gels were visualised using silver staining then scanned and analysed using PDQuest software (BioRad). The gels intended for mass spectrometry were stained with Coomassie Blue (Sigma Aldrich). The gels were compared to each other for differences in size and intensity of visualized

protein spots. Spots presenting over 2-fold higher expression in all samples of OPA in comparison to non-tumour one, were manually excised and submitted for analysis and protein identification using mass spectrometry with MALDI-TOF at the Institute of Biochemistry and Biophysics in Warsaw (IBB, Warsaw).

Histopathology. For histopathological examination, the collected tissues fixed in 10% buffered formalin were processed to paraffin wax routinely. Thin sections (5 μm) were cut from paraffin blocks and stained with haematoxylin and eosin (HE).

Immunohistochemistry. The study was performed using a labelled streptavidin-biotin visualization system (LSAB). The following commercial antibodies against cytokeratin 19 and aldolase A, diluted in antibody diluent (Dako, USA), were used as the primary antibodies: ALDOA/Aldolase Goat anti-Rabbit Polyclonal (10 mg/ml, LS-C34940 Life Span Biosciences, dilution 1:800), and Cytokeratin 19 (312-335) Mouse anti-Human Monoclonal (0.1 mg/ml, AM08421PU-N, Acris Antibodies, dilution 1:80).

Endogenous peroxidase activity was blocked by incubating the slides in 3% hydrogen peroxide in water for 10 min at room temperature. The sections were then boiled in 10 mM citrate buffer (pH 6) for 5 min. The primary antibodies were then applied and left for incubation overnight at 4°C in a moist chamber. Staining was performed using a labelled streptavidin-biotin visualization system – HRP/LSAB+ kit (Dako, DE). For visualization, 3,3'-diaminobenzidine-4HCl (Dako, DE) was used. Sections were counterstained with Mayer's haematoxylin, dehydrated and mounted. Negative controls consisted of tissue sections incubated with TBS (Tris buffered saline) instead of primary antibody.

Results

The presence of OPA in lung tissue samples of JSRV inoculated animals was confirmed by histopathological examination. In one non-infected sheep, inflammatory cells were observed infiltrating the lung parenchyma.

Two-dimensional electrophoresis allowed for separation of extracted proteins according to their isoelectric points (pI) in the first dimension, and molecular mass in the second one. For 2DE gel analysis, PDQuest 7.2.0 was used to locate and quantify protein spots in gels containing tumour and non-tumour samples. After background elimination and gel normalization, the gels were matched and compared one to another. The main difference between protein profiles obtained from normal lung tissue and cancerous

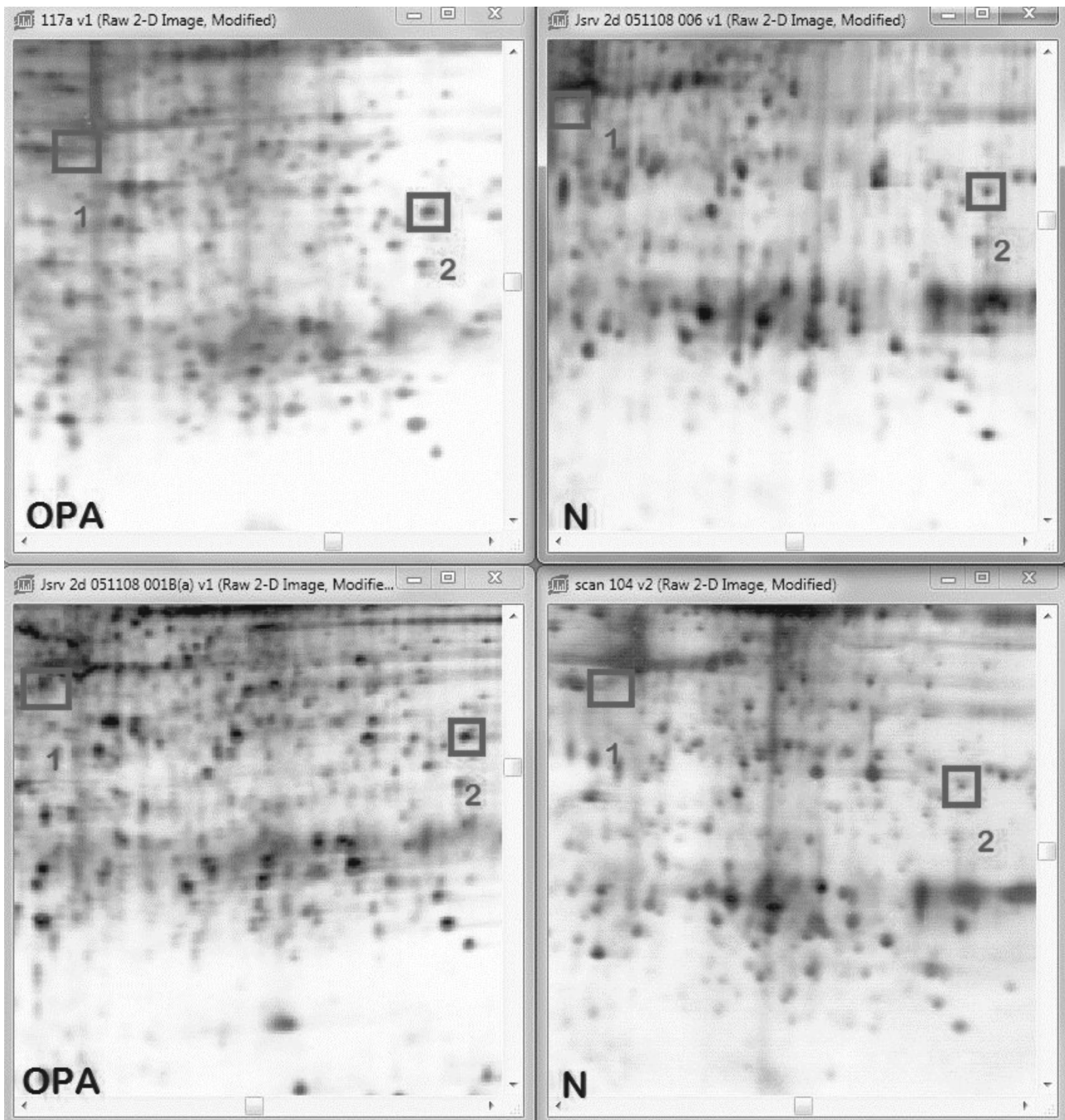


Fig. 1. Set of images of silver-stained gels obtained after two-dimensional electrophoresis of proteins isolated from two samples of ovine pulmonary adenocarcinoma and two non-neoplastic tissues. Locations of spots containing cytokeratine 19 (CK19) and aldolase A are labeled with red boxes. (OPA) – ovine pulmonary adenocarcinoma. (N) – non-neoplastic tissue. (1) – Location of CK19 spot. (2) – Location of aldolase A spot.

tissue was in the size and intensity of several spots, correlating with the amount of protein (Fig. 1).

There were 14 spots presenting at least 2-fold higher expression in each 2DE gel of neoplastic tissue as compared to non-neoplastic ones. The mass spectrometry analysis of the spots revealed that in 11 out of 14 spots, there was more than one polypeptide

present. In 3 spots single proteins were identified including: cytokeratin 19, aldolase A and mangan superoxide dismutase. For immunohistochemical study we used cytokeratin 19 and aldolase A as these proteins were identified in spots which were characterised by distinctive, over 3-fold overexpression in all neoplastic samples (Table 1).

Table 1. Proteins identified with mass spectrometry in selected spots. PDQuest Index – value of average spot expression increase in OPA vs. non- neoplastic tissue, generated in PDQuest. Theoretical mass and pI (isoelectric point) value were obtained using Mascot mass spectrometry software.

Spot Nr	Name of identified protein	*Index PDQuest	Theoretical mass / Calculated pI value	Protein access nr NCBI Database
1	Cytokeratin 19	3.3	43858 / 4.92	NP_001015600
2	Aldolase A	3.9	39925 / 8.45	NP_001095385

The results of the subsequent immunohistochemical study revealed that the normal, ciliated epithelium of bronchioles, as well as individual epithelial cells (type II pneumocytes) showed strong and diffuse expression of cytokeratin 19 and aldolase A in all specimens (Figs. 2, 4). Immunohistochemical analysis of CK19 and aldolase A expression in ovine lung adenocarcinoma sections showed positive cytoplasmic reaction in all tumour cells (Figs. 3, 5).

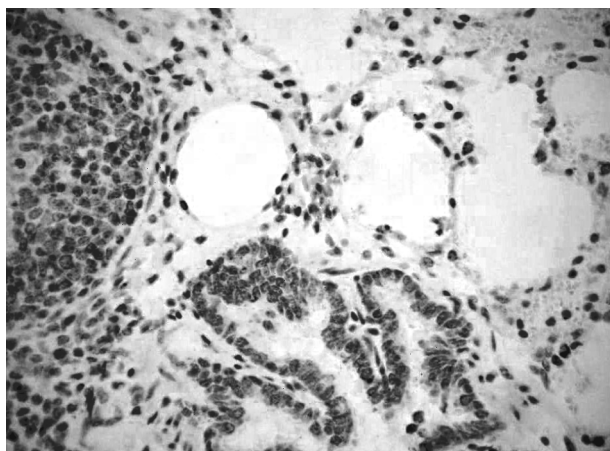


Fig. 2. Non-neoplastic lung tissue of sheep. Positive immunostaining for cytokeratin 19 visible in cytoplasm of epithelial cells of bronchioles and type II pneumocytes. 200x.

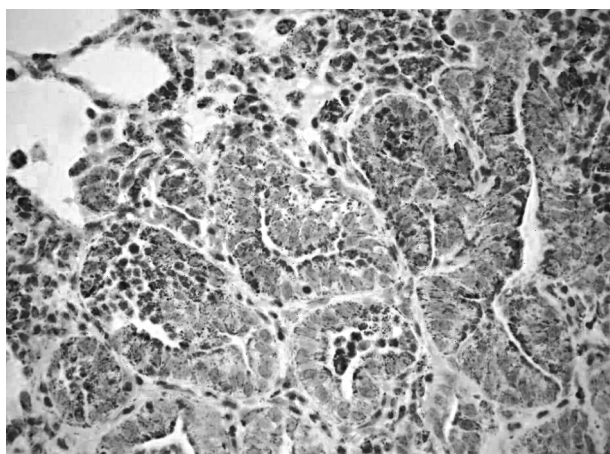


Fig. 3. Ovine pulmonary adenocarcinoma. Positive immunostaining for cytokeratin 19 visible in cytoplasm of epithelial cells of bronchioles and type II pneumocytes, as well as in neoplastic cells. 200x.

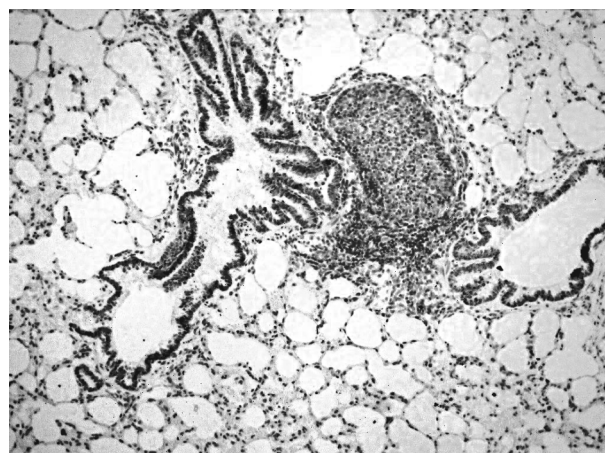


Fig. 4. Non-neoplastic lung tissue of sheep. Positive immunostaining for aldolase A visible in cytoplasm of epithelial cells of bronchioles and type II pneumocytes. 100x.

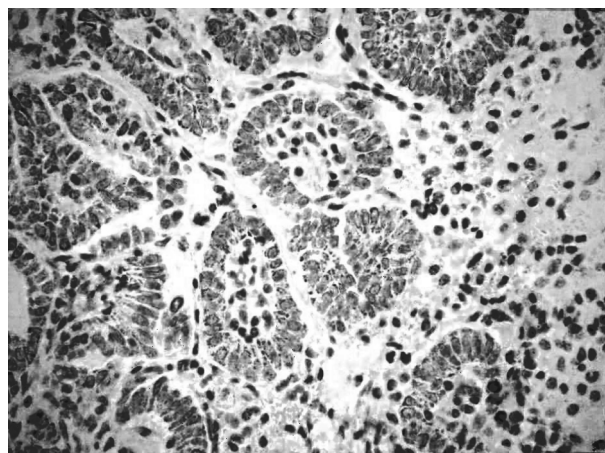


Fig. 5. Ovine pulmonary adenocarcinoma. Positive immunostaining for aldolase A visible in cytoplasm of epithelial cells of bronchioles and type II pneumocytes, as well as in neoplastic cells. 200x.

Discussion

In our study, we presented the utility of 2DE and mass spectrometry for revealing proteins differentially expressed in OPA tissues. Proteomic methods combined with immunohistochemistry allowed us to identify the proteins overexpressed in lung tissues of sheep affected with OPA.

In the majority of spots upregulated in OPA 2DE gels, multiple polypeptides were identified, which indicated overlapping of polypeptides in the gels. However, there were two protein spots showing over 3-fold upregulation in which single proteins were identified: cytokeratin 19 and aldolase A, and the expression of these two proteins was further verified with immunohistochemistry. IHC analysis not only confirmed CK19 and aldolase A expression in OPA, but also revealed which components of the tissue are responsible for higher expression of the two proteins in lung tissues of OPA affected sheep. Both CK19 and aldolase A were present in normal epithelial cells of bronchioles, as well as in neoplastic cells of OPA, indicating that upregulation of protein spots reflected the abundance of neoplastic cells in OPA samples.

The present work is, to our knowledge, the first report of analysis of CK19 and aldolase A expression in ovine pulmonary carcinoma. Both proteins were previously studied in humans, and there are several reports of their differential expression in human neoplastic diseases (Moll et al. 1982). Cytokeratin 19, a type I cytokeratin, belongs to intermediate filament proteins forming the cytoskeleton. CK 19 is the smallest known acidic cytokeratin and is not paired with a basic cytokeratin, unlike the other proteins of this group. According to Moll et al. (1982), CK19 together with cytokeratins 8, 9 and 18 is expressed in cells of simple, columnar epithelia such as the respiratory epithelium of the bronchial tree, which is consistent with the results of our study. It was found to be expressed specifically in periderm (Bártek et al. 1986). In vitro studies of rat lung alveolar epithelial cells have shown high expression of cytokeratin 19 in intensively proliferating type II pneumocytes (Paine et al. 1995). Increased expression of this protein was found using immunohistochemical methods in lung cancer in humans, and a particularly strong overexpression was observed in cases of squamous cell carcinoma and adenocarcinoma (Chyczewski et al. 1997, Kosacka and Jankowska 2007, Naseem et al. 2010). Cytokeratin 19 was also found to be expressed in other human epithelial malignancies including neoplasms of the liver (van Sprundel et al. 2010), colon, stomach, pancreas (Ohshio et al. 1997), biliary tract (Lódi et al. 2006), and breast (Alix-Panabières et al. 2009).

Gharib et al. (2002), in their study on the expression of cytokeratin in human adenocarcinoma of the lung, using two dimensional electrophoresis, demonstrated overexpression of CK 19 in neoplastic samples, compared with non-neoplastic tissue, which is consistent with our findings in OPA samples. The same authors, using Western blot analysis, detected

three isoforms of CK19 in neoplastic 2DE gels and observed a positive correlation between poor prognosis for patients affected with lung adenocarcinoma and high expression of CK19 protein isoforms of the lowest pI values (Gharib et al. 2002).

The soluble fragments of cytokeratin 19, known as CYFRA 21-1, were described by several authors to be present in human serum, with their level being increased in cases of non-small cell lung cancer (Weiskopf et al. 1995, Bates et al. 1997, Pujol et al. 2004) and squamous cell carcinoma of the head and neck (Bongers et al. 1995). CYFRA 21-1 was therefore considered by the authors to be one of the tumour markers, in particular, markers of epithelial lineage differentiation (Pujol et al. 2004).

Aldolase A (fructose-1,6-(bis)phosphate aldolase), which was identified in our study in the second analysed spot, is an enzyme belonging to the class of lyases and is involved in glycolysis and gluconeogenesis. In the cell it was found in the nucleus and cytoplasm, and was described to be involved in the organization of actin filaments and cytoskeleton formation (Kusakabe et al. 1997). High expression of this protein was observed in the lamellipodia of migrating keratinocytes occurring in healing wounds (Tochio et al. 2010). Aldolase A was also found to be produced in large quantities in the muscles and red blood cells. High expression of aldolase A was detected in the fetal liver in rats, and it was much lower in adults (Schapira et al. 1971, Hatzfeld et al. 1978, Gefflaut et al. 1995). Mutation in aldolase A was indicated by Kreuder et al. (1996) to be associated with myopathy and hemolytic anaemia. Aldolase A expression was found to be increased in various neoplasms in humans, such as lung, liver, gastric or colorectal cancer (Asaka et al. 1994, Tomonaga et al. 2004). There are also reports indicating that aldolase A level becomes elevated in serum of patients with malignant tumours, such as lung cancer and renal cancer (Takashi et al. 1992, Asaka et al. 1994, Güre et al. 1998). The high level of aldolase A is considered to be associated with anaerobic glycolysis, which is generally enhanced in neoplastic tissues (Ojika et al. 1991, Asaka et al. 1994).

In our study, we successfully applied two dimensional electrophoresis for proteomic analysis of OPA. Immunohistochemical examination permitted estimation of CK 19 and aldolase A as proteins expressed specifically in cubic respiratory epithelial cells and neoplastic cells indicating the origin of the tumour. Although these are preliminary studies on protein profile of OPA, we expect that detailed analysis, for example using narrow pH gradients in 2DE, may allow more potential protein markers to be revealed. The proteomic methods, by finding simi-

larities between OPA and human lung neoplasms on the protein level, proved to be useful for better understanding of the biology of cancer cells, as well as revealing possible markers of the disease.

Acknowledgments

This work was supported by Project No.: N N308 256335 funded by the Ministry of Science and Higher Education of Poland.

References

- Alix-Panabieres C, Vendrell JP, Slijper M, Pelle O, Barbotte E, Mercier G, Jacot W, Fabbro M, Pantel K (2009) Full-length cytokeratin-19 is released by human tumor cells: apotential role in metastatic progression of breast cancer. *Breast Cancer Res* 11: R39.
- Asaka M, Kimura T, Meguro T, Kalo M, Kudo M, Miyazaki T, Alpert E (1994) Alteration of aldolase isozymes in serum and tissues of patients with cancer and other diseases. *J Clin Lab Anal* 8: 144-148.
- Bártek J, Bártková J, Taylor-Papadimitriou J, Rejthar A, Kovařík J, Lukáš Z, Vojtěšek B (1986) Differential expression of keratin 19 in normal human epithelial tissues revealed by monospecific monoclonal antibodies. *Histochem J* 18: 565-575.
- Bates J, Rutherford R, Divilly M, Finn J, Grimes H, O'Muircheartaigh I, Gilmartin JJ (1997) Clinical value of CYFRA 21.1, carcinoembryonic antigen, neurone-specific enolase, tissue polypeptide specific antigen and tissue polypeptide antigen in the diagnosis of lung cancer. *Eur Respir J* 10: 2535-2538.
- Bongers V, Braakhuis BJ, Snow GB (1995) Circulating fragments of cytokeratin 19 in patients with head and neck squamous cell carcinoma. *Clin Otolaryngol Allied Sci* 20: 479-482.
- Chyczewski L, Nikliński J, Chyczewska E, Laudański J, Furman M (1997) Immunohistochemical analysis of tissue localization of cytokeratin 19 in lung cancer. *Rocz Akad Med Białymst* 42: 162-172.
- De las Heras M, Gonzalez L, Sharp JM (2003) Pathology of ovine pulmonary adenocarcinoma. *Curr Top Microbiol Immunol* 275: 25-54.
- De las Heras M, Ortin A, Salvatori D, Perez de Villareal M, Cousens C, Ferrer LM, Cebrian LM, Garcia de Jalon JA, Gonzalez L, Sharp JM (2005) A PCR technique for the detection of Jaagsiekte sheep retrovirus in the blood suitable for the screening of ovine pulmonary adenocarcinoma in field conditions. *Res Vet Sci* 79: 259-264.
- DeMartini JC, Carlson JO, Leroux C, Spencer T, Palmarini M (2003) Endogenous retroviruses related to jaagsiekte sheep retrovirus. *Curr Top Microbiol Immunol* 275: 117-137.
- Gefflaut T, Blonski C, Perie J, Willson M (1995) Class I aldolases: substrate specificity, mechanism, inhibitors and structural aspects. *Prog Biophys Mol Biol* 63: 301-340.
- Gharib TG, Chen G, Wang H, Huang CC, Prescott MS, Shedden K, Misek DE, Thomas DG, Giordano TJ, Taylor JM, Kardia S, Yee J, Orringer MB, Hanash S, Beer DG (2002) Proteomic analysis of cytokeratin isoforms uncovers association with survival in lung adenocarcinoma. *Neoplasia* 4: 440-448.
- Granville CA, Dennis PA (2005) An overview of lung cancer genomics and proteomics. *Am J Respir Cell Mol Biol* 32: 169-176.
- Gure AO, Altorki NK, Stockert E, Scanlan MJ, Old LJ, Chen YT (1998) Human lung cancer antigens recognized by autologous antibodies: definition of a novel cDNA derived from the tumor suppressor gene locus on chromosome 3p21.3. *Cancer Res* 58: 1034-1041.
- Hatzfeld A, Feldmann G, Guesnon J, Frayssinet C, Schapira F, Szajnert MF, Maurice M, Wolfelsperger M (1978) Location of adult and fetal aldolases A, B, and C by immunoperoxidase technique in LF fast-growing rat hepatomas. *Cancer Res* 38: 16-22.
- Kosacka M, Jankowska R (2007). The prognostic value of cytokeratin 19 expression in non-small cell lung cancer. *Pneumonol Alergol Pol* 75: 317-323.
- Kreuder J, Borkhardt A, Repp R, Pekrun A, Götttsche B, Gottschalk U, Reichmann H, Schachenmayr W, Schlegel K, Lampert F (1996) Brief report: inherited metabolic myopathy and hemolysis due to a mutation in aldolase A. *New Engl J Med* 334: 1100-1104.
- Kusakabe T, Motoki K, Hori K (1997) Mode of interactions of human aldolase isozymes with cytoskeletons. *Arch Biochem Biophys* 344: 184-193.
- Kycko A, Reichert M (2008) Two-dimensional electrophoretic analysis of polypeptides expressed by normal and ovine pulmonary adenocarcinoma affected lung tissues. *Bull Vet Inst Pulawy* 52: 3-7.
- Kycko A, Reichert M (2010) PCR-based methods for detection of JSRV in experimentally and naturally infected sheep. *Bull Vet Inst Pulawy* 54: 445-450.
- Lódi C, Szabó E, Holczbauer A, Batmunkh E, Sziójártó A, Kupcsulik P, Kovalszky I, Paku S, Illyés G, Kiss A, Schaff Z (2006) Claudin-4 differentiates biliary tract cancers from hepatocellular carcinomas. *Mod Pathol* 19: 460-469.
- Moll R, Franke WW, Schiller DL, Geiger B, Krepler R (1982) The catalog of human cytokeratins: Patterns of expression in normal epithelia, tumors and cultured cells. *Cell* 31: 11-24.
- Mornex JF, Thivolet F, De las Heras M, Leroux C (2003) Pathology of human bronchioloalveolar carcinoma and its relationship to the ovine disease. *Curr Top Microbiol Immunol* 275: 225-248.
- Naseem N, Reyaz N, Nagi AH, Ashraf M, Sami W (2010) Immunohistochemical expression of cytokeratin-19 in non small cell lung carcinomas – an experience from a tertiary care hospital in Lahore. *Int J Pathol* 8: 54-59.
- Ohshio G, Imamura T, Okada N, Yamaki K, Suwa H, Imamura M, Sakahara H (1997) Cytokeratin 19 fragment in serum and tissues of patients with pancreatic diseases. *Int J Pancreatol* 21: 235-241.
- Ojika T, Imaizumi M, Abe T, Kato K (1991) Immunohistochemical and immunohistochemical studies on three aldolase isozymes in human lung cancer. *Cancer* 67: 2153-2158.
- Paine R, Gaposchkin D, Kelly C, Wilcoxon SE (1995) Regulation of cytokeratin expression in rat lung alveolar epithelial cells in vitro. *Am J Physiol* 269: L536-L544.
- Palmarini M, Fan H (2001) Retrovirus-induced ovine pulmonary adenocarcinoma, an animal model for lung cancer. *J Natl Cancer Inst* 93: 1603-1614.

- Platt JA, Kraipowich N, Villafane F, DeMartini JC (2002) Alveolar type II cells expressing jaagsiekte sheep retrovirus capsid protein and surfactant proteins are the predominant neoplastic cell type in ovine pulmonary adenocarcinoma. *Vet Pathol* 39: 341-352.
- Pujol JL, Molinier O, Ebert W, Daurés JP, Barlesi F, Bucheri G, Paesmans M, Quoix E, Moro-Sibilot D, Szturmowicz M, Brechot JM, Muley T, Grenier J (2004) CYFRA 21-1 is a prognostic determinant in non-small-cell lung cancer: results of a meta-analysis in 2063 patients. *Br J Cancer* 90: 2097-2105.
- Rosadio RH, Sharp JM, Lairmore MD, Dahlberg JE, De Martini JC (1988) Lesions and retroviruses associated with naturally occurring ovine pulmonary carcinoma (sheep pulmonary adenomatosis). *Vet Pathol* 25: 58-66.
- Schapira F, Hatzfeld A, Reuber MD (1971) Fetal pattern of aldolase transplantable hepatomas. *Cancer Res* 31: 1224-1230.
- Sharp JM, DeMartini JC (2003) Natural history of JSRV in sheep. *Curr Top Microbiol Immunol* 275: 55-79.
- Srinivas PR, Verma M, Zhao Y, Srivastava S (2002) Proteomics for cancer biomarker discovery. *Clin Chem* 48: 1160-1169.
- Takashi M, Zhu Y, Nakano Y, Miyake K, Kato K (1992) Elevated levels of serum aldolase A in patients with renal cell carcinoma. *Urol Res* 20: 307-311.
- Tochio T, Tanaka H, Nakata S, Hosoya H (2010) Fructose-1,6-bisphosphate aldolase A is involved in HaCaT cell migration by inducing lamellipodia formation. *J Dermatol Sci* 58: 123-129.
- Tomonaga T, Matsushita K, Yamaguchi S, Oh-Ishi M, Kodera Y, Maeda T, Shimada H, Ochiai T, Nomura F (2004) Identification of altered protein expression and post-translational modifications in primary colorectal cancer by using agarose two-dimensional gel electrophoresis. *Clin Cancer Res* 10: 2007-2014.
- van Sprundel RG, van den Ingh TS, Desmet VJ, Katoonizadeh A, Penning LC, Rothuizen J, Roskams T, Spee B (2010) Keratin 19 marks poor differentiation and a more aggressive behaviour in canine and human hepatocellular tumours. *Comp Hepatol* 9: 4.
- Wieskopf B, Demangeat C, Purohit A, Stenger R, Gries P, Kreisman H, Quoix E (1995) Cyfra 21-1 as a biologic marker of non-small cell lung cancer. Evaluation of sensitivity, specificity, and prognostic role. *Chest* 108: 163-169.
- York DF, Querat G (2003) A history of ovine pulmonary adenocarcinoma (jaagsiekte) and experiments leading to the deduction of the JSRV nucleotide sequence. *Curr Top Microbiol Immunol* 275: 1-23.