

DOI 10.2478/pjvs-2013-0063

Original article

Effects of two water disinfectants (chloramine T and peracetic acid) on the epidermis and gills of *Garra rufa* used in human ichthyotherapy

R. Sirri, A. Zaccaroni, A. Di Biase, O. Mordenti, L. Stancampiano,
G. Sarli, L. Mandrioli

Department of Veterinary Medical Sciences, University of Bologna,
Via Tolara di Sopra, 50, 40064, Ozzano Emilia, Bologna, Italy

Abstract

Doctor fish (*Garra rufa*) have recently been used for aesthetic purposes and as a medical treatment in patients with psoriasis (ichthyotherapy). For this particular kind of human therapy it is essential to guarantee adequate hygienic conditions for both people and fish. The aim of this study was to test two concentrations of water disinfectants, chloramine T and peracetic acid, on *Garra rufa* to ascertain possible exposure damage to the epidermis and gills. Fish were exposed to 2 mg/l and 10 mg/l of chloramine T and to 15 µl/l and 45 µl/l of peracetic acid in a 40-minute static bath up to six times a day for one week. The epidermis and gills were checked for histological changes and the number of epidermal mucous cells, club cells and taste buds were quantified; mucous cells were also characterized histochemically to detect alterations in mucin production. No mortality or severe histological changes were found in treated or control fish. Cell count showed a significant increase ($p < 0.05$) in mucous cells (mean 49.1 ± 6.7 vs 37.0 ± 13.1 of controls) in animals treated with peracetic acid independently of the dose. Club cell number showed a significant ($p < 0.05$) decrease in fish treated with 2 mg/l of chloramine T (mean 74.3 ± 15.6) and with 45 µl/l of peracetic acid (mean 78.17 ± 10.5) compared to controls (mean 107.0 ± 19.2). Histochemical evaluation of mucous cells did not reveal changes in mucin type in fish exposed to the two disinfectants. The results suggest a good tolerability of *Garra rufa* to the two disinfectants at the concentrations tested.

Key words: Doctor fish, cyprinid, human ichthyotherapy, chloramine T, peracetic acid, histology, histochemistry

Introduction

The use of the so-called doctor fish (*Garra rufa*) has recently been established both for aesthetic purposes in “health and wellness” centres and as a medical treatment in patients with psoriasis (ich-

thyotherapy) (Ozcelik et al. 2000, Grassberger and Hoch 2006). The basis of the therapy is that people are exposed to fish which feed on skin tissues. In this context it is essential to guarantee adequate hygienic conditions for humans and at the same time preserve

fish health. To date, no scientific studies have addressed the positive effects of ichthyotherapy.

The aim of this study was 1) to test two concentrations of two different disinfectants commonly used for water treatment (chloramine T and peracetic acid) on *Garra rufa* tissues to assess possible tissue damage to the integument and gills; 2) to characterize any disinfectant-induced histochemical changes in the composition of mucins.

Materials and Methods

Experimental protocol

The experiment was approved by the ethical scientific committee for animal experimentation of the University of Bologna, in accordance with the European Community Council directive (86/609/ECC) and carried out at the facility in Cesenatico (Bologna University, Italy). Fish were previously obtained by natural reproduction in controlled conditions. Five 60 liter aquaria (one control group and four treatments) were set up with a recirculating system to contain 20 fish each. The environmental conditions were monitored daily to maintain standard parameters of temperature (28-29°C) and oxygen (5-6 mg/l) and to check for ammonia, nitrites and nitrates. Water pH and hardness (CaCO₃ equivalents) were 7.4 and 29° F respectively (1° F=10 mg/L CaCO₃ equivalents). Fish (a total of 100 animals) were acclimatized for two weeks before the experiment.

The disinfectant concentrations were chosen according to the literature (Powell et al. 1995, Sanchez et al. 1998, King and Farrell 2002) and following the guidelines for water treatment given by the manufacturer (Oxygen, WWW.ORPC.IT, Milan, Italy) as 2 mg/l (low dose) and 10 mg/l (high dose) for chloramine T and 15 µl/l (low dose) and 45 µl/l (high dose) for peracetic acid.

Fish were moved each time from the aquaria to a ten liter tank for a 40-minute static bath with the disinfectant. At the end of the treatment the fish were returned to their aquaria. This was done to reproduce the hypothetical practical conditions of repeated ichthyotherapeutic sessions. The trial protocol consisted of five days of treatment for each dose/disinfectant with increasing disinfections/day (from two disinfections on the first day to six disinfections on the fifth day). The bath was renewed each time.

Fish were fed a commercial cyprinid food twice a day, morning and evening, to verify appetite. Data on mortality were recorded.

On the fifth day, after the last treatment, a total of 29 fish (5 controls and 6 animals from each dose/disin-

fectant treatment – 3 immediately after the last treatment and 3 after 12 hours in clean water) were euthanized with a lethal dose of anesthetic (tricaine methanesulfonate MS-222, 100 mg/l).

Macroscopic findings and histology

At necropsy, any changes were recorded and documented. Gills, mouth/barbs and integument of the ventral area were sampled and immediately fixed in 4% buffered formalin. After paraffin embedding histological sections were then cut at change in 3 µm, hematoxylin and eosin stained and evaluated under a light microscope. Epidermal mucous cells, keratinocytes, club cells, taste buds and gill mucous cells, epithelial cells and capillary axis were checked for hypertrophy, hyperplasia, cellular degeneration, necrosis, inflammatory changes and circulatory disturbances.

Three micrometer-thick H&E stained sections of integument of the ventral area were assessed under a light microscope. A manual count was performed to quantify the number of mucous cells (MC), taste buds (TB) and club cells (CC). Images of three fields per fish (area per field 34477 µm²) were taken at 40x lens using a Nikon Eclipse 80i optical microscope and a Nikon Digital Sight SD-MS camera (Nikon Corporation, Japan).

Statistical analysis of data was performed using SPSS 12.0. Significance was set at p<0.05. Preliminary non-parametric analysis was used to test for Normal distribution (one sample Kolmogorov-Smirnov test) of the three variables – total number of MC, TB and CC counted for each fish. To evaluate the influence of both disinfectants and dose on cell numbers, parametric (Analysis of Variance – ANOVA) and non-parametric (Kruskal-Wallis test) analyses were used for Normal distributed and non-Normal distributed data, respectively.

Histochemistry on the mouth epidermis and gills

Different histochemical stains were used to characterize the chemical composition of mucins of epidermal and gill mucous cells and disclose any qualitative changes in mucin type related to disinfectants. Alcian blue at pH 2.5 and pH 1 combined with PAS staining (Harris et al. 1973) were used to reveal neutral and acidic mucins on sections from two animals per treatment (including control). Selected cases were also pretreated with diastase to exclude glycogen in PAS positive staining or with sulfuric acid 0.1 N (Cull-

ing's method) to distinguish between sialylated or sulphate acid mucins according to McManus and Mowry (1960).

Results

Feeding behavior of fish treated with the minimum dose of both compounds was not affected: the animals showed appetite and voracity (typical "rooting" on the bottom) throughout the week, whereas animals treated with the highest dose of both compounds showed poor appetite, especially towards the last days of the week. No mortality was observed. At necropsy, macroscopic findings were absent. Hypertrophy, hyperplasia, cellular degeneration, necrosis, inflammatory changes and circulatory disturbances were not observed in the integument and gills, either in treated subjects or in controls.

No significant differences were found in cell numbers among controls, fish euthanized immediately at the end of the last treatment and fish euthanized 12 hours later. Due to the lack of significant differences related to euthanasia timing, the following analyses were performed using pooled data. For each group – one control group and the four treatments (peracetic acid high dose, peracetic acid low dose, chloramine T high dose, chloramine T low dose) – mean and 95% confidence intervals (CI) of the number of TB, MC and CC are reported in Figs. 1-3 respectively.

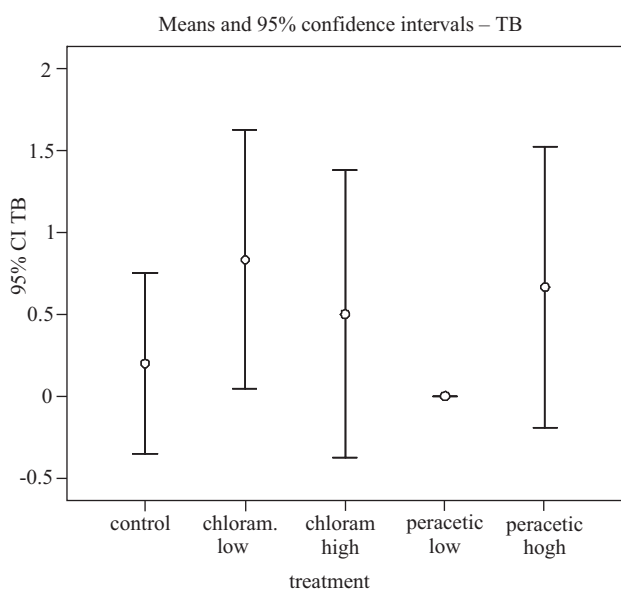


Fig. 1 – Mean number of TB and 95% confidence interval (CI) in each treatment group. Due to the low number of TB cells and because of the non Normal distribution of the data, CI for this type of cell are not reliable and are shown for informative purposes only.

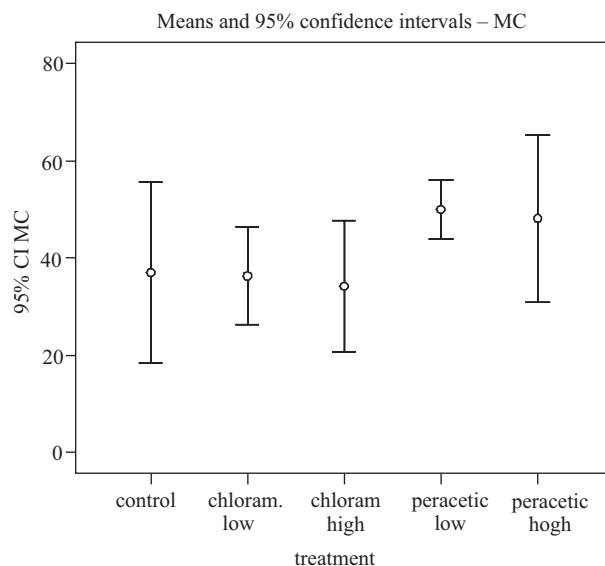


Fig. 2 – Mean number of MC and 95% confidence interval in each treatment group.

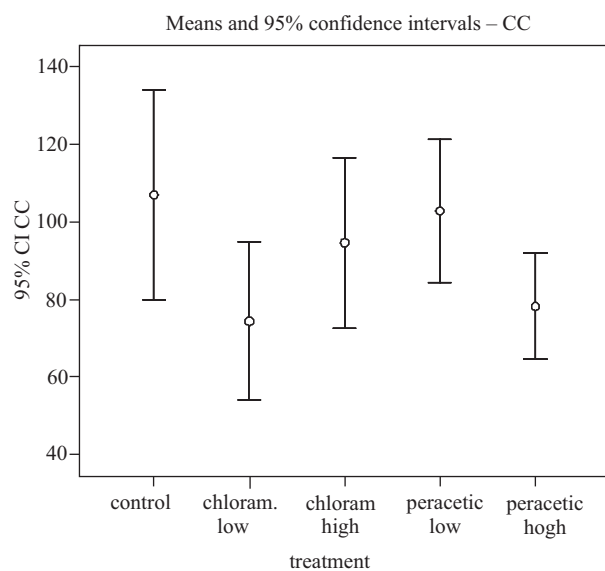


Fig. 3 – Mean number of CC and 95% confidence interval in each treatment group.

The total number of counted TB ranged from zero to two cells (mean 0.45; standard deviation 0.69). TB number was not normally distributed (Kolmogorov-Smirnow test, $p < 0.01$) so non-parametric statistical analysis was performed to compare TB number among the five groups corresponding to the one control group and the four treatment groups (peracetic acid high dose, peracetic acid low dose, chloramine T high dose, chloramine T low dose). No significant differences (Kruskal-Wallis test, $p > 0.05$) in TB numbers were found among the five groups (Fig. 1).

The total number of counted MC ranged from 16 to 74 (mean 41.28; standard deviation 13.34). MC

number was normally distributed (Kolmogorov-Smirnow test, $p > 0.05$) so data were analyzed using ANOVA. Independent variables were the type of disinfectant (peracetic acid or chloramine T) and the dose of disinfectant (high or low); the interaction between the two variables was also included in the statistical model to see if the effect of each variable was influenced by the level of the other one. ANOVA is a multivariate analysis and allowed the concurrent inclusion of both disinfectants, dose and interaction in the analysis: as a consequence, the effect of each independent variable is estimated by the model holding constant all other variables. A significant difference related to disinfectant type was found for MC (ANOVA, $p < 0.05$): independently of the dose, animals treated with peracetic acid showed more MC (mean $\pm 95\%$ CI: 49.1 ± 6.7) than controls (37.0 ± 13.1) and animals treated with chloramine T (35.3 ± 6.2) (Fig. 2). Neither disinfectant dose nor dose-type interaction significantly affected MC number (both $p > 0.05$). Marginal means predicted by the statistical model are shown in Fig. 4.

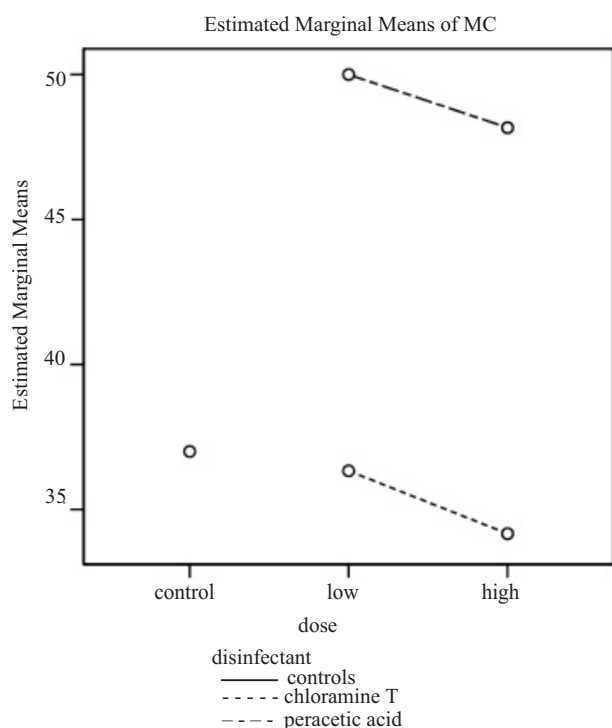


Fig. 4 – Marginal means of MC as predicted by the model. Means of MC are higher in peracetic acid-treated fish. No interaction between disinfectant and dose is appreciable.

CC number was normally distributed (Kolmogorov-Smirnow test, $p > 0.05$) so data were analyzed using ANOVA. As for MC, the type of disinfectant, disinfectant dose and the interaction between the two variables were concurrently included in the multivariate

statistical analysis. The total number of counted CC ranged from 56 to 140 cells (mean 90.86 ; standard deviation 21.78). Statistical analysis revealed a difference in CC number due to the interaction between disinfectant dose and type ($p < 0.01$): CC number was significantly lower in fish treated with low dose chloramine T (74.3 ± 15.6) and with high dose peracetic acid (78.17 ± 10.5) than that found in controls (mean $\pm 95\%$ CI: 107.0 ± 19.2) (Fig. 3). Marginal means predicted by the statistical model are shown in Fig. 5.

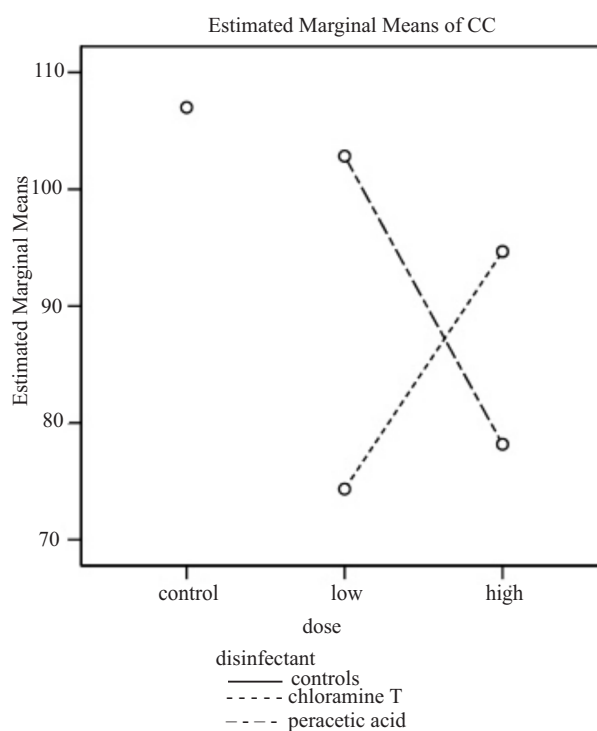


Fig. 5 – Marginal means of CC as predicted by the model. Means of CC are lower in fish treated with high dose chloramine T and with low dose peracetic acid. The interaction between disinfectant and dose is appreciable due to the intersection of the lines.

Histochemistry of the mouth epidermis with combined Alcian blue pH2.5/PAS staining displayed a mixed cell population: mucous cells with foamy cytoplasm light blue stained (faint Alcian blue stain) containing non sulphated acid mucins and cells with homogeneous dark blue cytoplasm (Alcian blue positive) which contained acid mucins, and mucous cells magenta stained (PAS positive) which contained neutral mucins (Fig. 6 A). On the other hand, with Alcian blue pH1/PAS staining all mucous cell were magenta (PAS positive) showing that the acid mucins had weak acid radicals (sulphate-free sialic acid or carboxylated acid mucins) (Fig. 6 B). After a pre-treatment with sulfuric acid these cells stained with Alcian blue con-

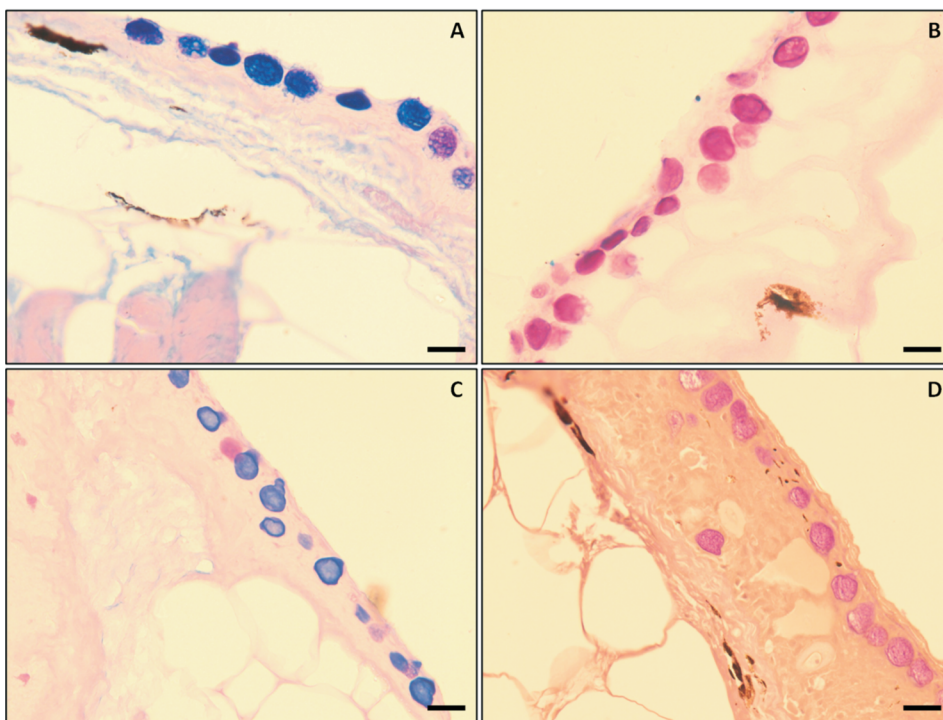


Fig. 6. Histochemistry of the mouth epidermis in control animals: (A) Alcian blue pH2.5/PAS staining displays a mixed cell population composed of light blue stained mucous cells (non sulphated acid mucins), mucous cells with a dark blue cytoplasm (acid mucins) and magenta stained mucous cells (neutral mucins); (B) Alcian blue pH1/PAS staining displays all magenta stained mucous cells (neutral and sulphate-free sialic acid or carboxylated acid mucins); (C) Sections pre-treated with sulfuric acid show the majority of mucous cells are Alcian blue stained (sulphate-free carboxylated acid mucins); (D) Sections pre-treated with diastase show all mucous cells magenta stained (absence of a glycogen content). Bar = 25 μ m.

firming a sulphate-free content (carboxylated acid mucins) (Fig. 6 C). Finally, with diastase digestion all mucous cells were magenta (PAS-positive) demonstrating the absence of glycogen (Fig. 6 D).

In gills, combined Alcian blue pH2.5/PAS staining showed a mixed cell population at the apex of primary lamellae, with most mucous cells containing neutral (PAS positive) mucins and some Alcian blue stained cells containing acid mucins (Fig. 7 A). At the base of primary lamellae all mucous cells stained magenta (only PAS positive) displaying a neutral content (Fig. 7 B). With Alcian blue pH1/PAS staining all mucous cells were only PAS positive (Fig. 7 C, D). The pre-treatment with sulfuric acid showed that mucous cells at the apex of primary lamellae, Alcian blue stained with Alcian blue pH2.5/PAS, remained Alcian positive confirming a sialic-free acid content, while the majority of cells were magenta stained (neutral mucin content) (Fig. 7 E) like the mucous cells at the base of primary lamellae (Fig. 7 F). Glycogen was not confirmed with diastase digestion (Fig. 7 G, H). Qualitative evaluation of mucin type in animals exposed to the two disinfectants and in the control did not show changes in mucous cell content at either concentration tested.

Discussion

This study protocol reproduced the hypothetical practical condition of “health and wellness” centres where fish can be employed for up to six customers a day in ichthyotherapy sessions lasting 30-40 minutes.

The two molecules tested were chosen among the common disinfectants used in Italy for waste-water treatment (peracetic acid) and for disinfection of sanitary tools and facilities (chloramine T) (Pergetti et al. 1999, VV AA 2011). Moreover the two compounds are used in Italy for tool/tank disinfection in aquaculture, and in other countries also for treatment of fish bacteria, fungi and parasites (Bullock et al. 1991, Harris et al. 2005, Sudová et al. 2010, Straus et al. 2012a). Chloramine-T is less affected by organic matter than other chloride compounds; it becomes more toxic in acidic and warm water and in soft water (Bills et al. 1988). Peracetic acid is a very powerful oxidant but information on repeated dose toxicity, composition, concentration and stability of this substance is scant and few toxicity tests have been done. However, the effects reported in the literature were generally a result of the irritant and corrosive properties of peracetic acid (MassDEP 2010).

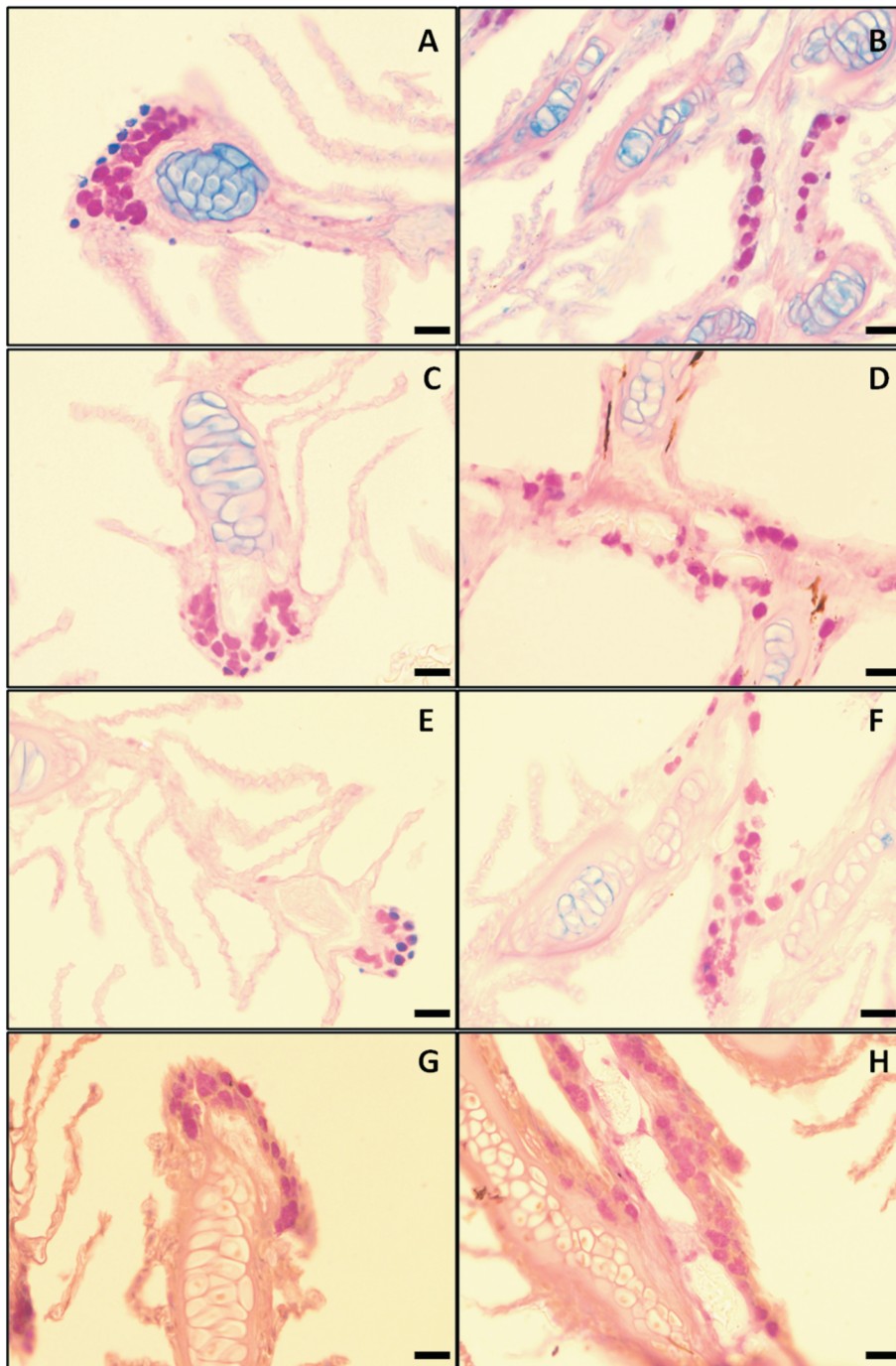


Fig. 7. Histochemistry of gills in control animals: (A,B) Alcian blue pH2.5/PAS staining displays a mixed cell population at the apex of primary lamellae (A) with a majority of mucous cells magenta stained (neutral mucins) and some Alcian blue stained mucous cells (acid mucins). At the base of primary lamellae (B) all mucous cells are magenta stained (neutral mucins). (C,D) Alcian blue pH1/PAS staining shows all mucous cells magenta stained both at the apex (C) (neutral and sulphate-free sialic acid or carboxylated acid mucins) and at the base (D) (neutral mucins) of primary lamellae. (E,F) Sections pre-treated with sulfuric acid show some mucous cells at the apex of Alcian blue stained primary lamellae (E) (sialic-free acid mucins), while the majority of mucous cells are magenta stained (neutral mucins) like the mucous cells at the base of primary lamellae (F). (G,H) Sections pre-treated with diastase show all mucous cells magenta stained (absence of a glycogen content) both at the apex (G) and at the base (H) of primary lamellae. Bar= 25 μ m.

The histomorphological features and inflammatory response of the integument and gills have been evaluated to assess the health of fish in contact with chemical agents as these organs are those primarily in direct contact with the aquatic environment (Sanchez et al. 1997, Sanchez et al. 1998).

In our study, neither chloramine T nor peracetic acid induced histological changes in the integument and gills. This is not fully consistent with some literature reports of histological changes for both disinfectants in different fish species. In juvenile rainbow trout (*Oncorhynchus mykiss*) a thinning of the epidermis was associated with a decrease in mucous cell volume after four weeks of treatment with 10 mg/l of chloramine T for 60 minutes once weekly (Sanchez et al. 1998) while minimal changes were found in gills treated twice weekly for an 11-week period with a one-hour bath of 10 mg/l chloramine T (Sanchez et al. 1997). Moreover, Powell et al. (1995) found a swelling of the gill epithelium associated with intercellular edema, loss of mucous cells and an increase in chloride cells in fingerling rainbow trout (*Oncorhynchus mykiss*) treated for one hour with 10 and 20 mg/l chloramine T twice weekly on two consecutive days for four weeks; in adult rainbow trout mucous cell hyperplasia was disclosed in a graded hypoxia experiment with repeated intermittent exposure to 9 mg/l chloramine T (Powell et al. 1998).

However, chloramine T has been used safely at concentrations higher than those used in our study in up to four 60-minute treatments in Atlantic salmon (*Salmo salar*), walleye (*Sander vitreum*) and channel catfish (*Ictalurus punctatus*); data on a safe treatment concentration are lacking for other species (Gaikowski et al. 2009).

The only study on peracetic acid reported histopathological changes in the gills of channel catfish fry (*Ictalurus punctatus*) treated with 2.2 mg/l (Straus et al. 2012b).

Our study evaluated the number of mucous cells, club cells and taste buds because of their actual or potential response to environmental changes. In particular, mucous cells are known to be responsive to general irritative insults through hyperplasia and mucous discharge as an adaptive and protective reaction (Ferguson 2006). Halbgehwachs et al. (2009) found that the number of club cells in fathead minnows (*Pimephales promelas*) decreased significantly after cortisol injection, suggesting their role in the immune response. Fish taste buds consist of several cellular components and enable the animal to identify food by detecting distinct chemical substances at a short distance (Kasumyan 1997). Any change in the number of taste buds induced by disinfectants could consequently induce a certain degree of appetite loss.

The significant increase in mucous cells in fish treated with a high peracetic acid concentration is probably a protective response to irritant acidic environmental conditions (Ledy et al. 2003). This response was not evident for chloramine T, in line with its chemical features.

The observed decrease in club cells at high peracetic acid concentration and at low concentration of chloramine T cannot be considered a direct consequence of the type and dosage of disinfectants. The adverse effect of chloramine T only when used at low dosage is biologically inconsistent. The differences among groups are probably a stress-dependent response to accidental events, such as handling of fish. We suggest caution in using these cells as indicators of adverse chemical effects because of their high susceptibility to various stressors.

The lack of significant differences in taste buds among the five groups is related to their low number in ventral areas (Cinar et al. 2008).

Histochemistry by combined Alcian blue/PAS staining at two pH values proved a useful tool to classify different mucous cell populations on the basis of the type of mucins produced, and disclose any changes due to the treatments. The present results suggest that the majority of mucous cells in the epidermis of *Garra rufa* have sulphate-free acid mucopolysaccharides (carboxylated), while only some mucous cells possess a neutral content. Most mucous cells in gills contained neutral mucopolysaccharides and only few cells at the apex of primary lamellae showed sulphate-free acid mucopolysaccharides (carboxylated). Yamada et al. (1975) reported a prevalence of mucous cells containing sialic acid glycoproteins in skin and gills of Japanese eel (*Anguilla japonica*). Saxena and Kulshrestha (1981) showed a mixed mucous cell population containing neutral mucopolysaccharides, glycogen, sulphated acid mucopolysaccharides and sialic acid glycoproteins in the skin of striped dwarf catfish (*Mystus vittatus*). Fletcher et al. (1976) showed a majority of sulphated acid mucopolysaccharides in the skin of plaice (*Pleuronectes platessa*), a mixed mucous cell population containing neutral mucins, glycogen, sulphated acid mucopolysaccharides and sialic acid glycoproteins in the skin of flounder (*Platichthys flesus*), and mucous cells containing sialic acid glycoproteins in the skin of rainbow trout (*Salmo gairdneri*). The mucous cell population was mixed in the gills of all three species, with cells producing each type of glycoprotein. Harris et al. (1973) found a prevalence of sialic acid glycoproteins in epidermal mucous cells in brown trout (*Salmo trutta*) and Hentschel and Muller (1979) displayed the same content in mucous cells of Prussian carp (*Carassius auratus gibelio*), European bullhead (*Cottus*

gobio) and bull rout (*Myoxocephalus scorpius*), especially in freshwater species with respect to saltwater fish. More recently, two studies on epidermal and gill mucous cells of a cyprinid fish, Indian major carp (*Labeo rohita* and *Cirrhinus mrigala*) showed the production of glycoproteins in gills with oxidizable vicinal diols and glycoproteins with sialic acid residues without O-acyl substitution, and the same glycoproteins also in the epidermis but at a low concentration. In addition, glycoproteins with O-sulphate esters are secreted by the mucous goblet cells both in gills and epidermis (Rai et al. 2012, Srivastava et al. 2012). Qualitative evaluation of mucous cell mucin types in the present study did not reveal changes among the five groups. The histochemical composition of mucins was not affected by the two disinfectant molecules tested.

In conclusion, although peracetic acid showed a moderate irritative effect at the higher concentration used, no severe histological damage was found suggesting the two disinfectant molecules are well-tolerated by *Garra rufa*.

Acknowledgments

This work was supported by SPINNER 2013 Program, European Social Fund (ESF), Emilia-Romagna Regional Department for Education, Professional Training, University and Research, and Work. The authors gratefully acknowledge the skilful technical assistance of Stefano Ghiotto in performing histology and histochemistry, and Anne Collins for English editing.

References

- Bills TD, Marking LL, Dawson VK, Rach JJ (1988) Effects of environmental factors on the toxicity of chloramine-T to fish. US Fish Wildl Serv Invest Fish Control 96: 1-6.
- Bullock GL, Herman RL, Waggy C (1991) Hatchery efficacy trials with chloramines-T for control of bacterial gill disease. J Aquat Anim Health 3: 48-50.
- Cinar K, Venol N, Kuru N (2008) The distribution of taste buds in *Garra rufa*. Anat Histol Embryol 37: 63-66.
- Ferguson HW (2006) Skin. In: Ferguson HW (ed) Systemic pathology of fish, 2nd ed., Scotian Press, London, pp 64-89.
- Fletcher TC, Jones R, Reid L (1976) Identification of glycoproteins in goblet cells of epidermis and gill of plaice (*Pleuronectes platessa* L.), flounder (*Platichthys flesus* (L.)) and rainbow trout (*Salmo gairdneri* Richardson). Histochem J 8: 597-608.
- Gaikowski MP, Densmore CL, Blazer VS (2009) Histopathology of repeated, intermittent exposure of chloramine-T to walleye (*Sander vitreum*) and (*Ictalurus punctatus*) channel catfish. Aquaculture 287: 28-34.
- Grassberger M, Hoch W (2006) Ichthyotherapy as alternative treatment for patients with psoriasis: a pilot study. Evid Based Complement Alternat Med 3: 483-488.
- Halbgewachs CF, Marchant TA, Kusch RC, Chivers DP (2009) Epidermal club cells and the innate immune system of minnows. Biol J Linn Soc 98: 891-897.
- Harris JE, Watson A, Hunt S (1973) Histochemical analysis of mucous cells in the epidermis of brown trout *Salmo trutta* L. J Fish Biol 5: 345-351.
- Harris JO, Powell MD, Attard MG, DeHayr L (2005) Clinical assessment of chloramine-T and freshwater as treatments for the control of gill amoebae in Atlantic salmon, *Salmo salar* L. Aquac Res 36: 776-784.
- Hentschel H, Muller M (1979) Sialic acids in epithelial tissues of *Carassius auratus gibelio* (bloch) (prussian carp), *Cottus gobio* L. (bullhead) and *Myoxocephalus scorpius* (L.) (bull rout). Comp Biochem Physiol A 64: 585-588.
- Kasumyan AO (1997) Gustatory reception and feeding behavior in fish. J Ichthyol 37: 72-86.
- King K, Farrell P (2002) Sensitivity of juvenile Atlantic sturgeon to three therapeutic chemicals used in aquaculture. North Am J Aquacult 64: 60-65.
- Ledy K, Giambérini L, Pihan JC (2003) Mucous cell responses in gill and skin of brown trout *Salmo trutta fario* in acidic, aluminium-containing stream water. Dis Aquat Organ 56: 235-240.
- MassDEP (2010) Hydrogen peroxide, peracetic acid and sodium percarbonate. Massachusetts Department of Environmental Protection, Massachusetts Department of Agricultural Resources – Massachusetts Executive Office of Energy and Environmental Affairs Boston, 17 pp <http://www.mass.gov/eea/docs/agr/pesticides/aquatic/sodium-carbonate-peroxyhydrate-and-hydrogen-peroxide.pdf>
- McManus JFA, Mowry RW (1960) Staining methods. Histological and histochemical, Paul B. Hoeber Inc. Medical Division of Harper & Brothers, New York.
- Ozçelik S, Polat HH, Akyol M, Yalçın AN, Ozçelik D, Marufihah M (2000) Kangal hot spring with fish and psoriasis treatment. J Dermatol 27: 386-390.
- Pergetti M, Davoli D, Gaccioli M, Sansebastiano G, Stecchi R (1999) Esperienza di disinfezione con acido peracetico di un effluente di un depuratore biologico. Biologia Ambientale 1: 19-28.
- Powell MD, Speare DJ, Wright GM (1995) Morphological changes in rainbow trout (*Oncorhynchus mykiss*) gill epithelia following repeated intermittent exposure to chloramine-T. Can J Zool 73: 154-165.
- Powell MD, Haman F, Wright GM, Perry SF (1998) Response of rainbow trout (*Oncorhynchus mykiss*) to a graded hypoxia following repeated intermittent exposure to chloramine-T. Aquaculture 165: 27-39.
- Rai AK, Srivastava N, Kumari U, Mittal S, Mittal AK (2012) Histochemical analysis of glycoproteins in the secretory cells in the epidermis of the head skin of Indian Major Carp, *Labeo rohita*. Tissue Cell 44: 409-417.
- Sanchez JG, Speare DJ, Johnson GJ (1997) Morphometric and histochemical assessment of the branchial tissue response of rainbow trout, *Oncorhynchus mykiss* (Walbaum), associated with chloramine-T treatment. J Fish Dis 20: 375-381.
- Sanchez JG, Speare DJ, Sims DE, Johnson JG (1998) Morphometric assessment of epidermal and mucous-biofilm changes caused by exposure of trout to chloramine-T or formalin treatment. J Comp Pathol 118: 81-87.

- Saxena M, Kulshrestha SK (1981) Histochemical studies of mucosubstances in the epidermis of a nonscaly teleost *Mystus (Mystus) vittatus* Bl. (Pisces-Bagridae). Histochemistry 72: 155-160.
- Srivastava N, Kumari U, Rai AK, Mittal S, Mittal AK (2012) Histochemical analysis of glycoproteins in the gill epithelium of an Indian major carp, *Cirrhinus mrigala*. Acta Histochem 114: 626-635.
- Straus DL, Meinelt T, Farmer BD, Mitchell AJ (2012a) Peracetic acid is effective for controlling fungus on channel catfish eggs. J Fish Dis 35: 505-511.
- Straus DL, Meinelt T, Farmer BD, Beck BH (2012b) Acute toxicity and histopathology of channel catfish fry exposed to peracetic acid. Aquaculture 342-343: 134-138.
- Sudová E, Straus DL, Wienke A, Meinelt T (2010) Evaluation of continuous 4-day exposure to peracetic acid as a treatment for *Ichthyophthirius multifiliis*. Parasitol Res 106: 539-542.
- VV AA (2011) Antisepti e disinfezione in ambito sanitario e socio-sanitario. Agenzia sanitaria e sociale regionale dell'Emilia-Romagna, Centro Stampa Regionale, Bologna, Italy. http://www.docvadis.it/assistentadomiciliare/document/assistentadomiciliare/line_guida_disinfezione/fr/metadata/files/0/file/kdisinfezione.pdf
- Yamada K (1975) Morphochemical analysis of mucosubstances in some epithelial tissues of the eel (*Anguilla japonica*). Histochemistry 43: 161-172.